



Review of the Literature on Pain in Horses During Colic: Understanding Visceral Abdominal Pain for the Right Therapeutic Choice

Sourokou Sabi S. ^{a*}, Kane Y. ^a, Kadja M. C. ^a, Chabchoub A. ^b,
Kabura E. ^a, Cisse S.A. ^a and Kaboret Y.Y. ^a

^a Inter-State School of Veterinary Science and Medicine (EISMV), Dakar, Senegal.

^b National School of Veterinary Medicine (ENMV), Sidi Thabet, Tunisia.

Authors' contributions

This work was carried out in collaboration among all authors. All authors read and approved the final manuscript.

Article Information

DOI: <https://doi.org/10.9734/ajob/2024/v20i6415>

Open Peer Review History:

This journal follows the Advanced Open Peer Review policy. Identity of the Reviewers, Editor(s) and additional Reviewers, peer review comments, different versions of the manuscript, comments of the editors, etc are available here: <https://www.sdiarticle5.com/review-history/116787>

Review Article

Received: 10/03/2024

Accepted: 14/05/2024

Published: 18/05/2024

ABSTRACT

Pain is one of the most dreaded signs of colic in horses. The aim of this work is to facilitate understanding of the pathophysiology of this pain in order to improve therapeutic choices in equine clinics. The knowledge of the anatomy, physiology and innervation of the digestive tract will enable you to deal more effectively with algology during colic: understanding the pathophysiology, management of visceral pain during equine colic and well-being of horses. In this way, the management of a horse suffering from colic will be easier and more appropriate, by anticipating the deterioration in the animal's general condition and avoiding the side effects of the molecules to be used.

Keywords: Understanding; horse; colic; pain; therapeutic choice.

*Corresponding author: E-mail: sourokou@yahoo.fr;

Cite as: Sourokou Sabi S., Kane Y., Kadja M. C., Chabchoub A., Kabura E., Cisse S.A., & Kaboret Y.Y. (2024). Review of the Literature on Pain in Horses During Colic: Understanding Visceral Abdominal Pain for the Right Therapeutic Choice. *Asian Journal of Biology*, 20(6), 60–66. <https://doi.org/10.9734/ajob/2024/v20i6415>

1. INTRODUCTION

In horses, colic is a painful attack of the abdomen, manifested by stereotyped symptoms also known as "acute abdominal pain" [1]. Acute abdominal pain covers a range of symptoms, but refers specifically to pain of abdominal origin, the causes of which are multiple and most frequently of digestive origin [2,3,4]. They are recognised as the leading cause of mortality in horses [5] and one of the most frequent reasons for consultation in equine clinics [6]

The harmful clinical consequences and the impact of pain on the well-being of a sick horse mean that appropriate and rapid treatment is required [7]. The aim of treatment in the field is to eliminate this pain, or at least to reduce it [8]. Nociceptive stimulation during colic and its consequences makes analgesia the key stage in the treatment of colicky horses, and requires an understanding of visceral motricity and pain in order to make the best therapeutic choices (Drendel, 2009).

2. ABDOMINAL VISCERAL PAIN: ORIGIN (ANATOMIC AND PHYSIOLOGY), CONSEQUENCE AND LEVELS

- **Anatomic: Visceral sensory innervation (BIELEFELDT and GEBHART, 2006)**

A particular feature of visceral pain is the dual innervation provided by the parasympathetic system (vagus nerve in particular, but also pelvic nerves for the lower part of the body) and by spinal afferent fibres which pass through the sympathetic system. The innervation of the transverse colon, for example, includes vagal afferent fibres (from a local ganglion to the nucleus of the solitary fasciculus) and splanchnic nerves (or viscerosensory axons) from the T5 to L2 medullary roots. These fibres are polymodal, meaning that they are chemo-, thermo- and mechano-sensitive. A sensitisation phenomenon may develop after an injury; in addition, some nociceptors are "silent", i.e. they are insensitive to stimuli in physiological situations. Nociceptive afferent fibres terminate in layers I, II, V and X of the medulla, with visceral afferents accounting for around 10% of all nerve fibres at this level (Fig. 1). The central ascending pathways are via the spinothalamic, spinohypothalamic, spinosolitary and spinoreticular bundles and, unlike the somatic pathway, via the posterior cords of the spinal cord. Pain receptors are unevenly distributed throughout the body. They

are numerous in areas exposed to tissue damage, such as the skin, muscles, tendons and joints. They are also abundant in the digestive tract. Substance P (an 11 amino acid protein) is the main neuromodulator involved in the transmission of the nociceptive stimulus. There are two classes of visceral nociceptors: those with a low activation threshold (70%) found in the stomach, colon and bladder, and those with a high activation threshold (30%) found in the ureter, kidneys, lungs and heart [9].

- **Physiology of abdominal visceral pain**

Abdominal pain is caused by the stimulation of intra-abdominal nociceptive receptors or nociceptors, which create a nociceptive message that travels up the pain pathway to the brain via the spinal cord. These receptors are found in the wall (lamina propria and muscularis) of hollow organs, in the serosa (peritoneum and capsule of parenchymal organs) and in the mesentery. They respond to a mechanical stimulus such as (i) significant gastrointestinal distension, (ii) contraction of the muscular portion of the intestinal wall (the pain will be even more intense if the muscles cannot shorten, as in the case of obstruction), (iii) traction or compression of the blood vessels and mesentery, (iv) torsion and stretching causing sudden anoxia of the visceral muscles (e.g. during volvulus), and (v) gastric, intestinal or peritoneal inflammation (Montréal, 2018). They are also stimulated by inflammatory substances such as bradykinins, substance P, serotonin, histamine and prostaglandins. The density of these receptors is much lower, for example, than in the skin. This explains why the response to localised stimuli, such as an incision, a pinch or a localised burn is weak, and why visceral pain is perceived as dull, diffuse and difficult to localise [10]. These particularities help to explain the severe pain caused by gaseous distension of the colon, for example, and the animals' tolerance to transrectal palpation or laparoscopic surgery on a standing horse.

- **Consequences of visceral pain in horses**

Although it has not been fully studied or demonstrated in horses, it is accepted that pain causes an organic stress reaction with neuroendocrine and immunological consequences that have a harmful impact on healing, the occurrence of complications, the duration of treatment and, particularly for the digestive tract, the resumption of transit [11,12]. Pain inhibits digestive transit by activating a spinal reflex which induces orthosympathetic

hyperactivity [13]. Furthermore, if visceral pain is treated inadequately, too late or for too short a period, it is feared that hypersensitivity of the pain pathways may develop, leading to a chronic hyperalgesic state, with potentially disastrous consequences for the animal's well-being and therefore its quality of life, temperament and performance [14].

The harmful clinical consequences of pain mean that it is considered to be a pathological process that warrants treatment. Nociceptive stimulation of the nervous portion of the hypothalamus leads to orthosympathetic stimulation and parasympathetic depression, resulting in reduced tissue perfusion, increased

afterload, reduced intestinal motricity and tachypnoea. If left unchecked, pain can lead to shock, which, when well established, often has a very poor prognosis. Analgesia is therefore the key stage in the treatment of colicky horses; it must always be adapted to the intensity of the animal's pain (Cirrier, 2004), [15, 16,6,17].

• **Classification of colic according to pain intensity**

The course of colic can take different forms, with different clinical signs depending on the type of condition involved (Table 1).

Table 1. Levels of pain according to the intensity of abdominal pain, symptoms and types of condition involved (modified from Gluntz, [18])

Levels	Symptoms of Colic	Type of Affection
Stade 1 No pain	-No	
Stade 2 Light pain	- Inappetence - Scrapes floor occasionally - Stares at side - Camps up as if to urinate - Lies down longer than normal - Leans against wall - Curls up upper lip - Plays with water without drinking	Ileus, ischaemia, poor tissue perfusion (dehydration), distension of muscle fibres (around an obstruction)
Stade 3 Moderate pain	- Restless, won't stay put - Gathers as if to lie down - Hits abdomen with hind leg - Lies flat on the ground - Rolls over - Adopts a "sitting dog" position - Growls	Inflammation, fluid retention with distension following occlusion, reperfusion following occlusion, poor tissue perfusion (in the event of obstruction), distension of muscle fibres
Stade 4 Severed pain	- Sweats - Rolls violently - Drops to the floor -Any other previously described symptom expressed violently	Inflammation, distension of the cecum, distension of the folded colon
Stade 5 Depression	- Depression state	

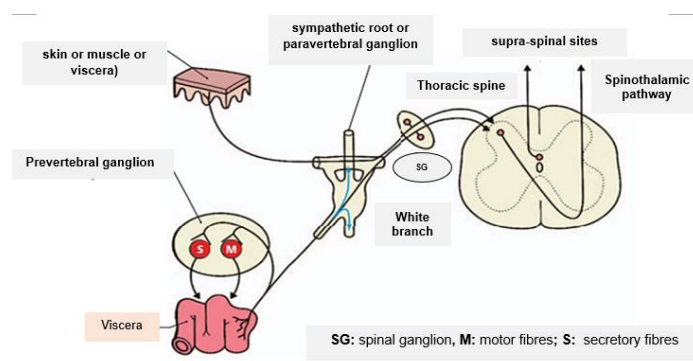


Fig. 1. Study area map

Table 2. Different histological layers of the digestive tract and associated plexi [22]

Layers of the digestive tract	Plexi
Mucosa	Submucosal plexus
Submucosa	
Circular muscularis	Myenteric plexus
Longitudinal muscularis	
Serosa or adventitia	

Table 3. Pathways linking the ENS to the CNS [22]

Central Nervous System (CNS)	Vagal pathway	Enteric Nervous System (ENS) or Intrinsic Innervation
	Sympathetic pathway	
	Pelvic or lumbosacral route	

3. PATHOPHYSIOLOGY OF VISCERAL ABDOMINAL PAIN

This is a pathophysiological description based on the enteric nervous system and extrinsic nerves, neuromodulators and certain abnormalities in visceral sensitivity.

- **Enteric nervous system and extrinsic nerves**

The brain-gut axis is organised into two peripheral levels: the enteric nervous system or myenteric plexus, also known as "intrinsic innervation", located in the digestive wall, and the "extrinsic nerves" which link the myenteric plexus to the spinal cord and the central nervous system (CNS). The ENS is connected to the CNS by the following pathways: sympathetic pathways, vagal pathways and lumbosacral (pelvic) pathways (Table 3).

In the wall of the digestive tract, the myenteric plexus is organised as a network that forms the "intestinal brain". It contains as many neurons as the spinal cord, most of which are afferent, i.e. sensory, neurons. In this network, interneurons establish connections between afferent and efferent neurons, as well as between neurons at different levels. The myenteric plexus is therefore the first level of integration of digestive sensations, recognising the size, speed and direction of movement of food particles [19]. The Enteric Nervous System (ENS) is an integrative nervous system located throughout the digestive tract, making it the second most neuron-rich organ after the brain. It is organised into distinct plexi formed by ganglionic structures connected to each other by inter-ganglionic fibres [20]. The main plexuses include the myenteric plexus (Table 2), located between the circular and longitudinal muscle layers, and the submucosal

plexus, located between the circular muscle layer and the mucosa [21]. Intrinsic innervation is linked to the CNS via three pathways (Table 3).

The enteric nervous system (ENS) is made up of neurons and enteric glial cells (Gulbransen and Sharkey, 2012). The ability of the ENS to generate reflexes, independently of any control by the CNS, is due to the presence of three functionally and neurochemically distinct types of intrinsic sensory neurons, interneurons and motor neurons [20]. Neurons regulating the motor functions of the digestive tract are located in the myenteric plexus, while those involved in the control of mucosal functions are located in the submucosal plexus [23]. The peristaltic activity of the digestive tract, triggered by chemical or mechanical stimuli, results from contraction upstream of the alimentary bolus and simultaneous relaxation downstream [25-28]. The coordinated repetition of this activity, over a segment, leads to the propagation of the alimentary bolus in an anterior-posterior direction (Huizinga and Lammers, 2009). One of the central and triggering elements of the peristaltic reflex is the enterochromaffin cell [20]. The brain-gut axis includes so-called descending antinociceptive nerve pathways which travel at the same time as the efferent pathways, from the hypothalamic nuclei [29,30]. They are distributed to the myenteric plexus and modulate the activity of afferent pathways, particularly the nociceptor neurons which are responsible for painful sensations. From a functional point of view, it is therefore logical to divide the complex nerve pathways linking the brain and the digestive tract into efferent pathways carrying information from the CNS to the periphery, and afferent pathways carrying information received at peripheral level to the higher integration centres [20].

• **Neurotransmitters**

Neuromodulators can be classified according to their biochemical structure into amines (acetylcholine and noradrenaline), serotonin, peptides (substance P, cholecystokinin, vasoactive intestinal peptide, enkephalins, etc.), purines (adenosine triphosphate, adenosine diphosphate, adenosine) and nitric oxide (NO). In response to chemical or mechanical stimuli, digestive epithelial cells release various neurotransmitters (serotonin, adenosine triphosphate or ATP) near the terminals of enteric sensory neurons. Serotonin activates intrinsic sensory neurons via 5HTP1p receptors. These neurons then lead, after activation of interneurons, to the activation of two phenotypically distinct categories of neurons that innervate the circular muscle. Thus, neurons whose axons project in the upward direction synthesise acetylcholine (Ach) and substance P (SP) and are excitatory motor

neurons. Neurons, whose axons project in the descending (anal) direction, synthesise nitric oxide (NO), vasoactive intestinal peptide (VIP), and Adenosine Triphosphate (ATP) and are inhibitory motor neurons that induce relaxation downstream of the stimulus [22]. Following activation of these neurons, there is a delayed activation of excitatory neurons, and a contraction allowing the restoration of basic muscle tone.

4. THERAPEUTIC CHOICE

Knowledge of the pathophysiology and consequences of pain allows a better understanding of the mechanisms by which it occurs and its classification according to severity. In this way, the management of a colicky horse will be easier and more appropriate by anticipating the deterioration in the animal's general condition and avoiding the side effects of the molecules to be used (Tables 4, 5 and 6).

Table 4. Main (undesirable) side effects of NSAIDs [7]

Systems	Adverse Effects	Comments
Digestive	Erosions and ulcerations of the gastric glandular mucosa and the mucosa of the large colon	Administer mucous membrane protectors to subjects at risk: foals, ponies or horses treated long-term.
Renal	Renal hypoperfusion leading to renal papillary necrosis	Low risk in animals with normal volemia. Increased risk in subjects in shock.
Cardiovascular	Thrombophlebitis and anticoagulant effect.	Long-lasting anticoagulant action of acetylsalicylic acid (11-14 days). Not recommended in cases of coagulation deficiency. Beneficial effect in preventing DIC (laminitis, endotoxemia, etc.).

Table 5. Main adverse effects of alpha-2 agonists [24]

Systems	ADVERSE Effects	Comments
Digestive	Significant reduction in motor function for at least 2 hours	Do not allow the horse to eat for 2 hours after sedation
Cardiovascular	Hypotension and bradycardia. Arrhythmic effect (blocks)	Reserve these molecules for horses with a suitable cardiovascular status.

Table 6. Criteria for the indicative choice of analgesic treatment for colic, depending on the treatment objective and the pain observed [15]

Treatment objective, probable type of pain and desired duration of action	Light pain	Moderate pain	Severe pain
-Mechanical origin, desired effect for 2 to 3 hours -Uncertain diagnosis, temporary relief or -Transport to a clinic, short journey	Dipyrone	Dipyrone + alpha-2 agonists (low dose)	Dipyrone + alpha-2 agonists (increase the dose)
-Main mechanical origin, desired effect for 6 to 8 hours -Diagnosis established, lasting relief -Transport to a clinic, long journey	Flunixin or Ketoprofen	Flunixin or Ketoprofen Butorphanol or low-dose morphine (re-administration probably necessary*)	

Treatment objective, probable type of pain and desired duration of action	Light pain	Moderate pain	Severe pain
Main inflammatory origin, desired effect for 8 to 12 hours	Meloxicam or Flunixin or Phenylbutazone	Meloxicam or Flunixin + Butorphanol	Meloxicam or Flunixin + morphine (increase dose) (re-administration 130 Low-dose morphine (re-administration imperative*) imperative*)

For example, the efficacy of non-steroidal anti-inflammatory drugs (NSAIDs) is limited to mild to moderate pain (Table 4). In the case of severe level III pain, the action of NSAIDs must be supplemented by another pharmacological class, such as alpha-2 agonists or morphine overexploit horses (Table 5). In addition, improving horse feed is a priority for all those involved in equine activities.

5. CONCLUSION

When it comes to abdominal pain in horses, it is important to have knowledge of the anatomy, physiology and innervation of the digestive tract, which will help you to manage algology during colic: understanding the pathophysiology and management of visceral pain during equine colic. Pain is the main factor underlying the symptoms observed during digestive colic in horses. The more intense the pain, the greater and more varied the clinical consequences. Consequently, early and appropriate management of a horse suffering from digestive colic is vital in order to avoid a crescendo of adverse consequences, including reduced performance, reduced well-being and, above all, the death of the horse affected. The management of digestive colic in horses depends on a number of factors, including the causes and severity of the consequences of the pain, and the therapeutic arsenal available.

COMPETING INTERESTS

Authors have declared that no competing interests exist.

REFERENCES

- Messaoudi EL, Landosli F, Chabchoub A. Coliques du cheval : Diagnostic et thérapeutique. El Baytary N°41 – 42 du Décembre 2006. Pathologie médicale Equidés et Carnivores. ENMV Sidi Thabet Tunisie 2020;2006.
- Cirier Pierre. Connaître les causes pour mieux les traiter; 2010. Available:https://www.doc-developpement durable.org/file/Elevages/cheval/maladies/coliquesDuCheval.pdf

- Cirier pierre. Les coliques digestives du cheval. Paris: Maloine. 2010;114. Available:https://www.amazon.fr/coliques-digestives-du-cheval/dp/2224028091
- Chabchoub A, Kane Y, Landolsi F, Ghorbel. A Ulcères de l'estomac chez le cheval. El Baytary 2007.n°45-46 Juillet 24-25; 2007.
- Julliard Véronique et GENAIN Jean-Luc.03/01/2011. Origines des coliques chez le cheval. Available:https://equipedia.ifce.fr/sante-et-bien-etre-animal/maladies/systeme-digestif-et-parasitisme/origines-des-coliques#auteurs
- Mair T, Divers T, Ducharme N. Manual of equine gastroenterology. Philadelphia: WB Saunders Co. 2002;540. Available:https://www.elsevier.com/books/manual-of-equine-gastroenterology/9780702024863
- Guezennec Aurelie Marie Catherine. Gestion pratique de la douleur chez le cheval; 2006. Available:https://oatao.univ-toulouse.fr/1649/1/GuezennecA.pdf
- White NA. The Equine acute abdomen (369-374). -Philadelphia: Lea and Febiger. 1990;434. Available:https://www.wiley.com/en-us/The+Equine+Acute+Abdomen,+3rd+Edition-p-9781119063216
- Bielefeldt K, Gebhart GF. Visceral pain: Basic mechanisms. Dans Textbook of Pain. Editors: McMahon SB, Koltzenburg M. Elsevier, 5e edition. 2006;721-736.
- Robertson ET Sanchez : Robertson, SA et Sanchez, LC. Traitement des douleurs viscérales chez les chevaux. Cliniques vétérinaires d'Amérique du Nord : Equine Practice. 2010;26(3):603–617.
- Andrews FM, Buchanan BR, Elliot SB, Clariday NA, ET Edwards LH. Gastric ulcers in horses. - J. Anim. Sci. 2005;83: 18-21.
- Arnauld Des Lions J, Battail GA, Gluntz X, Maurizi L, Et Fontaine G. L'accrochement néphrosplénique chez le cheval adulte: Revue bibliographique et actualités

- thérapeutiques. *Pratique Vétérinaire Equine*. 2002;34(134):11-18.
13. Sellon DC. Gestion du cheval en colique. *Prat. Vet. Equine*. 2007;158:25-33.
 14. Gwenola Touzot-Jourde. Gestion de la douleur viscérale d'origine abdominale chez le cheval La Semaine Vétérinaire n° 176 du 01/10/2012; 2012.
 15. Gluntz X, Et Gogny M. Les coliques du cheval. -Rueil-Malmaison : Les Editions du Point Vétérinaire. (Collection Atlas). 2007; 256.
 16. Battail GA. Premiers gestes au chevet du cheval en coliques (471-473). In : Journées nationales des GTV, Nantes, 25-26-27 Mai. 2005;562.
 17. White NA. Handbook of equine colic. - Oxford: Butterworth and Heinemann. 1999;146. Available:<https://lib.ugent.be/catalog/rug01:000659907>
 18. Gluntz X. Examen clinique du cheval en coliques. - *Pratique Vétérinaire Equine*. 2005;37(145):73.
 19. Delvaux Michel. Les douleurs abdominales en question : Rôle physiologique de la sensibilité viscérale. ISBN 2-287-21435-6. Springer-Verlag France; 2005.
 20. Neunlist M, Van Landeghem L, Mahe MM, Derkinderen P, Bruley Des Varannes SB, Rolli-Derkinderen M. The digestive neuronal-glia-epithelial unit: A new actor in gut health and disease. 2013 *Nature Reviews*. 2012;10(2):90–100.
 21. Wedel T, Roblick U, Gleiss J, Schiedeck T, Bruch HP, Kühnel W, Krammer HJ. Organization of the enteric nervous system in the human colon demonstrated by whole mount immunohistochemistry with special reference to the sub mucous plexus. *Ann Anat*. 1999;181(4):327–337
 22. Furness JB. The enteric nervous system and neuro-gastroenterology. *Nature Reviews*. 2012;9(5):286–29. Available:<https://pubmed.ncbi.nlm.nih.gov/22392290/>
 23. Grundy D, Al-Chaer ED, Aziz A, Collins SM, Ke M, Tache Y, Wood JD. Fundamentals of neuro-gastroenterology : Basic science. *Gastroenterology*. 2006;130(5):1391 -1411.
 24. Perrin R. La douleur en pathologie digestive. *Pratique vétérinaire équine*, 31 (numéro spécial coliques du cheval). 1999; 25-36.
 25. Gogny M. Anti-inflammatoires non stéroïdiens et douleur aiguë chez le cheval. *Bulletin des Groupements Techniques Vétérinaires (GTV)*. 2003;22: 275-280.
 26. Hillyer MH, Taylor FGR, Et French NP. A cross-sectional study of colic in horses on thoroughbred training premises in the British Isles in 1997. *Equine Veterinary Journal*. 2001;33(4):38-385. Available:<https://doi.org/10.2746/042516401776249499>
 27. Hillyer MH, Taylor FGR, Proudman CJ, DEWARDS GB, SMITH JE, ET French NP. Risk factors for simple colonic obstruction and distension colic in horses. In: *Proceedings of the 7th Equine Colic research Symposium*. *Equine Veterinary Journal*. 2002;34(5): 455-463.
 28. Serteyn D, Caudron I, Szoke M, Fontaine G, Stacquez S, Cheve D. Diagnostic et pronostic des pathologies intestinales aiguës chirurgicales du cheval. *Prat. Vet. Equine*. 1994;26:135-145.
 29. Thilo Wedel, Uwe Roblick, Joachim Gleiss, Thomas Schiedeck, Hans -Peter Bruch, Wolfgang Kühnel, Heinz-Jürgen Krammer. Organization of the enteric nervous system in the human colon demonstrated by whole mount immunohistochemistry with special reference to the sub mucous plexus. *Ann. Anat*. 1999;181(4):327 – 337. Available:[https://doi.org/10.1016/S0940-9602\(99\)80122-8](https://doi.org/10.1016/S0940-9602(99)80122-8)
 30. Université De Montreal. Département d'anesthésiologie et de médecine de la douleur; 2018 Available:<https://anesthesiologie.umontreal.ca/wp-content/uploads/sites/33/Chap-1-Les-Voies-de-la-Douleur.pdf>

© Copyright (2024): Author(s). The licensee is the journal publisher. This is an Open Access article distributed under the terms of the Creative Commons Attribution License (<http://creativecommons.org/licenses/by/4.0>), which permits unrestricted use, distribution, and reproduction in any medium, provided the original work is properly cited.

Peer-review history:

The peer review history for this paper can be accessed here:

<https://www.sdiarticle5.com/review-history/116787>