



## Outcomes of Diode Laser in Treatment of Common Anal Surgical Lesions (Haemorrhoids, Chronic Fissure and Fistula): A Prospective Study

Mohamed Talaat <sup>a\*</sup>, Ahmed Hazem <sup>a</sup>, Hamdy Abdel-Hady <sup>a</sup>  
and Mostafa M. Elsheikh <sup>a</sup>

<sup>a</sup> Department of General Surgery, Faculty of Medicine, Tanta University, Egypt.

### Authors' contributions

*This work was carried out in collaboration among all authors. All authors read and approved the final manuscript.*

### Article Information

#### Open Peer Review History:

This journal follows the Advanced Open Peer Review policy. Identity of the Reviewers, Editor(s) and additional Reviewers, peer review comments, different versions of the manuscript, comments of the editors, etc are available here: <https://www.sdiarticle5.com/review-history/92712>

Original Research Article

Received 05 August 2022

Accepted 11 October 2022

Published 12 October 2022

### ABSTRACT

**Introduction:** Management of anorectal disorders has been always a challenge for colorectal surgeons. Recently, the use of diode laser in proctology has emerged as an alternative to the conventional surgical treatment. The laser beam causes shrinkage and degeneration that depend on the power and the duration of laser light application. It is also associated with minimal postoperative pain, bleeding, discharge and short hospital stay.

**Patients and Methods:** This prospective study was carried out on 76 patients with common anal surgical lesions categorized into 3 groups. Group 1 included 26 patients with hemorrhoids and underwent laser hemorrhoidoplasty, group 2 included 24 patients with chronic anal fissure and underwent closed laser lateral internal sphincterotomy whereas group 3 included 26 patients with perianal fistula and underwent either fistula laser closure (FILAC) or laser fistulotomy in the Gastrointestinal Surgery Unit, General Surgery Department, Tanta University Hospitals, during the study period (12 months, from February 2021 to February 2022 on 76 patients).

**Results:** Regarding group1, laser hemorrhoidoplasty (LHP) was associated with minimal postoperative pain using VAS score, minimal bleeding with no serious bleeding requiring intervention, short hospital stay and only one case of recurrence. There was significant relation between postoperative edema and grade 4 hemorrhoids. Regarding group 2, closed laser lateral internal sphincterotomy was associated with no complications except for postoperative itching in five

cases and was treated by local soothing agents. As for group 3, success rate was 73.9% among cases who underwent fistula laser closure (FILAC) and overall success rate was 76.9%. There was significant relation between recurrence and posterior position of the fistulous track of the intersphincteric type and significance between wide caliber of the track (more than 7mm) and recurrence.

**Conclusion:** Diode laser is a safe minimally invasive procedure for treatment of hemorrhoids, chronic anal fissure and perianal fistula.

*Keywords: Haemorrhoids; chronic anal fissure; perianal fistula; diode laser; laser hemorrhoidoplasty, FILAC.*

## 1. INTRODUCTION

Anorectal diseases are a group of medical disorders that occur at the junction of the anal canal and the rectum and their prevalence in general population is probably much higher than that seen in clinical practice as most patients do not seek medical attention [1].

Hemorrhoids, anal fissures, and fistulas are common benign anorectal diseases that have a significant impact on patient's life [2].

Hemorrhoidal disease is protrusion of plexus or blood vessels in the anal canal. The hemorrhoid may cause symptoms that are: bleeding, prolapse, itching, soiling of feces, and psychologic discomfort [3].

An anal fissure is a linear tear in the anal mucosa, usually extending from the dentate line to the anal verge. If one persists for more than 4-8 weeks, it is considered chronic [4].

An anal fistula is a persistent epithelialized tract from the anal canal to the perianal skin, and can be intersphincteric, transsphincteric, suprasphincteric, or extrasphincteric [5].

Surgical treatment has been always the definitive treatment for the previously mentioned lesions, even better than the medical choice [6].

Currently, patients undergoing surgical intervention either hemorrhoidectomy for piles or lateral internal sphincterotomy for chronic anal fissure or fistulectomy for perianal fistula, could experience variable intensity of postoperative pain, bleeding, delayed return to normal life style and recurrence rate that differs according to the adopted technique and the operator [7].

The commonly used laser energy in medicine are diode laser, carbon dioxide, argon, and Nd:YAG. The laser beam causes tissue shrinkage and degeneration at different depths depending on the laser power and the duration of laser light application. Recently, laser treatment using diode laser is a new minimal invasive and painless procedure and considered as alternative to the surgical choice and associated with less postoperative pain, less bleeding, early return to normal life [8].

### 1.1 Aim of the Work

The aim of this work was to evaluate the efficacy of diode laser in treatment of patients with symptomatic hemorrhoids, chronic anal fissure and perianal fistula, focusing on the postoperative pain, complications and return to normal daily activity.

## 2. PATIENTS AND METHODS

This study was a prospective study included 76 patients who were presented with common anal surgical lesions (hemorrhoids, chronic fissure and fistula). They were admitted to the general surgery department, Tanta University hospitals in the period between February 2021 and February 2022.

These patients were divided into three groups. Group 1 (G1) included 26 cases with hemorrhoids, group 2 (G2) included 24 cases with chronic anal fissure and group 3 (G3) included 26 cases with perianal fistula.

### Inclusion criteria:

- Age more than 18 years old.
- Second, third and fourth degrees of hemorrhoids.
- Chronic anal fissure.
- Perianal fistula.

**Exclusion criteria:**

- Acute anal fissure.
- Acutely inflamed thrombosed hemorrhoids.
- Patients affected by inflammatory bowel disease (IBD) affecting rectum or anus.

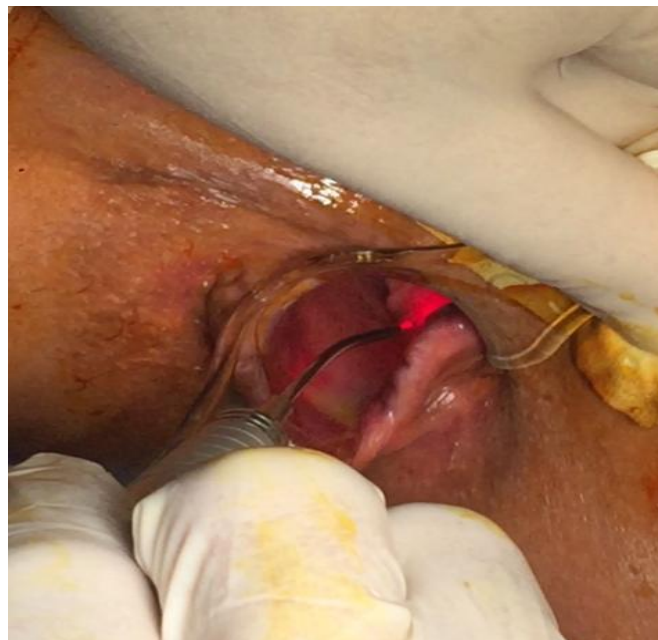**2.1 Preoperative Assessment**

All patients were subjected to full history taking, general examination, digital rectal examination to determine degree of hemorrhoids, position of anal fissure and internal and external openings of perianal fistula, routine laboratory investigations, colonoscopy to exclude cancer colon and rectum in patients more than 50 years old, endo-anal ultrasound for all cases of perianal fistula and MRI for cases with suspected complex perianal fistula.

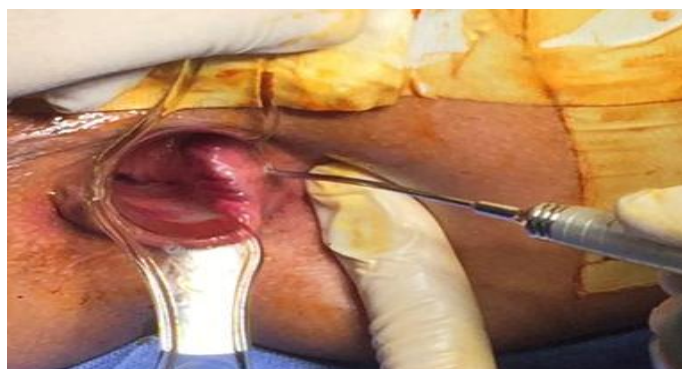**2.2 Operative technique**

**1-Group 1 (Hemorrhoids):** Laser hemorrhoidoplasty was defined by three positions. Position A was coagulation of the feeding vessel of the hemorrhoid by introduction of the laser bare fiber through the anus and about 80 joules were given without touching the mucosa to avoid its injury (Fig. 1).

Position B was done by making a skin micro-incision of 3 mm using the laser probe about 0.5 cm from the anal verge at the base of each hemorrhoid in the subcutaneous plane. The probe was driven through the incision in the submucosal tissue till reaching the area underneath the distal rectal mucosa (Fig. 2).



**Fig. 1. Coagulation of the feeding vessel**



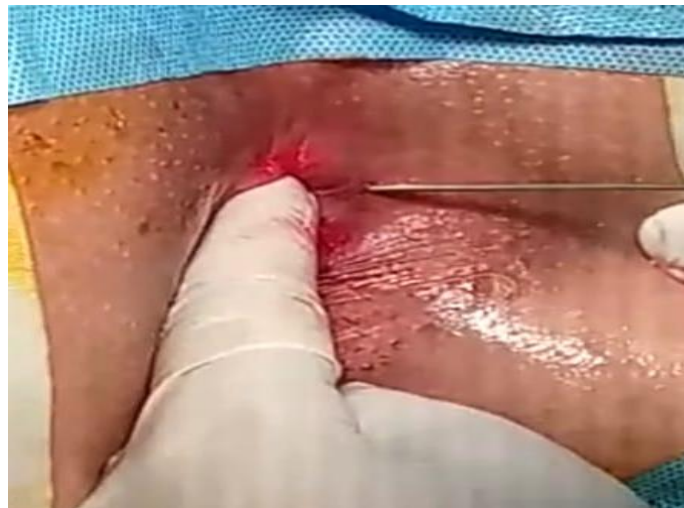**Fig. 2. Introduction of the laser probe into the subcutaneous plane**

- Effective pulses (about 100 joules) using laser generator were fired using bare fibers under 8 watts and wavelength 1470 nm. Then position C was achieved by giving another 80-100 joules to the cushion to achieve shrinkage of the hemorrhoids.
- Total number of joules for each hemorrhoid was about 250-300 joules.
- Ice packs were put inside the anus to produce cooling effect to avoid postoperative itching due to laser heat.
- In case of fourth degree hemorrhoids and large external component, mucopexy was

done to augment shrinkage of the hemorrhoid.

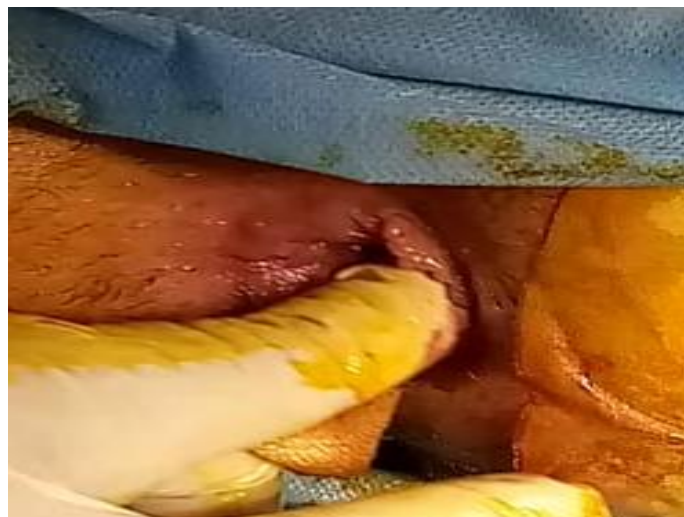#### **2-Group 2 (Chronic anal fissure):**

- Laser lateral internal sphincterotomy was done using bare fiber by closed method.
- Using closed method, palpation of the internal sphincter was followed by introduction of the laser probe through the skin towards the internal sphincter and the energy was given between 70-100 joules (Fig. 3).

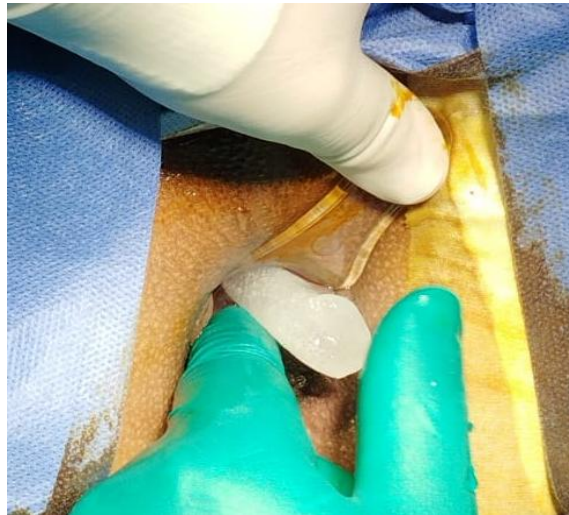


**Fig. 3. Introduction of laser probe towards the internal sphincter**

- Then, separation of the internal sphincter by index finger of the surgeon's left hand was done with minimal pressure to feel the defect in the IAS (Fig. 4).
- Ice pack was introduced inside the anus to avoid heat from laser energy and consequent postoperative itching (Fig. 5).



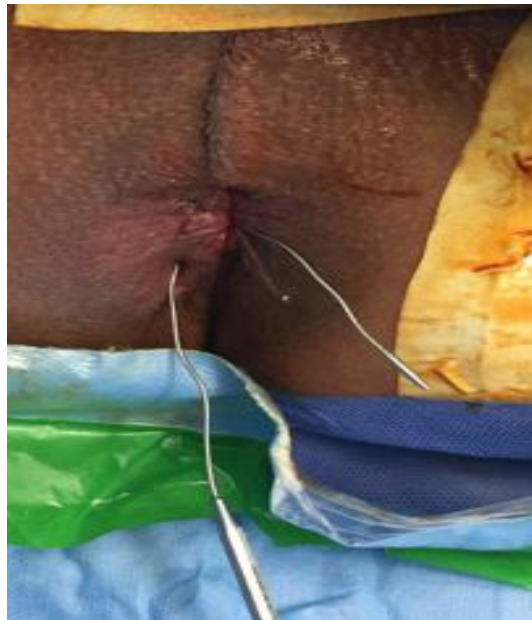**Fig. 4. Separation on internal sphincter fibers by index finger**



**Fig. 5. Application of ice packs through the anus**

**3-Group 3 (Perianal fistula):**

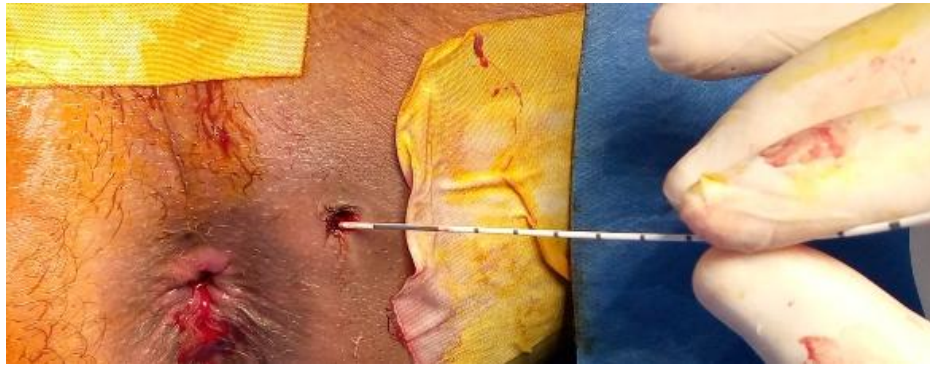- Fistula catheterization by probe was done for proper identification of the internal opening. In some cases injection of hydrogen peroxide was necessary to detect the internal opening (Fig. 6).



**Fig. 6. Catheterization of the fistulous track by probe**

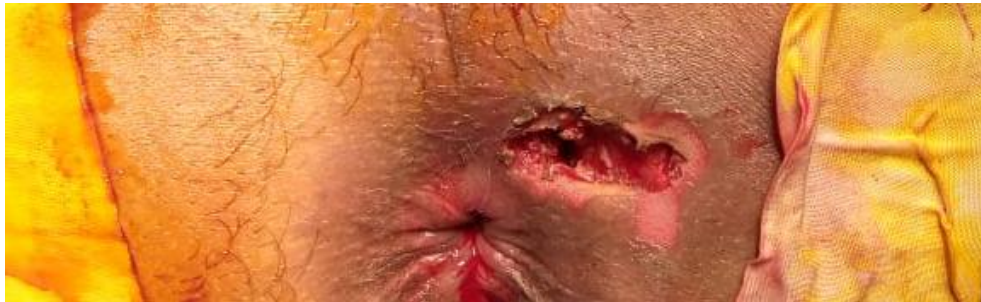- Closure of the internal orifice either by figure of eight VICRYL 3/0 suture or mucosal advancement flap was done. If the internal opening was not present or the track was blind ended, only FILAC was done.
- Introduction of laser radial fibers from internal to external orifices of the fistula. Laser closure of the fistulous track was done with simultaneous destruction and sealing of the track. 100 joules were given for each 1 cm of the track using radial fibers of 1470 nm in wavelength and 10 watts in energy (Fig. 7).





**Fig. 7. Closure of the track using radial fiber**

- Coagulation of the external orifice at the end of the procedure. In some cases where fistula was associated with discharge, proper drainage of the external orifice was achieved then curettage was done and was followed by wash with H<sub>2</sub>O<sub>2</sub> and saline (Fig. 8).



**Fig. 8. Drainage of the external opening in cases with associated abscess**

- In some cases of posterior intersphincteric fistula or track more than 7 mm in width, laser fistulotomy was done using bare fibers of 1470 nm in wavelength and 10 watts in energy. Ligation of the intersphincteric fistula track combined with FILAC was done in some cases with complex perianal fistula with. LIFT was done for ligation of the track proximally then FILAC was done for coagulation of the track distally.

#### **Follow up:**

- Assessment of postoperative pain using the visual analogue score (VAS), need of analgesics, postoperative bleeding (either spontaneous or post-defecation), edema and sero-mucous discharge was evaluated in the first 24 hours.
- Patients were discharged 24 hours after surgery and on the same day of the surgery if there was no complications and pain was less than 5 by VAS score.
- Follow up, weekly for one month and monthly for six months.

### **3. RESULTS**

**Group 1 (hemorrhoids):** 26 patients under went laser hemorrhoidoplasty ranging from 22 to 76 years old. 17 of them were males (65.4%) and 9 were females (34.6%), minimum age was 22 and maximum age was 76. 10 patients (38.5%) suffered from grade 2 hemorrhoids, 9 (34.6%) suffered from grade 3 hemorrhoids and 7 (26.9%) suffered from grade 4 hemorrhoids. Operative time ranged from 6-23 minutes with mean of  $13.19 \pm 5.04$  SD. Shrinkage of hemorrhoids occurred immediately postoperative at some extent and complete shrinkage occurred after one month (Figs. 9-11).

Postoperative pain was evaluated using VAS score, in the first 6 hours VAS ranged from 4-9 with mean of  $5.81 \pm 1.23$  SD, after 12 hours ranged from 1-7 with mean of  $4.19 \pm 1.70$  SD. After 24 hours VAS score ranged from 0-7 with mean of  $2.73 \pm 2.07$  SD. Three days after surgery VAS score ranged from 0-3 with mean of  $0.12 \pm 0.59$  SD. VAS score was 0 after one week, two weeks, one month, two months and

six months of follow up (Table 1). Postoperative bleeding was present in the form of spontaneous post-defecation spotting with no eventual serious bleeding requiring hemostasis. It occurred in three patients after 24 hours and was present in only one case after one week, two weeks, one, two and six months which was considered as recurrence. There was no postoperative discharge in all cases after 24 hours but discharge was present in two cases after one week in the form of infection and was treated conservatively by antibiotics as ceftriaxone or levofloxacin. Postoperative edema was present in 6 patients (23.1%) and was treated conservatively by local and systemic anti-inflammatory medications (Fig. 12). There was significance between grade of hemorrhoid and postoperative edema (P value was less than 0.001) as all of the six patients who

developed edema, they were grade 4 hemorrhoids. Also, there was relation between grade 4 hemorrhoid and the development of other postoperative complications but p value was not significant (0.066 in abscess and 0.260 in recurrence) (Table 3). Itching occurred in three patients (11.5%) mainly due to the heat caused by the laser probe and was treated by local soothing agents. Infection occurred in two patients (7.7%) and was treated by antibiotics. There was no incontinence or stenosis in all of the 26 patients and recurrence occurred only in one case (3.8%) and underwent conventional hemorrhoidectomy after six months of follow up (Table 2). Hospital stay ranged between one and two days with mean of  $1.12 \pm 0.33$  SD. Return to normal activities ranged between 2 and 7 days (mean  $3.73 \pm 1.34$  SD).

**Table 1. Descriptive analysis of group 1 according to pain (VAS) score (n = 26)**

Pain (VAS) score	Min. – Max.	Mean ± SD.	Median (IQR)
6hrs	4.0 – 9.0	5.81 ± 1.23	5.50 (5.0 – 7.0)
12hrs	1.0 – 7.0	4.19 ± 1.70	4.0 (3.0 – 5.0)
24hrs	0.0 – 7.0	2.73 ± 2.07	2.50 (1.0 – 5.0)
3 days	0.0 – 3.0	0.12 ± 0.59	0.0 (0.0 – 0.0)
1 week	0.0 – 0.0	0.0 ± 0.0	0.0 (0.0 – 0.0)
2 weeks	0.0 – 0.0	0.0 ± 0.0	0.0 (0.0 – 0.0)
1 month	0.0 – 0.0	0.0 ± 0.0	0.0 (0.0 – 0.0)
2 months	0.0 – 0.0	0.0 ± 0.0	0.0 (0.0 – 0.0)
6 months	0.0 – 0.0	0.0 ± 0.0	0.0 (0.0 – 0.0)

IQR: Inter quartile range; SD: Standard deviation

**Table 2. Distribution of group 1 according to complication (n = 26)**

Complication	No.	%
Post. Edema	6	23.1
Infection	2	7.7
Recurrence	1	3.8
Itching	3	11.5
Incontinence	0	0.0
Stenosis	0	0.0

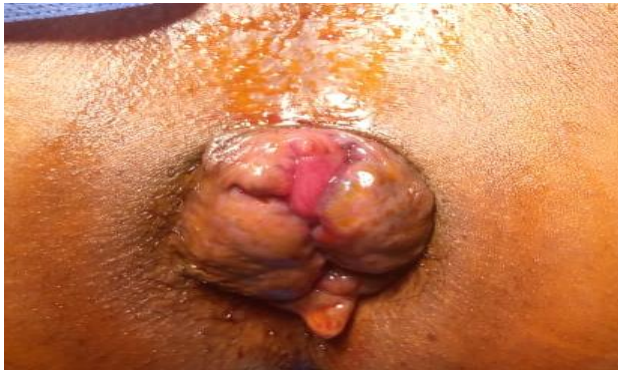**Table 3. Relation between grade and complication in group 1 (n = 26)**

	Grade						$\chi^2$	MC p
	II (n = 10)		III (n = 9)		IV (n = 7)			
	No.	%	No.	%	No.	%		
Post. edema	0	0.0	0	0.0	6	85.7	17.396	<0.001*
Infection	0	0.0	0	0.0	2	28.6	3.905	0.066
Recurrence	0	0.0	0	0.0	1	14.3	2.356	0.260
Itching	0	0.0	2	22.2	1	14.3	2.368	0.339
Incontinence	0	0.0	0	0.0	0	0.0	-	-
Stenosis	0	0.0	0	0.0	0	0.0	-	-

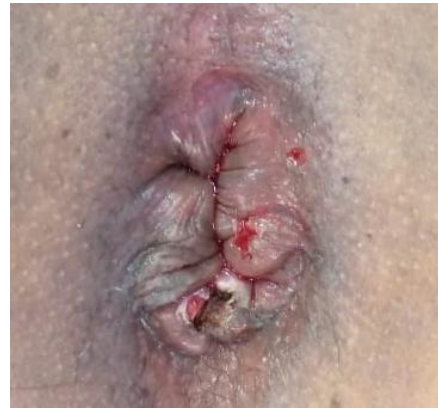$\chi^2$ : Chi square test; MC: Monte Carlo

p: p value for association between different categories

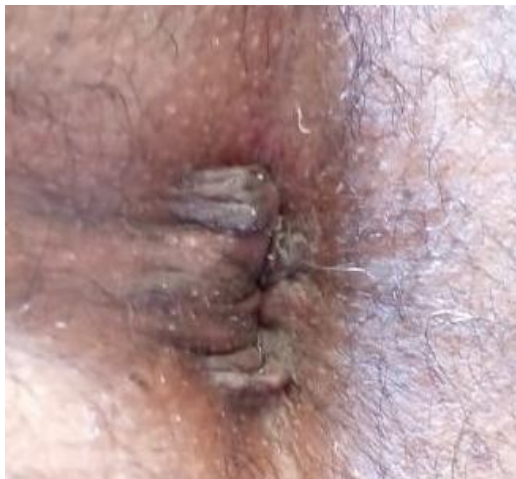\*: Statistically significant at  $p \leq 0.05$



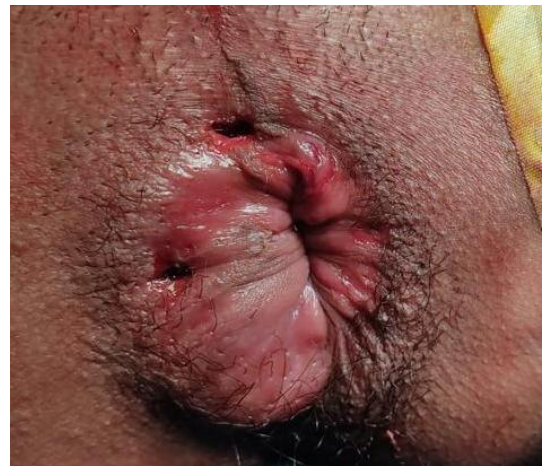**Fig. 9. Grade 4 hemorrhoids preoperative**



**Fig. 10. shrinkage of hemorrhoids immediately postoperative**



**Fig. 11. complete shrinkage of hemorrhoids after one month**



**Fig. 12. Postoperative edema after laser hemorrhoidoplasty**

**Group 2 (Chronic anal fissure):** Twenty four patients underwent laser closed lateral internal sphincterotomy using bare fibers of 1470 nm diode laser. Age ranged from 20 to 62 years old. From the 24 patients, 8 were males (33.3%) and 16 were females (66.7%). Operative time ranged from 3-12 minutes with mean of  $6.54 \pm 2.45$  SD. Postoperative pain was evaluated using VAS score. After 6 hours, VAS score ranged from 3-8 with mean of  $6.21 \pm 1.28$  SD, after 12 hours it ranged from 1-7 with mean of  $3.83 \pm 1.61$  SD, after 24 hours VAS score ranged from 0-6 with mean of  $1.58 \pm 1.32$  SD and after 3 days it ranged from 0-1 with mean of  $0.04 \pm 0.20$  SD. VAS score was 0 after one week, two weeks, one month, two months and six months (Table 4). Regarding postoperative bleeding, only one case (4.2%) developed bleeding during the first 24 hours after surgery in the form of post

defecation spotting with no serious bleeding requiring surgical hemostasis. There was no bleeding after 3 days and up to six months during the follow up. There was no postoperative discharge in the first 24 hours after surgery, but two cases (8.3%) developed serous discharge after three days and continued to one week, then the discharge stopped after two weeks and up to six months of follow up. No cases of incontinence or stenosis or recurrence were recorded in the study. No cases of postoperative edema or infection were recorded. Itching occurred in 5 cases (20.8%) and was treated by local soothing agents (Table 5). Hospital stay ranged from 1-2 days and return to normal activities ranged from 2-7 days. Preoperative and postoperative photos of healed chronic anterior and posterior anal fissures are shown in Figs. 13-15.

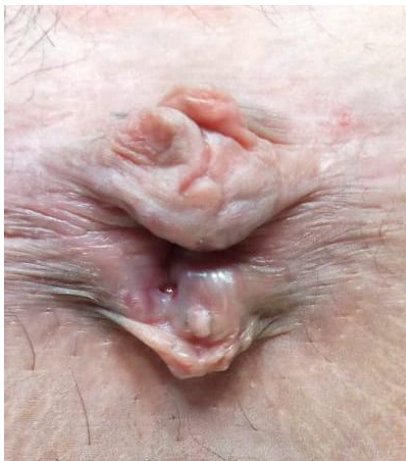

**Table 4. Descriptive analysis of group 2 according to pain (VAS) score (n = 24)**

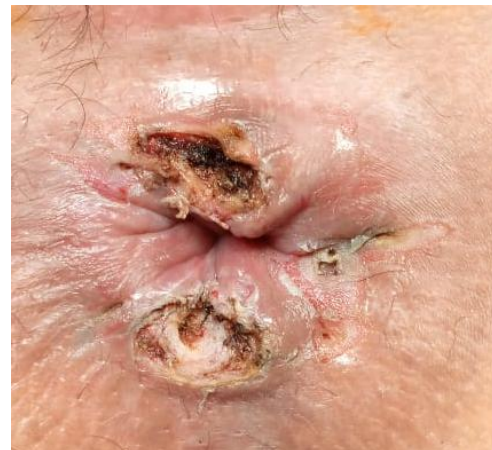Pain (VAS) score	Min. – Max.	Mean ± SD.	Median (IQR)
6hrs	3.0 – 8.0	6.21 ± 1.28	6.50 (5.0 – 7.0)
12hrs	1.0 – 7.0	3.83 ± 1.61	4.0 (3.0 – 5.0)
24hrs	0.0 – 6.0	1.58 ± 1.32	1.0 (1.0 – 2.0)
3 days	0.0 – 1.0	0.04 ± 0.20	0.0 (0.0 – 0.0)
1 week	0.0 – 0.0	0.0 ± 0.0	0.0 (–)
2 weeks	0.0 – 0.0	0.0 ± 0.0	0.0 (–)
1 month	0.0 – 0.0	0.0 ± 0.0	0.0 (–)
2 months	0.0 – 0.0	0.0 ± 0.0	0.0 (–)
6 months	0.0 – 0.0	0.0 ± 0.0	0.0 (–)

**Table 5. Distribution of group 2 according to complication (n = 24)**

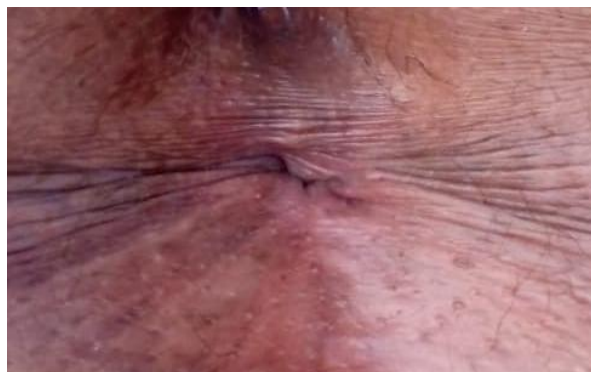Complication	No.	%
Post. Edema	0	0.0
Infection	0	0.0
Recurrence	0	0.0
Itching	5	20.8
Incontinence	0	0.0
Stenosis	0	0.0



**Fig. 13. Anterior and posterior Chronic anal fissures preoperative.**



**Fig. 14. Chronic anal fissure immediately postoperative**



**Fig. 15. Healed chronic anal fissure after one month.**

**Group 3 (Perianal fistula):** Twenty six consecutive patients underwent laser treatment for perianal fistula. Of the twenty patients, 17 of them (65.4%) were males and 9 (34.6%) were females. Age ranged from 17 to 72 years with mean of  $42.58 \pm 12.37$  SD. Regarding position of the fistula 13 cases (50%) were anterior and 12 (46.2%) were posterior and one case (3.8%) had both anterior and posterior fistulae and three cases were recurrent (11.5%). Regarding type of the fistula, 20 cases had intersphincteric tracks (76.9%), 5 cases had transsphincteric tracks (19.2%) and one case had suprasphincteric track (3.8%). Affection of the external sphincter was present in 6 patients (23.1%) and was documented by endo-anal ultrasound as routine imaging for all the cases of perianal fistula. Three cases were associated with discharge or abscess cavity (11.5%), 10 patients (38.5%) had history of previous anorectal surgery (hemorrhoids, anal fissure, anal fistula and perianal abscess). Caliber of the track ranged from 3-11 mm with mean of 6.36 mm. 21 patients (80.2%) had caliber of  $\leq 7$  mm while 5 patients (19.2%) had a caliber of more than 7 mm. Length of the tracks ranged from 2.3-8 cm with mean of  $3.75 \pm 1.49$  SD. 22 patients (88.5%) had single fistulous track, 2 patients (7.7%) had two tracks and one patient had 4 tracks (3.8%) which was biopsied to exclude inflammatory bowel disease, so total number of tracks was 31. Operative time ranged from 5-23 minutes with mean of  $11.73 \pm 4.90$  SD. 23 patients (88.5%) underwent FILAC using radial fiber of 1470 nm diode laser and 3 patients (11.5%) underwent fistulotomy using bare fiber of diode laser of 1470 nm. Two patients (7.7%) underwent FILAC combined with ligation of the intersphincteric fistula tract (LIFT) and three patients (11.5%) underwent FILAC with excision of the external opening for proper drainage. Hospital stay ranged from 1-3 days and return to normal activities ranged from 3-12 days.

Postoperative pain was evaluated using VAS score. 6 hours postoperative, VAS score ranged from 4-8 with mean of  $6.27 \pm 1.28$  SD, after 12 hours it ranged from 2-8 with mean of  $4.35 \pm 2.08$ , after 24 hours VAS score continued to decrease with range from 0-8 with mean of  $2.54 \pm 2.10$  SD. After 3 days, VAS score ranged from 0-2 with mean of  $0.31 \pm 0.62$  SD, after one week it ranged from 0-1 with mean of  $0.04 \pm 0.20$  SD, then it reached 0 after 2 weeks, one month, two months and six months of follow up (Table 6). There was no postoperative bleeding in all the 26 cases during the first 24 hours and up to 6 months of follow up. Regarding postoperative discharge, no discharge was recorded in the first 24 hours, then discharge was recorded during follow up in the third day in 21 patients (80.8%), in 15 patients (57.7%) after one week, in 9 patients (34.6%) after two weeks and in 6 patients (23.1) after one month, two months and six months of follow up which was considered as recurrence (Table 7). It is important to mention that regarding four patients who suffered from recurrence, they all had posterior intersphincteric fistula and underwent FILAC, wide caliber track (more than 7 mm) and variable track length. That is why we performed laser fistulotomy in the other patients who suffered from posterior intersphincteric fistula.

During the follow up which was up to six months, postoperative perianal edema occurred in 2 patients (7.7%) and was treated by anti-inflammatory medications, infection developed in one case (3.8%) which was among the recurrence group and was treated by antibiotics and was followed by open fistulotomy. No incontinence or stenosis occurred in all cases of the study, itching developed in two cases (7.7%) and was treated by local soothing agents. Success rate of the cases that underwent FILAC was 73.9% and 100% in the cases that underwent laser fistulotomy. Recurrence occurred in 6 patients (23.1%) and they underwent lay open fistulotomy (Table 8).

**Table 6. Descriptive analysis of group 3 according to pain (VAS) score (n = 26)**

Pain (VAS) score	Min. – Max.	Mean $\pm$ SD.	Median (IQR)
6hrs	4.0 – 8.0	$6.27 \pm 1.28$	7.0 (5.0 – 7.0)
12hrs	2.0 – 8.0	$4.35 \pm 2.08$	4.0 (2.0 – 6.0)
24hrs	0.0 – 8.0	$2.54 \pm 2.10$	2.0 (1.0 – 4.0)
3 days	0.0 – 2.0	$0.31 \pm 0.62$	0.0 (0.0 – 0.0)
1 week	0.0 – 1.0	$0.04 \pm 0.20$	0.0 (0.0 – 0.0)
2 weeks	0.0 – 0.0	$0.0 \pm 0.0$	0.0 (–)
1 month	0.0 – 0.0	$0.0 \pm 0.0$	0.0 (–)
2 months	0.0 – 0.0	$0.0 \pm 0.0$	0.0 (–)
6 months	0.0 – 0.0	$0.0 \pm 0.0$	0.0 (–)

**Table 7. Distribution of group 3 according to discharge (n = 26)**

Discharge	No		Yes	
	No.	%	No.	%
6hrs	26	100.0	0	0.0
12hrs	26	100.0	0	0.0
24hrs	26	100.0	0	0.0
3 days	5	19.2	21	80.8
1 week	11	42.3	15	57.7
2 weeks	17	65.4	9	34.6
1 month	20	76.9	6	23.1
2 months	20	76.9	6	23.1
6 months	20	76.9	6	23.1

**Table 8. Distribution of group 3 according to complication (n = 26)**

Complication	No.	%
Post. Edema	2	7.7
Infection	1	3.8
Recurrence	6	23.1
Itching	2	7.7
Incontinence	0	0.0
Stenosis	0	0.0

**Table 9. Relation between position of fistula and complication in FILAC cases (n = 23)**

Complication	Position of fistula						$\chi^2$	MC p
	Anterior (n = 13)		Posterior (n = 9)		Anterior & posterior (n = 1)			
	No.	%	No.	%	No.	%		
<b>Post. Edema</b>								
No	13	100.0	7	77.8	1	100.0	3.664	0.221
Yes	0	0.0	2	22.2	0	0.0		
<b>Infection</b>								
No	13	100.0	8	88.9	1	100.0	2.934	0.442
Yes	0	0.0	1	11.1	0	0.0		
<b>Recurrence</b>								
No	13	100.0	3	33.3	1	100.0	12.173*	0.001*
Yes	0	0.0	6	66.7	0	0.0		
<b>Itching</b>								
No	13	100.0	7	77.8	1	100.0	3.664	0.221
Yes	0	0.0	2	22.2	0	0.0		
<b>Incontinence</b>								
No	13	100.0	9	100.0	1	100.0	–	–
Yes	0	0.0	0	0.0	0	0.0		

$\chi^2$ : Chi square test; MC: Monte Carlo  
 p: p value for association between different categories  
 \*: Statistically significant at  $p \leq 0.05$



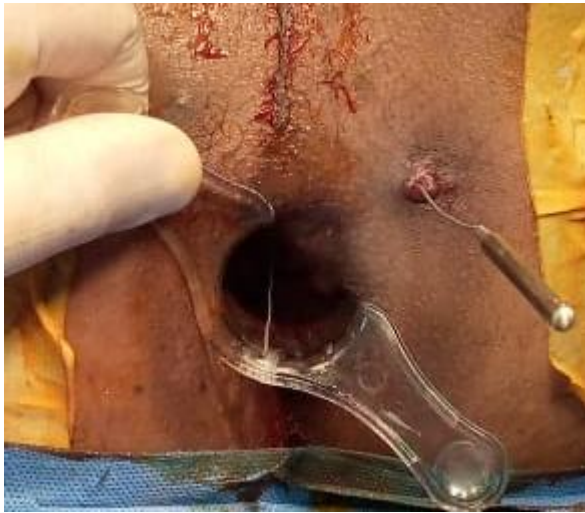**Table 10. Relation between caliber of the track and complication in FILAC cases (n = 23)**

Complication	Caliber of the track (mm)						
	N	Mean ± SD.	Median (Min. – Max.)	≤7 (n = 18)		>7 (n = 5)	
				No.	%	No.	%
<b>Post. Edema</b>							
No	21	6.40 ± 1.78	6.0 (3.0 – 11.0)	16	88.9	5	100.0
Yes	2	6.50 ± 0.71	6.50 (6.0 – 7.0)	2	11.1	0	0.0
Test of Sig. (p)		t=0.077,p=0.939		χ <sup>2</sup> =0.608, <sup>FE</sup> p=1.000			
<b>Infection</b>							
No	22	6.43 ± 1.74	6.45 (3.0 – 11.0)	17	94.4	5	100.0
Yes	1 <sup>#</sup>	6.0 <sup>#</sup>		1	5.6	0	0.0
Test of Sig. (p)		–		χ <sup>2</sup> =0.290, <sup>FE</sup> p=1.000			
<b>Recurrence</b>							
No	17	5.79 ± 1.23	6.0 (3.0 – 7.50)	16	88.9	1	20.0
Yes	6	8.17 ± 1.72	8.0 (6.0 – 11.0)	2	11.1	4	80.0
Test of Sig. (p)		t=3.678*, p=0.001*		χ <sup>2</sup> =9.631*, <sup>FE</sup> p=0.008*			
<b>Itching</b>							
No	21	6.35 ± 1.75	6.0 (3.0 – 11.0)	17	94.4	4	80.0
Yes	2	7.0 ± 1.41	7.0 (6.0 – 8.0)	1	5.6	1	20.0
Test of Sig. (p)		t=0.504,p=0.619		χ <sup>2</sup> =1.028, <sup>FE</sup> p=0.395			
<b>Incontinence</b>							
No	23	6.41 ± 1.71	6.0 (3.0 – 11.0)	18	100.0	5	100.0
Yes	0	–		0	0.0	0	0.0
Test of Sig. (p)		–		–			

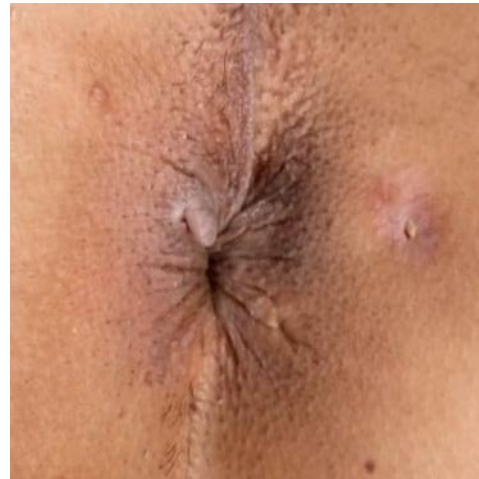
SD: Standard deviation; t: Student t-test; χ<sup>2</sup>: Chi square test; FE: Fisher Exact; p: p value for association between different categories; \*: Statistically significant at p ≤ 0.05

**Table 11. Relation between posterior fistula and caliber of the track >7mm and recurrence in FILAC cases (n = 23)**

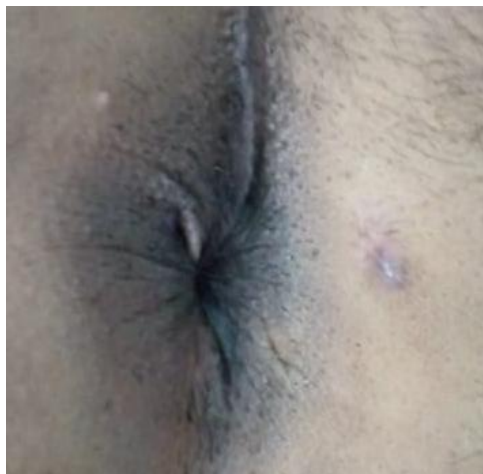
Recurrence	Posterior fistula and caliber of the track >7mm				χ <sup>2</sup>	<sup>FE</sup> p
	No (n = 19)		Yes (n = 4)			
	No.	%	No.	%		
No	17	89.5	0	0.0	13.719	0.002*
Yes	2	10.5	4	100.0		



**Fig. 16. Anterior transsphincteric perianal fistula intraoperative**



**Fig. 17. Anterior transsphincteric perianal fistula after one week**



**Fig. 18. Anterior transsphincteric perianal fistula after one month**

There was relation between the posterior position of the fistula and recurrence that was significant (P value was less than 0.001), while other complications as edema, itching and infection were not significantly related to the position of the fistula (Table 9). It is important to mention that recurrence was significant in the cases who had a caliber track more than 7 mm and underwent FILAC. 5 cases had a caliber track more than 7 mm and 4 of them (80%) suffered from recurrence, while 18 cases had caliber of 7 mm or less and only 2 of them (11.1%) suffered from recurrence (Table 10). Other complications like edema, itching and abscess formation had no significance in relation to the caliber of the track. There was no significance between type of the fistula and postoperative complications yet, all the recurrent cases were of the

intersphincteric type. Also, there was no significance between length of the fistulous track and postoperative complications. It is also important to mention that there was significant between recurrence and all the cases who had both posterior fistula and a track caliber more than 7mm, P value was 0.002. (Table 11). Preoperative and postoperative photos of healed transsphincteric fistula are illustrated in Figs. 16-18.

#### **4. DISCUSSION**

Treatment of anorectal diseases has always been a challenge as there are many treatment options and this multiplicity added more confusion about the best modality for treatment which is still controversial [9]. In our study we

used diode laser for treatment of common anal surgical lesions which are hemorrhoids, chronic fissure and fistula. 76 patients were included in the study, 26 patients suffered from hemorrhoids, 24 suffered from chronic anal fissure and 26 patients suffered from perianal fistula.

**Hemorrhoids:** In our study we used diode laser of wavelength 1470 nm 8 watts, total application of joules ranged from 250-350 joules for each hemorrhoid. Mucopexy was associated with laser hemorrhoidoplasty in some cases with grade 4 hemorrhoids. Follow up period was up to 6 months. Regarding wavelength, Jahanshahi et al, Maloku et al and Naderan et al. used diode laser of 980 nm wavelength while Weyand et al, Bruscianno et al. and Poskus et al. used diode laser of 1470 nm wavelength which was similar to our study [3,6,8,10-12]. Follow up ranged from 6 months to one year. In our series, postoperative pain was very low as VAS score reached mean of 2.37 after the first 24 hours. Post defecation bleeding occurred in 2 patients but there was no serious postoperative bleeding that required hemostasis. Discharge was reported in two patients in the form of serous discharge that stopped after three days. No incontinence was recorded in all of the 26 patients. Postoperative edema was reported in 6 patients and all of them were grade 4, there was significant relation between postoperative edema and grade of hemorrhoids. Itching occurred in 3 patients and was treated by soothing agents. Postoperative infection occurred in 2 patients and they were grade 4 but there was no significance between infections and grading of hemorrhoids may be due to small sample size. Recurrence was recorded only in one case. Jahanshahi et al. reported in a study in 2012 performed on 341 patients that diode laser treatment of hemorrhoids was associated with minimal postoperative pain and early return to normal activities which was similar to our study. There was no recurrence among all the 341 patients. They also mentioned that there was no limitation regarding grading of hemorrhoids. Yet, the technique is expensive in comparison with other modalities and long term follow up is required for better assessment of the results [6]. Maloku et al. in 2014 compared between laser hemorrhoidoplasty and open hemorrhoidectomy for third and fourth degrees of hemorrhoids. They concluded that Pain was significantly lower in laser hemorrhoidoplasty than open hemorrhoidectomy and that laser hemorrhoidoplasty was associated with less operative time and early return to normal

activities [3]. Weyand et al. in 2017 mentioned that energy given during laser hemorrhoidoplasty should be reduced to a minimum and not exceed 500 joules to avoid complications as perianal edema and thrombosis especially of the external component of the hemorrhoid. They also performed associated mucopexy in indicated cases of grade 4 hemorrhoids to augment proper shrinkage which was similar to our study [11]. Giamundo et al. in 2020 also performed mucopexy with hemorrhoidal laser procedure (HeLP) for treatment of third degree hemorrhoids. The procedure had promising results regarding postoperative pain, bleeding and return to normal activities [13]. On the other side, Poskus et al. in 2020 compared laser hemorrhoidoplasty with sutured mucopexy and open hemorrhoidectomy in treatment for second and third degrees of hemorrhoids. They concluded that LHP is associated with less postoperative pain than the other two procedures, less operative time and early return to normal activities and that patients rated LHP better than the other modalities. They also mentioned that over one year of follow up, open hemorrhoidectomy was more effective than LHP regarding recurrence and that LHP had higher cost than the other procedures [12]. Bruscianno et al. in 2020 had similar results to our study when laser hemorrhoidoplasty was performed on 50 patients with symptomatic hemorrhoids. The procedure was associated with minimal discomfort, little postoperative pain which reached a mean VAS value of 2 (range 0–3), while in the subsequent days, the VAS value decreased to 0, short hospital stay, early return to normal activities and no recurrence. They also proposed that the use of wavelength of 1470 nm penetrated only 2 mm which lead to optimum shrinkage of hemorrhoidal tissue and was selectively better adsorbed by hemoglobin than Nd:YAG laser [10,14]. Naderan et al. in 2017 also proposed that laser hemorrhoidoplasty had better outcome than Milligan Morgan hemorrhoidectomy regarding operative time, postoperative pain, bleeding but had higher cost. They also reported thrombosis of external hemorrhoids in 2 patients out of 30 as the external part could lose its venous drainage which lead to thrombosis [8]. Nagdy et al. in 2022 compared laser hemorrhoidoplasty with open hemorrhoidectomy for treatment of third and fourth degrees of hemorrhoids, they concluded that LHP was better in the terms of postoperative pain, bleeding, hospital stay and return to normal life [15].

**Chronic anal fissure:** The use of laser in treatment of chronic anal fissure is not common in chronic anal fissure in comparison to hemorrhoids and perianal fistula. Esfahani et al. used carbon dioxide laser as a novel method in treatment of anal fissure. The study revealed that this new laser-based surgery is a simple, safe, and effective procedure to treat the anal fissure that can be performed with local anesthesia in an outpatient clinic with minimal postoperative morbidity [16]. In our study, 24 patients underwent closed method of laser lateral internal sphincterotomy. Diode laser of 1470 nm wavelength was used together with bare fibers. Total number of joules ranged between 70-100 joules. In our study, laser closed lateral internal sphincterotomy was associated with minimal discomfort, little postoperative pain and early return to daily activities. Itching was present in 5 cases and treated by local soothing agents, there was no incontinence nor recurrence were recorded in all of our patients. Hussein et al. in 2020 used diode laser in hemorrhoids, anal fissure and anal fistula. The technique they used for anal fissure was open method of lateral internal sphincterotomy (LIS), but instead of cutting the internal sphincter by scalpel or diathermy, they used the laser probe [17]. Alam et al. in 2021 performed the same technique as ours for anal fissure. They performed laser hemorrhoioplasty and closed laser LIS on 120 patients complaining of anal fissure and hemorrhoids. The most frequently reported complications were bleeding in 63 (52.5%) cases, pain in 55 (45.8%), and itching in 21 (22%). They concluded that diode Laser surgery was a minimally invasive procedure that can be done even as a day-care procedure that offers several advantages over traditional surgery. Laser effectively treated hemorrhoids and anal fissure, improved symptoms and reduced postoperative pain [18].

**Perianal fistula:** Treatment of perianal fistula has been always challenging despite the presence of many treatment options. The most common causes for failure or recurrence of the fistula are missed internal opening, missed side tracks and improper drainage. Incontinence is the most feared complication while treating complex anal fistula with affection of the sphincters specially in conventional surgery [19,20]. Wilhelm et al. was the first to use radial emitting diode laser fibers for treatment of perianal fistula in 2011 when he ran a pilot study on 11 patients suffering from perianal fistula. First, all of the eleven patients underwent

drainage of perianal abscess and seton for localization of the internal opening and reduction of the local infection [21]. He used diode laser of wavelength 1470 nm as it had optimal adsorption curve in water with defined penetration depth limited to 2–3 mm which was better than other wavelengths as 980 nm which was associated with vascular injury while treating varicose veins using laser [22,23]. Wilhelm closed the internal opening by VICRYL 2/0 suture together with advancement flap, introduced the laser probe through the external opening, applied energy at 13 watts with continuous retraction of the probe at rate of 3 seconds for each one centimeter. Success rate was 81.8%. Wilhelm proposed that sealing of perianal fistula using radial emitting laser fiber (FILAC) was a promising sphincter saving procedure with minimal complications and further studies needed to be done for further assessment of this novel technique [21]. In our study, 26 patients under laser treatment for perianal fistula, 23 underwent FILAC and 3 underwent laser fistulotomy. 13 of the patients had anterior fistula, 12 had posterior fistula and one case had combined anterior and posterior fistulae. 20 cases were of intersphincteric type, 5 were transsphincteric and one case was suprasphincteric type. Regarding caliber of the track 21 patients had their caliber track of 7mm or less while the other 5 were more than 7 mm. Mean length of the track was 3.75 cm. In our study, diode laser of 1470 nm, 10 watts was used with radial fibers except in laser fistulotomy we used bare fibers. We did not use seton as Wilhelm et al. did, so in case of associated abscess or infection, wide excision of external opening and drainage of abscess cavity was done. Catheterization of the fistula was followed by introduction of laser probe from external to internal opening so that FILAC could be started from internal opening. Energy was applied at a rate of 100 joules per centimeter, sticky sensation was felt at each time the probe was retracted which was considered as a good sign for sealing and fibrosis of the track. The internal opening was closed by Vicryl 3/0 suture. Endo-anal mucosal flap was done in two cases for closure of the internal opening. LIFT technique was accompanied with FILAC in two cases. We recorded overall success rate of 76.9%, and 73.9% among the patients who underwent FILAC. Giamundo et al. in 2014 performed FILAC on 35 patients with transsphincteric fistula or anterior intersphincteric fistula, superficial fistula which could be treated by fistulotomy was excluded. 16 patients had previous seton, both 1470 nm and 980 nm wavelengths were used,



internal opening was left without any means of closure, excessive debridement of the track was avoided as the author suggested that it would cause unnecessary widening of the track which would increase the possibility of recurrence [7]. Success rate in their study was 71.4%, the author reported similar results to our study regarding operative time, postoperative pain, bleeding and incontinence. They also suggested that 1470 nm wavelength had better sealing effect and less thermal damage than 980 nm wavelength. Also, patients who had previous seton had better success rate as seton localized the track and minimized its caliber [7]. Giamundo et al. proposed that FILAC is a minimally invasive sphincter saving procedure with minimal postoperative complications, favorable results and short learning curve. They described the technique as a blind one which could not detect any side branches of the fistula which could cause recurrence. Also the expensive cost was considered a disadvantage from the author's point of view [7]. Öztürk et al. in 2014 reported high success rate (82%) when he performed FILAC on 50 patients with transsphincteric or intersphincteric fistula. Seton was used for 3-4 weeks before FILAC if there is associated abscess. They suggested that debridement of the track by cytology brush was an important step to avoid widening of the track and as hemoglobin was the ideal protein for sealing the track while in our study a simple curette was used for debridement of the track. 100 joules per cm was given and the internal opening was not closed. The author proposed that to and fro movement towards the internal opening while performing FILAC was essential to augment sealing of the track. The authors described the procedure as an effective one for treatment of anal fistula specially if the external sphincter is involved [24]. Giamundo et al. in 2015 reported 71.1% success rate over 30 months of follow up of 45 patients who underwent FILAC using diode laser of 1470 nm wavelength. They assumed that the best healing rates were associated with who had been previously treated by loose seton 8 weeks before laser treatment (79%) while healing rate in patients without seton was 62%. They also assumed that better healing rate was achieved when length of the track was 4 cm or more and that fistulas with 2 cm or less in length should not be treated with FILAC. Also, to and fro movement which was performed by Öztürk et al. should be avoided as this could hamper the healing effect of the laser [24,25]. In fact, this back and forth movement was not done in our study as the newly forming tissue in the lumen of

the fistula was still incomplete and vulnerable during the procedure and could be easily perforated by the laser probe if it was pushed back into the treated tract [25]. The first long follow up period for patients who underwent FILAC was 5 years when Wilhelm et al. in 2017 reported success rate of 64.1% on 117 patients suffering from perianal fistula. The authors suggested that placement of seton lead to easy introduction of the laser probe from external to internal opening (Seldinger maneuver) [26]. Considering suprasphincteric fistula, the laser probe pass introduced through the internal fistula opening to reach the "turning point" of the fistula track to obliterate the intersphincteric component [26]. In recurrent patients, we performed fistulotomy after six months, while Wilhelm et al. performed re-FILAC or fistulotomy or fistulectomy. They reported secondary success rate of 88%. They proposed that FILAC could be considered as a sensible first line for treatment of perianal fistula and that failed FILAC permitted easier fistulectomy [26]. Carvalho et al. in 2017 excised the external opening for better wound drainage and did not use seton and that was similar to what was done in our study. Yet, instead of closure of the internal opening by sutures, they closed it by myo-mucosal flap [27]. Lauretta et al. in 2018 proposed that the only significant factor in fistula treatment by FILAC was the length of the track although it was not significant in our series. Success rate in fistulas with track length less than 3 cm was 58.3% while it was 16.6% in fistulas with track length more than 3 cm unlike Giamundo et al. who suggested that success rate was associated with longer fistulous tracks while in our study where was no significance between length of the track and recurrence rate. The authors reported total success rate of 33.3% including 30 patients with transsphincteric fistula [28]. Terzi et al. in 2018 reported 40% success rate in a study included 103 patients. Seton was not used before definitive treatment and the internal opening was not closed, this could be the cause for the disappointing success rate. They also recognized FILAC as a considerable treatment option for anal fistula with modest expectations and possibility of reapplication [29]. Gorgun, et al. and Marref et al. in 2019 proposed that high transsphincteric fistula and suprasphincteric fistula would get the most benefit from FILAC due to the advantage of sparing the sphincter from damage which could not be present in other conventional measures [30,31]. It was also suggested that patients with abscess or infection should undergo drainage and placement of loose

seton to allow healing of the infection and convert it to a simple track with no cavity. Also, the internal opening could be closed with figure of 8 VICRYL suture or left without closure but the external opening should be left open or even excised for proper drainage [30,32]. Regarding closure of internal opening, Serin et al. in 2020 proposed that closure of the internal opening by VICRYL suture was an important factor to prevent recurrence of the fistula [33]. In our study, FILAC was combined with LIFT in two cases with high transsphincteric fistula in order to achieve good results. Also, Ahmed.A, et al. in 2022 combined FILAC with LIFT and VAAFT to treat high transsphincteric and suprasphincteric fistula in 45 patients. Overall success rate was 91.1% with no incontinence or major postoperative complications [34]. As FILAC was considered as a blind technique, it was supposed that VAAFT could be combined with FILAC to overcome this potential pitfall and make side branches visible [35]. The authors proposed that the combination of sphincter saving procedures improved healing of the fistula and was considered as promising and effective step towards the definitive management of complex perianal fistulas [34]. In our series, there was significance between the caliber of the track and the recurrence as fistula with caliber more than 7 mm was more likely to recur. This was supported by Giamundo et al. when he proposed that the diameter of fistula tracts also deserved careful consideration. Despite the difference in the amount of energy given, the shrinking effect caused by laser energy should allow fistulas to heal with diameters not exceeding 4–5 mm [35,36]. Fistulas with large caliber may not be efficiently treated with laser and this aspect could be responsible for the higher failure rates in some series as Giamundo et al. reported failure rate of 21.7% and recurrence rate of 11.4% over 180 patients who underwent FILAC during 10 years of experience of the author. They also reported that seton placement was statistically significant in relation to recurrence [36]. Regarding position of the fistula, in our study there was significance between posterior position of the fistula and recurrence that is why we performed fistulotomy using laser probe in 3 cases with posterior intersphincteric fistula. There is no study at the moment supported this event, but Giamundo et al included only anterior intersphincteric fistula and not posterior ones as most of posterior intersphincteric fistulas are superficial and fistulotomy is a sufficient procedure for their definitive treatment [25]. Our study was not the first study to perform

fistulotomy using laser probe, Hussein, B.G., et al. also performed laser fistulotomy for patients suffering from anal fistula. Laser fibers are thought to be better than diathermy as to avoid remote injury and excess burning of tissue which would to faster healing [17].

## 5. CONCLUSION

Based on our study we conclude that diode laser is a safe minimally invasive procedure for treatment of hemorrhoids, chronic anal fissure and perianal fistula and is associated with minimal postoperative pain, short hospital stay and early return to normal activities but the procedure is associated with high cost which can be the only limitation. We recommend the use of diode laser in a large number of patients for treatment of hemorrhoids, chronic anal fissure and perianal fistula as a new innovation and consider it as a better alternative than conventional surgery for treatment of these patients.

## ETHICAL APPROVAL

As per international standard or university standard written ethical approval has been collected and preserved by the author(s).

## CONSENT

As per international standard or university standard, patients' written consent has been collected and preserved by the author(s).

## ACKNOWLEDGEMENTS

All authors had equal role in design, work, statistical analysis and manuscript writing.

## COMPETING INTERESTS

Authors have declared that no competing interests exist.

## REFERENCES

1. Gopal DV. Diseases of the rectum and anus: a clinical approach to common disorders. Clin Cornerstone. 2002;4(4):34-48.
2. Crea N, Pata G, Lippa M, Chiesa D, Gregorini ME, Gandolfi P. Hemorrhoidal laser procedure: short- and long-term results from a prospective study. Am J Surg. 2014;208(1):21-5.

3. Maloku H, Gashi Z, Lazovic R, Islami H, Juniku-Shkololli A. Laser hemorrhoidoplasty procedure vs open surgical hemorrhoidectomy: A trial comparing 2 treatments for hemorrhoids of third and fourth degree. *Acta Inform Med.* 2014;22(6):365-7.
4. Kelli M, Bullard K, Rothenberger D. Colon rectum and anus in: *Schwartz's Principles of Surgery.* 9th ed. New York: McGraw-Hill. 2010;1059-60.
5. Sugrue J, Nordenstam J, Abcarian H, Bartholomew A, Schwartz JL, Mellgren A, et al. Pathogenesis and persistence of cryptoglandular anal fistula: a systematic review. *Tech Coloproctol.* 2017;21(6): 425-32.
6. Jahanshahi A, Mashhadizadeh E, Sarmast MH. Diode laser for treatment of symptomatic hemorrhoid: a short term clinical result of a mini invasive treatment, and one year follow up. *pol prz chir.* 2012;84(7):329-32.
7. Giamundo P, Geraci M, Tibaldi L, Valente M. Closure of fistula-in-ano with laser–FiLaC™: an effective novel sphincter-saving procedure for complex disease. *Colorectal Dis.* 2014;16(2):110-5.
8. Naderan M, Shoar S, Nazari M, Elsayed A, Mahmoodzadeh H, Khorgami Z. A randomized controlled trial comparing laser intra-hemorrhoidal coagulation and Milligan–Morgan hemorrhoidectomy. *J Invest Surg.* 2017;30(5):325-31.
9. Salfi R. A new technique for ambulatory hemorrhoidal treatment. *Coloproctology.* 2009;31(2):99-103.
10. Brusciano L, Gambardella C, Terracciano G, Gualtieri G, Schiano di Visconte M, Tolone S, et al. Postoperative discomfort and pain in the management of hemorrhoidal disease: laser hemorrhoidoplasty, a minimal invasive treatment of symptomatic hemorrhoids. *Update Surg.* 2020;72(3):851-7.
11. Weyand G, Theis CS, Fofana AN, Rüdiger F, Gehrke T. Laser hemorrhoidoplasty with 1470-nm diode laser in the treatment of second to fourth degree hemorrhoidal disease—a cohort study with 497 patients. *Zentralbl Chir.* 2019;144(4): 355-63.
12. Poskus T, Danys D, Makunaite G, Mainelis A, Mikalauskas S, Poskus E, et al. Results of the double-blind randomized controlled trial comparing laser hemorrhoidoplasty with sutured mucopexy and excisional hemorrhoidectomy. *Int J Colorectal Dis.* 2020;35(3):481-90.
13. Giamundo P, De Angelis M, Mereu A. Hemorrhoid laser procedure with suture-pexy (HeLPexx): a novel effective procedure to treat hemorrhoidal disease. *Tech Coloproctol.* 2020;24(2):199-205.
14. Plapler H, Hage R, Duarte J, Lopes N, Masson I, Cazarini C, et al. A new method for hemorrhoid surgery: intrahemorrhoidal diode laser, does it work? *Photomed Laser Surg.* 2009;27(5):819-23.
15. Nagdy m. Comparative study between Milligan Morgan Haemorrhoidectomy and Laser ablation for the Management of third and fourth Degree of hemorrhoids [journal]. *Al-Azhar International Medical Journal.* 2022;3(3):49-58.
16. Esfahani MN, Madani G, Madhkhan S. A novel method of anal fissure laser surgery: a pilot study. *Lasers Med Sci.* 2015;30(6):1711-7.
17. Hussein BG, Azzawi JI, Hussein RA. Diode laser & conventional surgery treatment, A comparative study in anal diseases. *Medico-Legal Update.* 2020;20(1):250-5.
18. Alam AJ. Laser surgery for treatment of haemorrhoid and anal fissure and its outcome. *App Sci.* 2021;5:663-9. Sch J.
19. Mitalas LE, Van Wijk JJ, Gosselink MP, Doornebosch P, Zimmerman DD, Schouten WR. Seton drainage prior to transanal advancement flap repair: useful or not? *Int J Colorectal Dis.* 2010;25(12):1499-502.
20. Sygut A, Mik M, Trzcinski R, Dziki A. How the location of the internal opening of anal fistulas affect the treatment results of primary transsphincteric fistulas. *Langenbecks Arch Surg.* 2010;395(8):1055-9.
21. Wilhelm A. A new technique for sphincter-preserving anal fistula repair using a novel radial emitting laser probe. *Tech Coloproctol.* 2011;15(4):445-9.
22. Doganci S, Demirkilic U. Comparison of 980-nm laser and bare-tip fibre with 1470-nm laser and radial fibre in the treatment of great saphenous vein varicosities: a prospective randomised clinical trial. *Eur J Vasc Endovasc Surg.* 2010;40(2):254-9.
23. Gale SS, Lee JN, Walsh ME, Wojnarowski DL, Comerota AJ. A randomized, controlled trial of endovenous thermal ablation using the 810-nm wavelength laser and the Closure PLUS radiofrequency ablation methods for

- superficial venous insufficiency of the great saphenous vein. *J Vasc Surg.* 2010;52(3):645-50.
24. Öztürk E, Gülcü B. Laser ablation of fistula tract: a sphincter-preserving method for treating fistula-in-ano. *Dis Colon Rectum.* 2014;57(3):360-4.
  25. Giamundo P, Esercizio L, Geraci M, Tibaldi L, Valente M. Fistula-tract Laser Closure (FiLaC™): long-term results and new operative strategies. *Tech Coloproctol.* 2015;19(8):449-53.
  26. Wilhelm A, Fiebig A, Krawczak M. Five years of experience with the FiLaC™ laser for fistula-in-ano management: long-term follow-up from a single institution. *Tech Coloproctol.* 2017;21(4):269-76.
  27. Carvalho ALd, Alves EF, Alcantara RSMd, et al. FILAC-Fistula-Tract Laser Closure: a sphincter-preserving procedure for the treatment of complex anal fistulas. *J Coloproctol.* 2017;37:160-2.
  28. Lauletta A, Falco N, Stocco E, Bellomo R, Infantino A. Anal fistula laser closure: the length of fistula is the Achilles' heel. *Tech Coloproctol.* 2018;22(12):933-9.
  29. Terzi MC, Agalar C, Habip S, Canda AE, Arslan NC, Obuz F. Closing perianal fistulas using a laser: long-term results in 103 patients. *Dis Colon Rectum.* 2018;61(5):599-603.
  30. Gorgun E, Sengun B. Laser fistula surgery [Filac]: when and how? *Semin Colon Rect Surg.* 2019;30(4):104-5..
  31. Marref I, Spindler L, Aubert M, Lemarchand N, Fathallah N, Pommaret E, et al. The optimal indication for FiLaC® is high trans-sphincteric fistula-in-ano: a prospective cohort of 69 consecutive patients. *Tech Coloproctol.* 2019;23(9): 893-7.
  32. Elfeki H, Shalaby M, Emile SH, Sakr A, Mikael M, Lundby L. A systematic review and meta-analysis of the safety and efficacy of fistula laser closure. *Tech Coloproctol.* 2020;24(4): 265-74.
  33. Serin KR, Hacim NA, Karabay O, Terzi MC. Retrospective analysis of primary suturing of the internal orifice of perianal fistula during FiLaC procedure. *Surg Laparosc Endosc Percutan Tech.* 2020;30(3):266-9.
  34. Ahmad A, Kumar A, Sonkar AA, Kumar P, Varma SK. A prospective study of combined sphincter preserving procedure (LIFT+ VAAFT+ FiLAC) in complex anal fistula. *Indian J Surg.* 2022:1-6.
  35. Giamundo P. Laser treatment for anal fistulas: what are the pitfalls?. *Tech Coloproctol.* 2020;24(7): 663-5.
  36. Giamundo P, De Angelis M. Treatment of anal fistula with FiLaC®: results of a 10-year experience with 175 patients. *Tech Coloproctol.* 2021;25(8): 941-8.

© 2022 Talaat et al.; This is an Open Access article distributed under the terms of the Creative Commons Attribution License (<http://creativecommons.org/licenses/by/4.0>), which permits unrestricted use, distribution, and reproduction in any medium, provided the original work is properly cited.

*Peer-review history:*

*The peer review history for this paper can be accessed here:*  
<https://www.sdiarticle5.com/review-history/92712>