



Giant Mixed Vesical Calculus in a Patient in North Central, Nigeria: A Case Report

**Saleh A. Longwap^{1*}, Ahmed M. Rabi², Cecilia N. Edeh³, Daniel O. Aina¹,
Ayuba Affi¹, David M. Manshor⁴, Emmanuel Innocent⁵, Henry Embu⁶,
Mercy Isichei⁷ and Ali I. Shugaba³**

¹Department of Chemical Pathology, University of Jos/Jos University Teaching Hospital, Nigeria.

²Department of Human Physiology, Federal University Lafia, Nigeria.

³Department of Anatomy, University of Jos, Nigeria.

⁴Department of Histopathology, Bingham University Teaching Hospital, Nigeria.

⁵Department of Histopathology, University of Jos/Jos University Teaching Hospital, Nigeria.

⁶Department of Anaesthesia, University of Jos/Jos University Teaching Hospital, Nigeria.

⁷Department of General Surgery, University of Jos/Jos University Teaching Hospital, Nigeria.

Authors' contributions

This work was carried out in collaboration among all authors. All authors read and approved the final manuscript.

Article Information

DOI: 10.9734/JSRR/2021/v27i730416

Editor(s):

(1) Dr. José Alberto Duarte Moller, Universidad de LaSalle Bajío, Mexico.

Reviewers:

(1) Mahesh Rath, Utkal University, India.

(2) Ujwala Shetty, India.

(3) Mehdi Fakour, Iran.

Complete Peer review History: <https://www.sdiarticle4.com/review-history/71587>

Case Report

**Received 20 June 2021
Accepted 26 August 2021
Published 02 September 2021**

ABSTRACT

A 30-year old male Business man presented at the accident and emergency unit of Abnira Medical Centre in Jos city on account of inability to pass urine for over fifteen hours. There was concomitant excruciating lower abdominal pain and swelling that is tender to touch. A positive history of generalized weakness, fatigue, nausea, haematuria was given. However, no fever, vomiting, headache nor history of fainting attacks. On examination, he was afebrile, acyanosed with associated tachycardia (pulse rate 121bpm) and tachypnea (respiratory rate of 27c/min). He was oriented in place, person and time with no focal neurological deficit. There were no cardiac and other respiratory signs picked on examination. His abdomen was soft and non-tender, with normal bowel sounds. However, there was renal angle tenderness. Biochemical investigations done on

presentation showed normal sodium, potassium, chlorite, and bicarbonate. He has some evidence of dehydration and pre-renal azotemia (increased creatinine, urea and uric acid). His liver function tests, lipase, thyroid function test, phosphate, magnesium and albumin-corrected calcium were all normal.

Keywords: Ammonium phosphate (struvite); carbonate apatite; vesical calculus.

1. INTRODUCTION

Giant multiple vesical are rare in modern urological practices. A vesical calculus weighing more than 100g is categorized as a giant urinary bladder stone. Male predisposition for urinary bladder calculi is well known [1].

Vesical calculus may be asymptomatic and discovered as incidental finding. Clinical features include lower abdominal pain, frequent urination, dysuria and blood in urine [2].

The most common causes of urinary bladder stone formation are well known which includes obstruction in the urinary tract that causes fluid stasis, Urinary tract infection (UTI), enlargement of the prostate gland in men, and lodging around foreign body that is present in the bladder. The amount of fluid intake and output and diet also appear to be important factors [3].

Very few number of cases of giant and multiple calculi have been reported in literature. The largest vesical calculus reported in literature is of 6294g [4].

2. CASE PRESENTATION

He was admitted about a year ago for 8 months on account of trauma to certain body parts secondary to Road Traffic Injury (RTI) which led to the traumatic amputation of his left arm. During that admission, there were intermittent generalized body pain, difficulty in micturition associated with frequency, urgency, nausea, flank pain and fever. However, anorexia, vomiting, and weight loss were not present. Suprapubic catheterization was done which helped to relieve urinary symptoms and the catheter was left in-situ for over 6 months. Patient got better and he was extubated prior to discharge.

Weeks later while at home, patient noticed passage of bloody urine associated with intermittent difficulty in micturition which led

patient to return to the hospital and got some investigations done that included complete blood count, electrolytes, liver function tests, magnesium, phosphate, albumin-corrected calcium and HIV I and II screening test and results were all within reference intervals. However, urinalysis indicated cloudiness in urine, pH of 7.5, leukocytes of 3+ and an associated lymphocytosis on complete blood count. An abdominal ultrasonography was unremarkable. A diagnosis of urinary tract infection was made and subsequently treated accordingly.

2.1 Treatment and Clinical Course

The patient was managed acutely with ciprofloxacin p.o 500mg b.d x 10 days and Ibuprofen 400mg b.dp.o x 5 days and discharged home to be seen in 14 days time with the result of Retrograde Urethro Gram (RUG) and Micturating Cysto-Urethrogram (MCUG).

2.2 The Findings on RUG +MCUG

Control Film: A fairly oval calcific foci is seen within the true pelvis suggestive of bladder stone.

Contrast Film: Following retrograde introduction of contrast, the penile and bulbar urethra were demonstrated. The posterior urethra is not demonstrated even on micturating film.

Contrast introduction was with minimal resistance.

Impression: 1. Posterior Urethral Stricture
2. Urinary Bladder stone

Consultant reviewed and patient was prepared for Urethrotomy after counseling and signing of consent form.

Bladder exploration and stone removal revealed Calculus of 5 cm by 3cm and 4.2kg dimension and weight. Analysis of which indicated mixed stones (about 80% Magnesium Ammonium Phosphate 6-hydrate (Struvite) + 20% Ammonium Hydrogenurate.

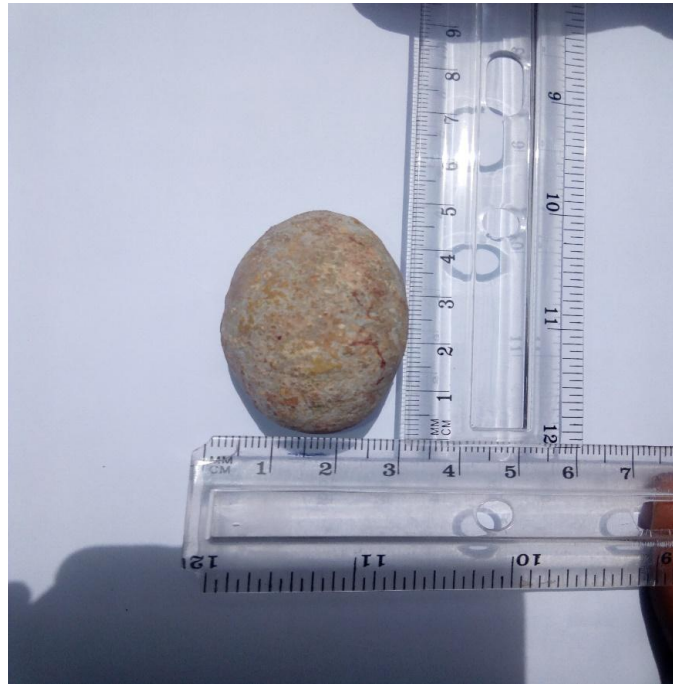


Fig. 1. BladderStone and its dimensions

3. DISCUSSION

Bladder (vesical) calculi are stones or calcified materials that are present in the bladder (or in a bladder substitutes that functions as a urinary reservoir. [1,2,3] They are normally associated with urinary stasis as it was the case of the index patient who was on admission for a long time with supra-pubic cauterization following trauma sustained in a Road Traffic Injury (RTI). This is the major predisposing factor that may have prompted several episodes of postvoid residual urine in the patient and caused stasis which led to crystal nucleation and accretion [4,5]. Bladder stones comprise 5% of urinary tract stones [6]. Generally, they occur in the presence of bladder neck obstruction, urinary tract infections associated with neurogenic bladder and foreign objects as in long standing catheter [6,7]. They are more common among men than women. Infection stones comprise approximately 15% of urinary tract stones. The general clinical setting is re-current urinary tract infections, hematuria and urinary retention which are the case with the index patient [8]. This is supported by a case report of sewing needle as a nidus for a bladder stone in a seven-year-old girl admitted to the hospital with chief complaining burning micturition for 6 months. A bladder stone sized 3.5 cm in length at the pelvic cavity and sewing needle in its center consisting of calcium oxalate monohydrate was removed.

Urinary tract infections and stricture which were documented earlier in the patient perhaps aided the formation of renal stones in him. As several earlier findings corroborated association of urinary tract infections and static urine as the cause of renal calculi, the very picture this patient had while on current admission. This is supported by a case report that revealed a giant bladder stones in a 35 year old male in Iran weight 826g and up to 110cm was removed without any form of obstruction or foreign body just history of recurrent urinary tract infection [9].

Other researchers in other regions of the world reported giant bladder stones which biochemical analysis indicated that they are usually consisting of mostly carbonate apatite and less of struvite. However, ours showed the opposite hence worth reporting. The commonest type of stone usually seen is uric acid stone (seen in over over 50% of cases) [3,5]. Ours revealed Magnesium Ammonium Phosphate Hexahydrate also known as Struvite (80%) +Ammonium Hydrogenurate (20%) which is unusual. A similar finding also in a 30 year old male in India demonstrated two vesical calculi weighing 194 g and 292 g that revealed a biochemical examination findings of 70% Magnesium Ammonium Phosphate Hexahydrate and 30% Carbonate Apatite similar to what we got [10].

5. CONCLUSION

In conclusion, this case report indicated a close relationship between lower abdominal pain, recurrent urinary tract infection and prolonged catheterization. Whenever two or three of these symptoms are presented, a high suspicion of Vesical calculus should be suspected and therefore investigated with radiology and urinalysis. This will assuredly go along way to bare the diagnosis and assist in the course of treatment. Finally, this calculus was apparently massive and first of its kind in this facility.

CONSENT

As per international standard or university standard, patients' written consent has been collected and preserved by the author(s).

ETHICAL APPROVAL

As per international standard or university standard written ethical approval has been collected and preserved by the author(s).

COMPETING INTERESTS

Authors have declared that no competing interests exist.

REFERENCES

1. Becher RM, Tolia BM, Newman HR: Giant vesical calculus. JAMA. 1978a;2272–2273.
2. Nabieu PF, Gevao PP, Songu-M'brewa K, Gegbai IB, Musa M, Swarray AB, et.al. Case Report: A Giant Urinary Bladder Stone in a Female Patient. Sierra Leone J Biomed Res. 2015;7(2):34 – 37.
3. 17+ years of translating research into clinical practice: A Rare Giant Urinary Bladder Stone: A Case Report. Uro Today Int J. 2010;3(3):1944–5784.
4. Aamir Hussain Hela, Mutahir Wani, Haseeb Mohammed Khandwaw, Divya Jyoti. Giant Multiple Vesical Calsuli: A Case Report. Urol Case Rep. 2020;11(33):101264.
5. Whittington JR, Simmons PM, Eltahawy EA, Magann EF. Bladder Stone in Pregnancy:A Case Report and Review of the Litterature. AJ. Case Report. 2018;19:1546-1549.
6. Hammad FT, Kaya M, Kazim E. Bladder Calculi: didthe clinical picture change? Urology. 2006;67(6):1154-1158.
7. Manjunath AS, Hofer MD. Urologic Emergencies. Med. Clin. North America 2018;102(2):373-385
8. Robert Douenas, Mark Rich, Goppal Badlani, David Mazor, Arthur Smith. Predisposing Factors in Bladder Calculi: review of 100 cases. Urology.1991;37(3);240-243. DOI:org/10:1016/0090-4295(91)80293.
9. Hodgkinson A. Composition of urinary tract calculi from some developing countries.Urology international.1979;34(1):26-35.
10. Polat EM, Ozcam L, Otunctemur A, Ozbek E. Giant Bladder Calculi: A Case Report. Urology Association Journal. 2015.12(2):2122-2123.
11. Schwart BJ, Stroller ML. The Vesical Calculus. Urology Clin. Journal Of North America. 2000;27(2):333-346
12. Tahtalı İN, Karataş T. Giant bladder stone: A case report and review of the literature. Turk. J. Urol. 2014;40(3):189-191. DOI:10.5152/tud.2014.02603
13. Palinrungi MA, Syahrir S, Kholis K, Faruk SM. Giant bladder stone formed around sewing-needle in childhood: A case report and literature review, Urology Case Reports. 2020;29(1).
14. Farshi A, Sari Motlagh, Jafari Arismani. Delivery of Huge Bladder Stone in a Thirty-Five-Year-OldMan. Nephro-Urol Mon. 2014;6(6):e20574. DOI:10.5812/numonthly.20574
15. Hela AH, Wani M, Khandwaw HM, Jyoti D. Giant multiple Vesical Calculi: A case report, Urology Case Reports. 2020;33(1).

© 2021 Longwap et al.; This is an Open Access article distributed under the terms of the Creative Commons Attribution License (<http://creativecommons.org/licenses/by/4.0>), which permits unrestricted use, distribution, and reproduction in any medium, provided the original work is properly cited.

Peer-review history:

The peer review history for this paper can be accessed here:
<https://www.sdiarticle4.com/review-history/71587>