

Percutaneous Retrograde Screw Fixation of the Acetabulum: A Case Report

Mohamed Seddik Eddine Akremi ^{a*}, Mehdi Bellil ^a, Majdi Ben Hnia ^a,
Senda Bellila ^a, Walid Balti ^a and Mohamed Ben Salah ^a

^a Department of Orthopaedic Surgery, Charles Nicolle Hospital, Tunis, Tunisia.

Authors' contributions

This work was carried out in collaboration among all authors. All authors read and approved the final manuscript.

Article Information

Open Peer Review History:

This journal follows the Advanced Open Peer Review policy. Identity of the Reviewers, Editor(s) and additional Reviewers, peer review comments, different versions of the manuscript, comments of the editors, etc are available here: <https://www.sdiarticle5.com/review-history/87917>

Case Report

Received 27 March 2022

Accepted 04 June 2022

Published 08 June 2022

ABSTRACT

Introduction: Percutaneous screw fixation techniques for pelvic fractures are mainly described in the management of posterior arch fractures. More recently, improved imaging technology and means for closed reduction have meant that percutaneous techniques have gained popularity in the treatment of acetabular fracture.

The objective of this study is to evaluate the feasibility and interest of percutaneous screw fixation in minimally displaced acetabular fractures.

Observation: We present the case of an 18-year-old female patient with a psychiatric history who was a victim of defenestration.

The radiological exam revealed a fracture of the right sacral ala associated with a minimally displaced T fracture of the left acetabulum. The patient had a percutaneous right sacroiliac screwing and a percutaneous retrograde screw fixation of the left acetabular posterior column. A psychiatric follow-up was carried out. Touch-down weightbearing is allowed for the first three weeks with crutch. The postoperative course was simple. A postoperative CT scan confirmed the correct placement of the screw. Support was allowed after 45 days. No complications were observed at the last 12-month follow-up.

Discussion: Orthopedic treatment of minimally displaced or nondisplaced acetabular fractures provides good radiological results but does not allow early mobilization and rehabilitation and exposes to decubitus complications. Percutaneous retrograde screw fixation is a reliable and reproducible technique that allows rapid ambulation while avoiding the complications of conventional surgery, such as bleeding, vascular and nerve damage, and heterotopic ossifications.

*Corresponding author: Email: seddikakremi@gmail.com;

Conclusion: Percutaneous acetabular screw fixation is a safe and reliable technique for the management of non-displaced and minimally displaced acetabular fractures.

Keywords: Acetabular fracture; percutaneous screwing; case report.

1. INTRODUCTION

Acetabular fractures result from high-energy trauma, frequently associated with severe thoraco-lumbar trauma. This type of fracture raise a problem of therapeutic strategy due to the variety of fracture types. "Many would consider open reduction and internal fixation the benchmark for the treatment of displaced fractures. Due to the bleeding nature of these fractures, the development of minimally invasive techniques has been explored. Initial descriptions of a percutaneous surgical technique was described in the late 2000 as a treatment option for select acetabular fractures" [1].

The objective of this study was to present a case of a minimally displaced T fracture of the acetabulum and highlight the feasibility and interest of percutaneous screw fixation.

2. OBSERVATION

We present the case of an 18-year-old female patient with a psychiatric history who was a victim of a polytrauma due to a height fall. After patient stabilization, the radiological exam revealed a fracture of the right sacral ala without neurological deficit, right obturator foramen fracture associated with a minimally displaced T fracture

of the left acetabulum (Fig. 1). Surgery was performed under general anaesthesia. The patient was placed on supine position with the sacrum elevated on several blankets as a bump. The patient had a percutaneous right sacroiliac screwing and a percutaneous retrograde screw fixation of the left acetabular posterior column. Retrograde posterior column screw was placed directly from the medial half of the ischium with the hip and knee flexed. Antero-posterior and orthogonal iliac and obturator oblique Judet views were used to advance the guidewire, with care taken to avoid medial wall and hip joint penetration (Fig. 2) [2]. The postoperative follow-up was favorable. A postoperative CT scan confirmed the correct placement of the screw and an anatomical restoration of the joint according to the Matta criteria (Fig. 3) [3].

A psychiatric follow-up was carried out. Touch-down weightbearing was allowed for the first three weeks with crutch. Support was allowed after radiological confirmation of bone healing at 60 days (Fig. 4). At the last 12-month follow-up, no complications were observed and the functional results were considered very good according to the quotation of patient-reported outcomes measurement information system (PROMIS Mobility) [4].

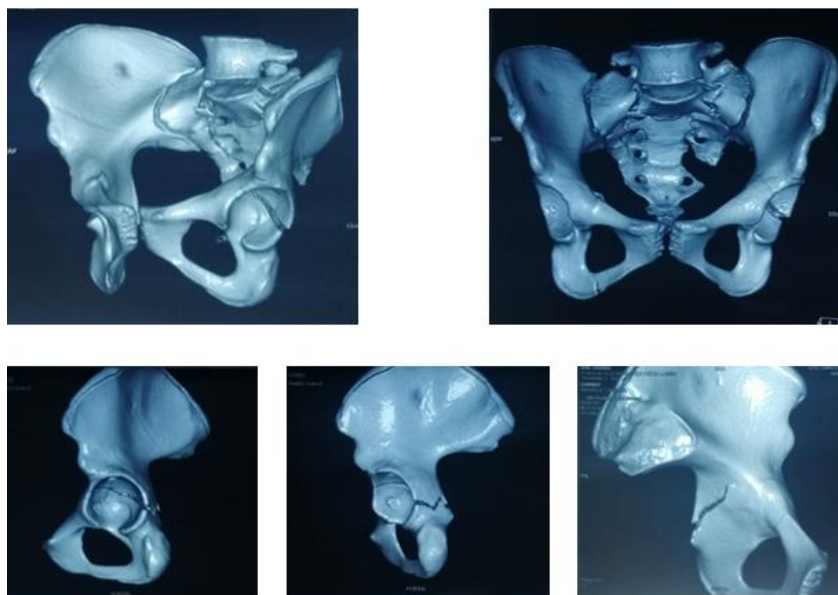


Fig. 1. 3 D scan of the pelvis

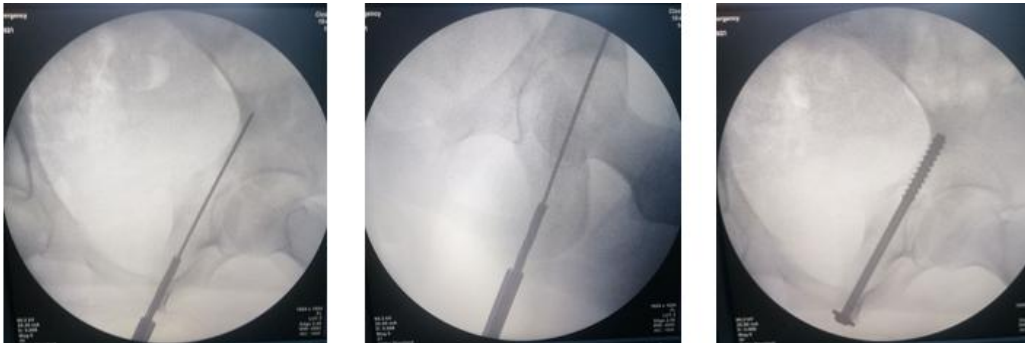

Fig. 2. Retrograde posterior column screw fixation

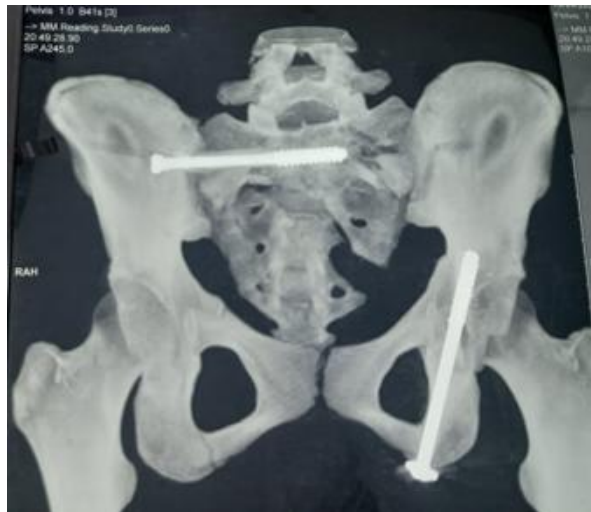

Fig. 3. Postoperative CT scan of the pelvis

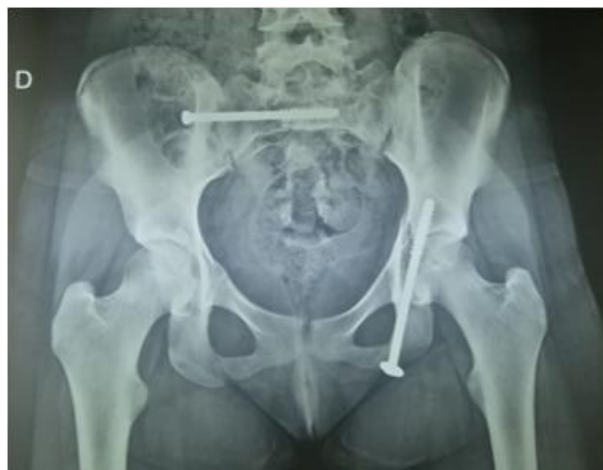

Fig. 4. 45 days post operative X-ray of the pelvis

3. DISCUSSION

Our case study demonstrated the feasibility of retrograde percutaneous screw fixation of the posterior acetabular column in the supine

position. The radiological and functional results in the medium term were considered good. Facing these acetabular fractures, we are faced with a therapeutic challenge. This fracture present a relative low incidence: three

patients/100,000/year [5], which explains the difficulty of gaining experience among young operators. Judet and Letournell classification remains the gold standard for studying fracture features [6]. "When surgical treatment is indicated: There are different means available, namely open reduction with osteosynthesis or percutaneous mini invasive approach. In fractures of the posterior column of acetabulum that are simple and minimally displaced, intramedullary screw fixation is advantageous over plate fixation because of its less invasive nature and lesser soft-tissue insult" [7].

Advancements in percutaneous fixation techniques has led to the broader use of these techniques, particularly as it relates to minimise the potential for complications associated with large surgical wounds.

Surgical planning begins with the evaluation of the intramedullary corridor of the acetabular columns based on CT imaging [8]. "Morphometric variations of this corridor have been described in the literature for its complex structure, which can influence the safe containment of intramedullary screw for fixation of its fractures" [9]. "The surgery can be performed under CT or fluoroscopic control. The antero posterior and obturator view shows the target of the long axis of the ischium, whereas the iliac oblique ensures that the wire is outside of the hip joint and the sciatic notch. If passing the screw retrograde, a true lateral shows the exit point" [10,11]. The postoperative course is usually less severe than in open reductions. This is mainly due to the preservation of the blood supply and the absence of muscle damage. At the same time, it has the advantage of allowing early crutching compared to functional treatment without the risk of secondary displacement.

4. CONCLUSION

Although percutaneous acetabular surgery has a steep learning curve, providing a less-invasive option with rigid columnar fixation can yield earlier mobilization with weight bearing. Operative positioning and preparation as described are essential for successful outcomes using this technique.

CONSENT

As per international standard or university standard, patients' written consent has been collected and preserved by the author(s).

ETHICAL APPROVAL

As per international standard or university standard written ethical approval has been collected and preserved by the author(s).

COMPETING INTERESTS

Authors have declared that no competing interests exist.

REFERENCES

1. Starr AJ, Reinert CM, Jones AL. Percutaneous fixation of the columns of the acetabulum: A new technique. *J Orthop Trauma*. 1998;12:51-58.
2. Connelly CL, Archdeacon MT. Transgluteal posterior column screw stabilization for fractures of the acetabulum: A technical trick. *J Orthop Trauma*. 2012;26:e193-e197.
3. Matta JM, Mehne DK, Roffi R. Fractures of the acetabulum early results of prospective study. *Clin Orthop*. 1986; 205:241-250.
4. Timothy G., Brandon D., Katherine B., Pamela F. Patient-Reported Outcomes Measurement Information System Tools for Collecting Patient-Reported Outcomes in Children With Juvenile Arthritis. *Arthritis Care Res*. 2017 Mar; 69(3): 393-402.
5. Laird A, Keating JF. Acetabular fractures: A 16-year prospective epidemiological study. *J Bone Joint Surg Br*. 2005;87:969-973.
6. Judet R, Judet J, Letournel E. Fractures of the acetabulum. *Acta Orthop Belg*. 1964;30:285-293.
7. Dunet B, Tournier C, Billaud A, Lavoine N, Fabre T, Durandeu A. Acetabular fracture: long-term follow-up and factors associated with secondary implantation of total hip arthroplasty. *Orthop Traumatol Surg Res*. 99(3):281-290.
8. Vivek T, Arvind K, Samarth M, Jigyasa P, Sahil G, Atin K. Morphometric analysis of the anterior column of the acetabulum and safety of intramedullary screw fixation for its fractures in Indian population: A preliminary report. *Int Orthop*. 2020 Apr; 44(4):655-664.
9. Bai Y, Liu Q, Zhongguo X, Fu C, Jian W, Ke Z, et al. Digital study of the ideal position of lag screw internal fixation in the

- anterior column of the acetabulum. 2021 Jun 15;35(6):684-689.
10. Daniel B, Adam JS, Kelly AL. Technical Considerations and Fluoroscopy in Percutaneous Fixation of the Pelvis and Acetabulum. J Am Acad Orthop Surg. 2019 Dec 15;27(24):899-908.
 11. João AM, Murphy P, Flávio R, Maria E, Amanda Do, Jamila Al, et al. The obturator oblique and iliac oblique/outlet views predict most accurately the adequate position of an anterior column acetabular screw. Int Orthop. 2019 May;43(5):1205-1213.

© 2022 Akremit et al.; This is an Open Access article distributed under the terms of the Creative Commons Attribution License (<http://creativecommons.org/licenses/by/4.0>), which permits unrestricted use, distribution, and reproduction in any medium, provided the original work is properly cited.

Peer-review history:

The peer review history for this paper can be accessed here:
<https://www.sdiarticle5.com/review-history/87917>