

Ischiatic Dislocation of the Hip Associated with an Ipsilateral Femoral Shaft Fracture: A Case Report and Literature Review

Z. F. Zengui ^{a*}, O. El Adaoui ^{a,b}, A. Rguibi ^a, Y. El Andaloussi ^{a,b},
A. R. Haddoun ^{a,b}, D. Bennouna ^{a,b} and M. Fadili ^{a,b}

^a Trauma Surgery and Orthopaedics Department, Wing 4, C. H. U. Ibn Rochd, Casablanca, Morocco.

^b Faculty of Medicine and Pharmacy of Casablanca, Hassan II University, Morocco.

Authors' contributions

This work was carried out in collaboration among all authors. All authors read and approved the final manuscript.

Article Information

Open Peer Review History:

This journal follows the Advanced Open Peer Review policy. Identity of the Reviewers, Editor(s) and additional Reviewers, peer review comments, different versions of the manuscript, comments of the editors, etc are available here: <https://www.sdiarticle5.com/review-history/85593>

Case Study

Received 21 January 2022

Accepted 31 March 2022

Published 02 April 2022

ABSTRACT

Introduction: Ischiatic dislocation of the hip associated with an ipsilateral femoral shaft fracture is unusual. It represents a real therapeutic challenge.

Case Report: We report the case of a 26-year-old drug-addicted patient who fell from the 4th floor. This fall resulted in severe polytrauma, with an ischiatic dislocation of the left hip associated with a fracture of the left femoral shaft, besides a displaced open fracture of the left humerus, a fracture of the medial malleolus, a fracture of the calcaneum and a fracture of the sacrum. An emergency reduction of the hip dislocation was performed 3 hours after admission to the operating room by external manoeuvres of the hip dislocation. Osteosynthesis of other lesions was performed 24 hours after the patient's hemodynamic and respiratory stability with the anterograde femoral nail. Early mobilisation of the limb joints without full weight bearing for up to 2 months. The patient returned to his professional activity pre-injury after 4 months.

At a 2-year follow-up postoperatively. The patient considered the evolution satisfactory. X-rays noted good consolidation of the fractures. There was no evidence of avascular necrosis on radiographs after 2 years.

Conclusion: The combined injury of a femoral shaft fracture with a homolateral ischiatic dislocation of the hip is extremely rare. The emergency in an unstable patient with femoral head dislocation is the reduction of the femoral head to minimise the risk of avascular necrosis in the young adult.

Keywords: Ischiatic hip dislocation; shaft femoral; ipsilateral; closed reduction.

1. INTRODUCTION

Hip dislocation is an orthopaedic emergency and its treatment is challenging if associated with other lesions involving the vital prognosis of the patient. It's usually with fractures of the acetabulum wall, the femoral head or neck and rarely the femoral shaft [1-4]. The combination of an ischiatic dislocation of the hip associated with an ipsilateral fracture of the femoral shaft is an unusual clinical entity. Closed reduction of the hip is often impossible or leads to secondary complications such as fractures of the femoral head or neck, or of the posterior acetabulum wall. A surgical approach may be necessary to reduce it [5-9]. We report the clinical case of a 26-year-old patient with ischiatic dislocation of the left hip with homolateral fracture of the proximal third of the femoral diaphysis following a fall from the 4th floor. Our work aimed to present the closed focus management of this entity and to evaluate the functional results at 2 years of follow-up.

2. CASE REPORT

A 26-year-old patient, a drug addict, reported a fall from the 4th floor. This fall resulted in severe polytrauma with impact to the left hip, left femur, ankles, right and left foot, open humerus trauma with cranial impact. He was initially attended by the emergency services, and on initial assessment, the patient was conscious with a

GCS of 14/15, haemodynamically and respiratory stable. The management consisted of placing a peripheral venous line with filling, and a cervical collar then the patient was transferred to the Trauma Surgery and Orthopaedic Department of the Ibn Rochd University Hospital of Casablanca for management.

On arrival at the emergency department, the clinical exam showed an agitated, conscious patient with a GCS of 13/15, Blood Pressure 100/60 mmHg, MAP 60 mmHg, RF 20 cycles/min, and SpO₂ 95% on room air. A frontal head wound left lower limb deformity with adduction, external rotation of the limb and shortening of 4 cm with hip flexion and significant oedema of the left hip (Fig. 1).

Multiple ecchymoses on the left hip, with no vascular or nervous disorders downstream. The oedema of both ankles with retro-malleolar ecchymoses. A traumatic attitude of the left upper limbs with pain and functional impotence, and a posterior angulation deformity of the left arm with a superficial wound on the external face of the left arm with no vascular-nervous deficit. The treatment had been readjusted with macromolecular vascular filling, antibiotic prophylaxis based on amoxicillin and clavulanic acid 1 g/125 mg every 8 h, analgesics based on paracetamol 1 g every 6 hours, Nefopam 20 mg every 4 h, and omeprazole 20 mg per day, oxygen therapy 6 l/min.

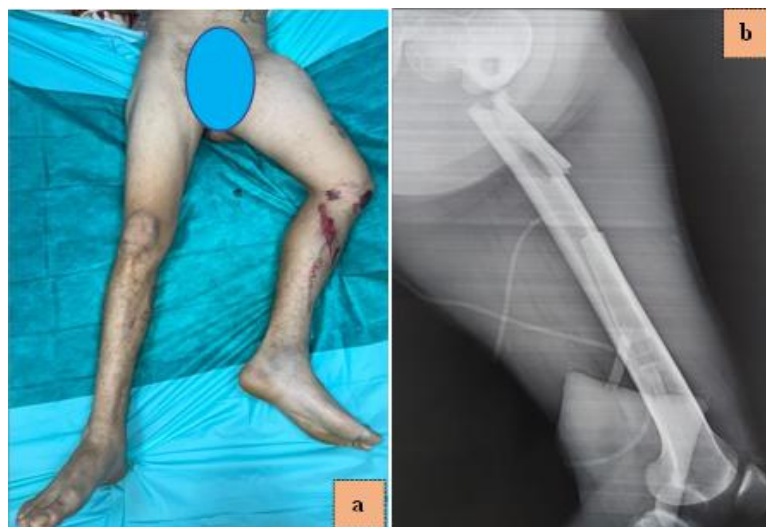

Fig. 1. a: Vicious attitude of the left lower limb with ecchymosis of the front of the knee, shortening of the limb. **b:** lateral view of the left femur showed the complex femoral shaft fracture with rotation of the proximal parts

The paraclinical investigation was carried out after the patient had been stable. X-rays of the pelvis left hip and femur from the front and lateral view showed an ischiatic dislocation of the left hip associated with a complex ipsilateral fracture of the proximal one-third of the left femoral shaft (Fig. 2). The rest of the exam showed a fracture of the left medial malleolus, a right calcaneal fracture, a left open humerus shaft fracture, and a fracture of the sacral aileron.

The Body CT noted no lesions of the brain parenchyma and subcutaneous emphysema of the frontal soft tissues; rectitude of the cervical spine; a bilateral pneumothorax of small volume. There was also a fracture of the anterior margin of the 2nd lumbar vertebra and a complex fracture of the 3rd lumbar vertebra without compression or posterior wall recession. It confirmed the articular nature of the calcaneal fracture with damage to the thalamic surface, the comminuted fracture of the two transforaminal sacral fins with a displaced right ischiopubic branch fracture, and an ischiatic dislocation of the left hip without damages in the femoral head and acetabulum (Fig. 2).

An emergency reduction was performed 3 h after admission to the operating room by external manoeuvres of the hip dislocation. The

manoeuvre consisted of traction in the axis and locating the femoral head in the gluteal region, then applying pressure on it, which was pushed forward with a sensation of jerks confirming the reintegration of the femoral head under fluoroscopic control. The control X-ray of the pelvis confirmed the reduction of the femoral head, and the control CT scan of the pelvis noted good head/cotyle congruence and no damage to the femoral head or any intraarticular fragments (Fig. 3). The patient was operated on at 24 h after the trauma and haemodynamic stabilisation, under general anaesthesia. Internal osteosynthesis was performed by femur intramedullary nailing with static bipolar locking (Fig. 4). A DCP thin plate osteosynthesis of the humerus, a medial malleolus screw fixation and screw fixation with the pinning of the calcaneum. Intraoperative hip testing after femoral nailing showed a stable hip joint in flexion, adduction, external and internal rotation. Functional treatment was undertaken for lumbar and sacrum fractures and the reduced left hip. It consisted of rest on an anti-scarred mattress, post-operative antibiotic prophylaxis with cefazolin for 48 h, analgesics and antithrombotic prophylaxis. Early mobilisation of the limb joints without full weight bearing for up to 2 months. The patient returned to his professional activity pre-injury after 4 months.

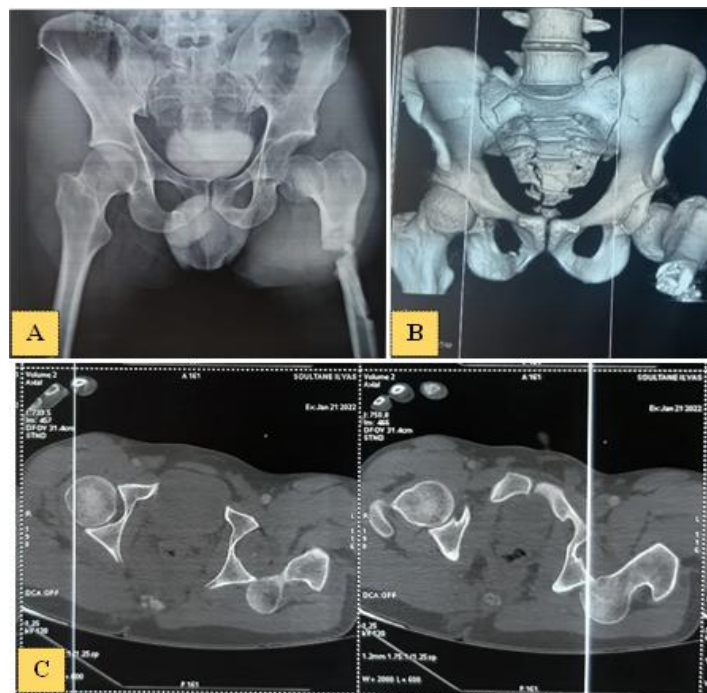

Fig. 2. A: Frontal X-ray of the pelvis showing ischiatic dislocation of the left hip with fracture of the proximal third of the left femoral head. B, C: CT scan 3D reveals dislocation of the left hip without fracture of the femoral head and non-displaced fracture of the sacral ailerons

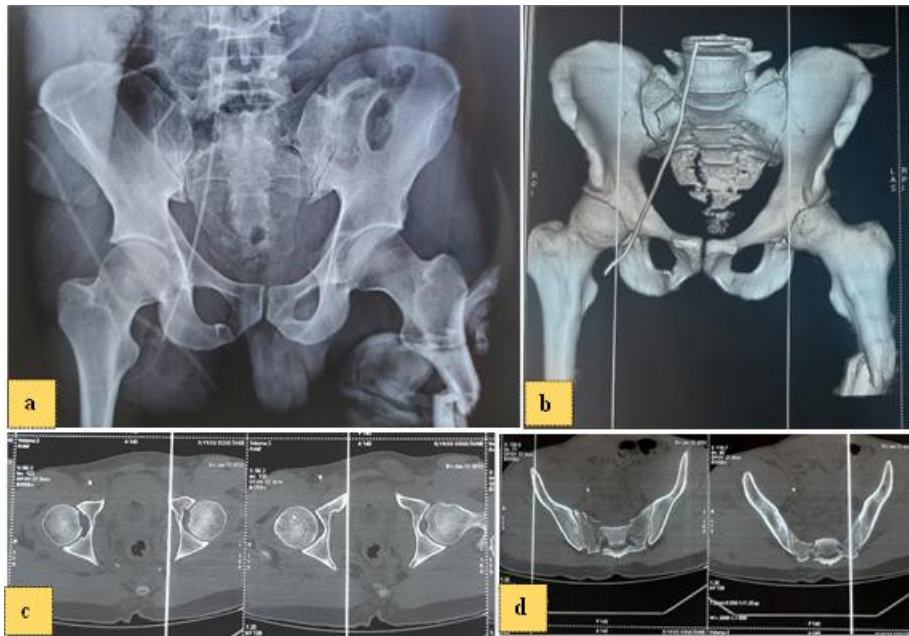


Fig. 3: a. Control AP X-ray of the pelvis showing reduction of the hip joint and fracture of the proximal third of the left femoral. b, c and d. Control pelvis CT scan showing reduction of the hip joint without significant fracture. Fracture of the sacral fins not displaced

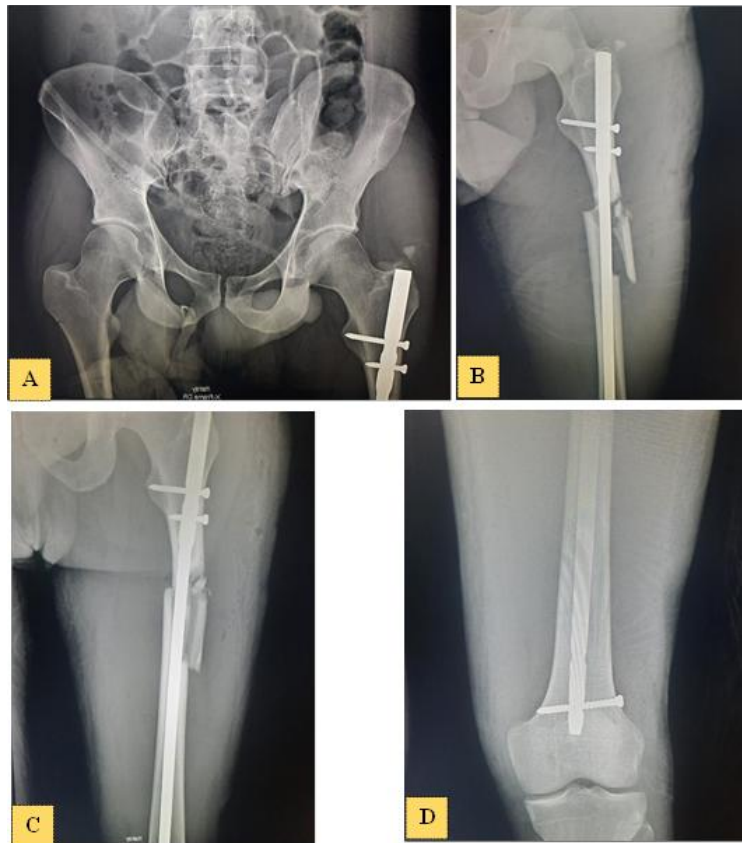


Fig. 4. A, B, C, and D: control X-rays of the pelvis face and left femur at J1 and 1 month postoperatively showing a locked femoral nail

At a 2-year follow-up postoperatively. The patient considered the evolution satisfactory. X-rays noted good consolidation of the femoral, humeral, medial malleolus and calcaneum fracture sites. There was no evidence of avascular necrosis on X-rays after 2 years. But we noted an intermittent pain in the left hip with quadriceps amyotrophy.

3. DISCUSSION

Posterior hip dislocation is a serious injury, the incidence of which is increasing due to high-energy trauma, including falling and road traffic accidents. Fractures commonly associated with the posterior hip dislocation are fractures of the head, neck, shaft or posterior acetabular wall [6,10,11]. The ischiatic dislocation of the hip associated with a fracture of the ipsilateral femoral shaft has been rarely reported. However, it has often been described with the anterior or inferior dislocation of the hip. This injury is also frequently associated with severe multisystem damage, which contraindicates early major surgery on the hip and associated injuries. This is due to the different force mechanisms involved in causing these injuries, although they both accompany high-energy trauma in a young victim. A contusion or laceration over the knee joint or an adducted femur should alert the orthopaedic surgeon to the possibility of hip dislocation [10].

The first problem concerns the initial management of the dislocation. Generally, all traumatic dislocations of the hip must be treated as surgical emergencies. In principle, a hip dislocation should be reduced as soon as possible to not compromise the prognosis of the femoral head. The early reduction in less than 6 h increased the highest incidence of good results in hips. Closed reduction should be performed before considering a surgical approach [10,13]. Which remains necessary in case of irreducibility due to fragmentary incarceration or associated femoral neck or head fractures. Multiple attempts at closed reduction are contraindicated [14]. In our case, we performed the first reduction of the hip dislocation in order not to compromise the prognosis of the femoral head in the long term. The fixation of the other lesions was performed after stabilisation of the patient. The reduction was obtained at the second attempt of the manoeuvre. In the case of irreducibility, the authors report in the literature the use of the Steinmann pin placed at the level of the greater trochanter and serving as a lever. In extreme

cases or associated fractures of the head, femoral neck or posterior wall of the acetabulum, a surgical approach is necessary [7,11,15,16].

The second problem concerns the post-operative management of these injuries which remains challenging, especially in severe polytrauma patients. Which can delay rehabilitation and return to work. Patients should always be informed of the risk of avascular necrosis and osteoarthritis of the hip in the long term. The optimal treatment approach for these complex lesions is currently undetermined. Good pre-surgical scheduling will reduce the risk of long-term injury.

4. CONCLUSION

The combined injury of a femoral shaft fracture with a homolateral ischiatic dislocation of the hip is extremely rare. There is general agreement that the prognosis for the hip relates directly to the promptness of reduction. Closed reduction remains difficult to achieve with the risk of aggravating the injuries, but remain possible as in our case where it was performed by simple external manoeuvre, and stabilisation of the associated lesions managed once the conditions are available.

CONSENT

As per international standard or university standard, patient's written consent has been collected and preserved by the author(s).

ETHICAL APPROVAL

As per international standard or university standard written ethical approval has been collected and preserved by the author(s).

COMPETING INTERESTS

Authors have declared that no competing interests exist.

REFERENCES

1. Ch'en H. Treatment of concomitant fractures of the shaft of the femur and of ipsilateral fracture of the hip. *Zhonghua Wai Ke Za Zhi*. Nov 1959;7:1112-3.
2. Droll KP, Broekhuysen H, O'Brien P. Fracture of the femoral head. *JAAOS- Journal of the American Academy of Orthopaedic Surgeons*. 2007;15(12):716-27.

3. Harper MC. Traumatic dislocation of the hip with ipsilateral femoral shaft fracture: a method of treatment. *Injury*. 1982;13(5):391-4.
4. McClelland SJ, Bauman PA, Medley CF, Shelton ML. Obturator hip dislocation with ipsilateral fractures of the femoral head and femoral neck. A case report. *Clin Orthop*. nov. 1987;224:164-8.
5. Slater RN, Allen PR. Traumatic hip dislocation with ipsilateral femoral shaft fracture in a child: an « open and closed » case. *Injury*. 1992;23(1):60-1.
6. Sharma G, Chadha M, Pankaj A. Hip dislocation associated with ipsilateral femoral neck and shaft fractures: An unusual combination and dilemma regarding head preservation. *Acta Orthop Traumatol Turc*. 2014;48(6):698-702.
7. Rana R, Patra SK, Khuntia S, Jain M, Patro BP. Traumatic Posterior Dislocation of Hip with Ipsilateral Fracture of Shaft of Femur: Temporary Fixator-assisted Reduction and Final Fixation with Interlocking Nail. *Cureus*. 26 août 2019;11(8):e5488.
8. Duygulu F, Calis M, Argun M, Guney A. Unusual combination of femoral head dislocation associated acetabular fracture with ipsilateral neck and shaft fractures: A case report. *J Trauma*. déc 2006;61(6):1545-8.
9. Bennett FS, Zinar DM, Kilgus DJ. Ipsilateral hip and femoral shaft fractures. *Clin Orthop*. 1993;(296):168-77.
10. Chouhan D, Behera P, Ansari MT, Digge VK. Posterior hip dislocation associated with concomitant ipsilateral femoral head and shaft fractures: an unusual combination of injuries. *BMJ Case Rep*. 26 août 2021;14(8):e244453.
11. Ul Haq R, Kumar J, Dhammi IK, Jain AK. Posterior dislocation of hip with ipsilateral intertrochanteric fracture: A report of two cases. *Indian J Orthop*. sept 2016;50(5):571-6.
12. Epstein HC, Wiss DA, Cozen L. Posterior Fracture Dislocation of the Hip with Fractures of the Femoral Head: *Clin Orthop*. déc 1985;201 (NA):9-17.
13. Barquet A. Traumatic hip dislocation with fracture of the ipsilateral femoral shaft in childhood. Report of a case and review of the literature. *Arch Orthop Trauma Surg Arch Orthopadische Unf-Chir*. 1981;98(1):69-72.
14. Gupta A, Barod S. Femoral head fracture without dislocation of hip in a young adult: A case report. *J Orthop Case Rep*. 2020;10(2):58-61.
15. Alhammoud A, Alnouri M, Arbash MA, Baco AM. Posterior hip dislocation with ipsilateral femoral head and shaft fracture - using a temporary external fixator as a method for closed reduction. *J Orthop Case Rep*. déc 2016;6(5):44-6.
16. Verdonk R, de Smet L. Hip dislocation combined with femoral shaft fracture. Two cases treated with the Lardennois hoop. *Acta Orthop Scand*. avr 1984;55(2):185-6.

© 2022 Zengui et al.; This is an Open Access article distributed under the terms of the Creative Commons Attribution License (<http://creativecommons.org/licenses/by/4.0>), which permits unrestricted use, distribution, and reproduction in any medium, provided the original work is properly cited.

Peer-review history:

The peer review history for this paper can be accessed here:
<https://www.sdiarticle5.com/review-history/85593>