

Laryngeal Tumours in University of Port Harcourt Teaching Hospital: A 9 Years Retrospective Study

U. A. Oparaodu ^{a*}, N. S. Uyanwane ^b, E. N. Oghenekaro ^b and L. O. Onotai ^b

^a Department of Surgery, College of Medical Sciences, Rivers State University, Nkpolu, Rivers State, Nigeria.

^b Department of Ear, Nose and Throat Surgery, University of Port Harcourt Teaching Hospital, Port Harcourt Rivers State, Nigeria.

Authors' contributions

This work was carried out in collaboration among all authors. All authors read and approved the final manuscript.

Article Information

Open Peer Review History:

This journal follows the Advanced Open Peer Review policy. Identity of the Reviewers, Editor(s) and additional Reviewers, peer review comments, different versions of the manuscript, comments of the editors, etc are available here: <https://www.sdiarticle5.com/review-history/86098>

Received 09 February 2022
Accepted 19 April 2022
Published 22 April 2022

Original Research Article

ABSTRACT

Background: Tumors of the larynx can be benign or malignant and affect both males and female. The presence of a lesion in the larynx can be detected early. However, most patients present late with the hope the symptoms are as a result of an upper respiratory tract infection which will clear in due time. The late presentation of patients results in more challenges in their management.

Aim: The aim of this study is to review the pattern of laryngeal tumors seen in the University of Port Harcourt Teaching Hospital

Method: This is a 9 years retrospective review of medical records from July 2009 to August 2018 who were managed for laryngeal tumors in the Ear, Nose and Throat Department of University of Port-Harcourt Teaching Hospital. Information retrieved includes biodata, occupation, exposure to tobacco and alcohol, presenting complaints, management and histological findings. Data was analyzed using statistical products and service solutions (SPSS) version 20.

Results: There were 25 patients reviewed during this time accounting for 18 males (72%) and 7 females (28%). The age ranged between 29 to 52 years. The most common presenting symptom was hoarseness, followed by difficulty in breathing then dysphagia. All the patients under review had tracheostomy done for relieve of upper airway obstruction. A direct laryngoscopy and biopsy was done. Histologic variants derived include; 16 cases of squamous cell carcinoma (64%), 6 cases of adenocystic carcinoma (24%) and 3 cases of papilloma (12%) . Two cases of laryngeal

papilloma were weaned off tracheostomy following excisional biopsy of the lesion and confirmatory histology report. A total of 5 laryngectomies were done, patients with advanced cases were referred to other centers for radiotherapy and chemotherapy while a few declined medical advice and others were lost to follow up.

Conclusion: There are more males than females with laryngeal tumors in this study. Majority of these tumors are malignant. Early presentation will result in better management options and thus there is need for health education.

Keywords: Laryngeal neoplasm; carcinoma; squamous cell; university of port harcourt teaching hospital; tracheostomy; laryngectomy; hoarsness.

1. INTRODUCTION

The larynx is the voice box responsible for voice production and the passage of air during respiration [1]. It is located in the neck between the third to sixth cervical vertebrae. The intrinsic muscles of the larynx cause abduction and adduction of the vocal cords leading to passage of air during respiration and phonation [1].

Laryngeal neoplasm can be benign or malignant. It can affect any of the anatomical regions namely supraglottic, glottic and subglottic. Laryngeal carcinoma is one of the debilitating tumors in the head and neck regions which is seen more in males than females [2]. Globally, the male to female ratio for laryngeal cancer is accepted to be 10:1 despite regional variations [3]. In Spain, where carcinoma of the larynx is common, it accounts for 5.6% of all malignancies [4] and 3.4 % of head and neck Cancers in Ile Iife, Nigeria [5].

The presence of a lesion in the larynx can be detected early. However, most of these patients present late based on the assumption that the change in voice is due to an upper respiratory tract infection which will clear with time. Also, many of these patients are first seen by Family Physicians and Medical Practitioners which may lead to misdiagnosis. They however present for a review by the Ear, Nose and Throat (ENT) surgeons after taking a lot of medications with no avail, or when symptoms have gotten worse with associated respiratory distress. This late presentation results in more challenges in management of the patient which may lead to worsening morbidity and mortality [6].

Early diagnosis and management gives a better outcome [7]. There is currently no appropriate marker for early detection [8]. The pattern of laryngeal cancers depends on the anatomical region affected [9]. Thus the knowledge of clinical presentations of laryngeal tumor is

necessary for the general medical practitioners who usually see these patients before referral to the ENT Surgeons.

There is paucity of information on laryngeal tumor in our environment. Thus, the aim of this study is to review the histologic pattern of laryngeal tumors seen in the University of Port Harcourt Teaching Hospital in Rivers State Nigeria.

2. PATIENTS AND METHODS

This is a 9 years retrospective review of medical records of patients who had a diagnosis of laryngeal tumor during the time of review. The age range of these patients from data collated was between 29-52years who were managed for laryngeal tumors in Ear, Nose and Throat (ENT) Surgery Department of the University of Port Harcourt Teaching Hospital from July 2009 to August 2018. Ethical approval was sought and obtained for the study. Information retrieved includes biodata, presenting complaints, occupation, exposure to tobacco and consumption of alcohol, the management and histological findings. Data was analyzed using statistical products and service solutions (SPSS) version 20.

3. RESULTS

There were 25 patients reviewed within the study period accounting for 18 males (72%) and 7 females (28%) as seen in Fig. 1. The age ranged between 29 to 52years.

3.1 Presentation

The most common symptom presented among the cases reviewed showed hoarseness (100%) in all the patients, this was followed by dyspnea accounting for 80% with a clinical finding of stridor. Some patients had difficulty in swallowing (24%), cough (20%) and 4 noticed anterior neck swelling (16%) as in Fig. 2.

3.2 Social History

24% of the patients took alcohol regularly, 60 % occasionally and 16% never took alcohol. Regarding tobacco use, 16 % of patients were regularly exposed to tobacco, both passively and actively, 52% were casual smokers and 32% never used tobacco products. In terms of occupation, six patients were farmers, five were farmers and five were also teachers. Three patients each were civil servants, traders and industry workers.

3.3 Treatment

All the patients under review had tracheostomy done for relieve of upper airway obstruction. A

direct laryngoscopy and biopsy was done. Two cases of laryngeal papilloma were weaned off tracheostomy following excisional biopsy of the lesion and confirmatory histology report.

A total of 5 laryngectomies were done, patients with advanced cases were referred to other centers for radiotherapy and chemotherapy, a few declined medical advice and others were lost to follow up.

3.4 Histology

Histologic variants derived include; 16 cases of squamous cell carcinoma (64%), 6 cases of adenocystic carcinoma (24%) and 3 cases of papilloma (12%) as shown in Fig. 3.

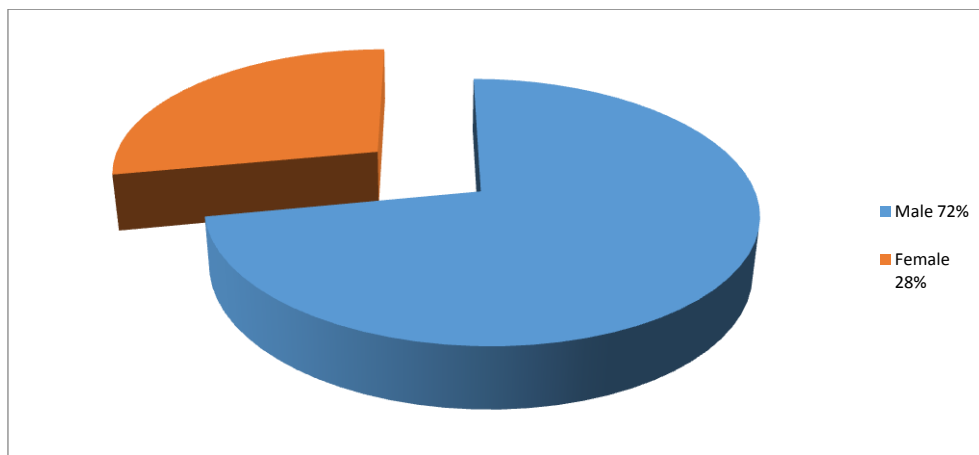


Fig. 1. Pie chart showing sex distribution

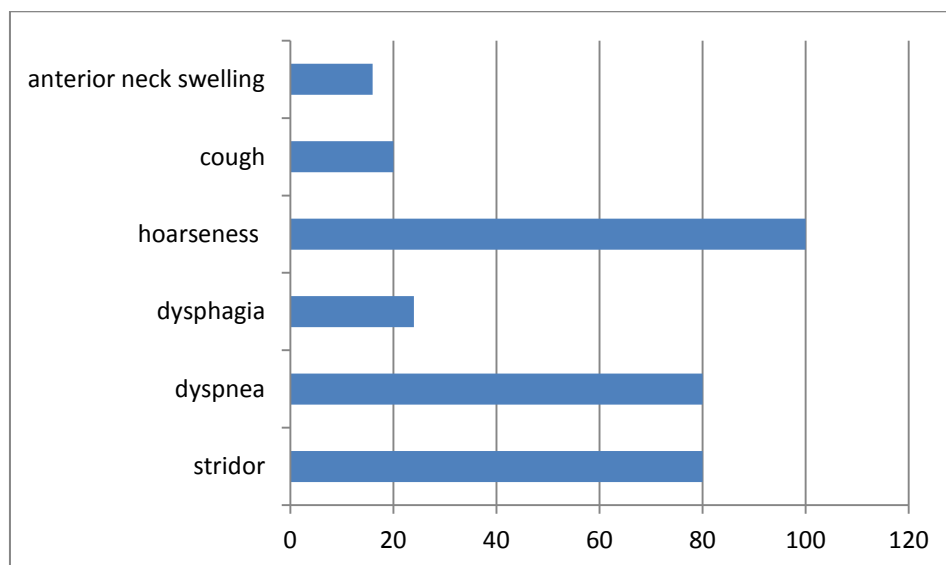


Fig. 2. Graph showing clinical presentation of the patients

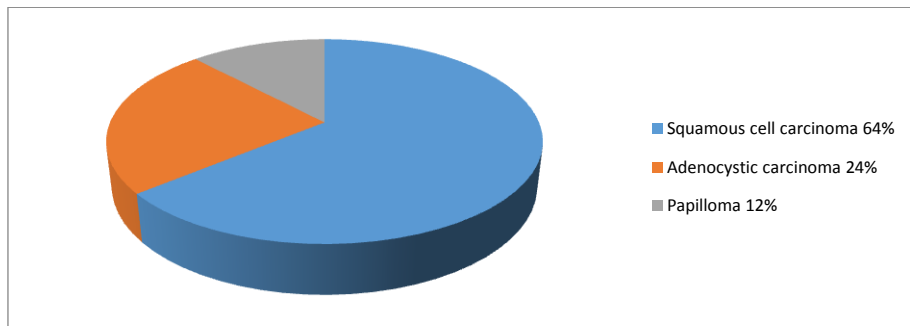


Fig. 3. Pie chart showing the distribution of histologic findings of the laryngeal tumor

4. DISCUSSION

Laryngeal tumor is one of head and neck diseases, which can result in further morbidity and mortality if not managed in time. Majority of laryngeal tumors are malignant as seen in this review and other studies [10]. It affects both male and female, however seen more among the male gender as recorded in this study accounting for 72% of males. This is similar to other studies [5,10,11]. This study records females accounting for 28% of the cases, which is an increase in value compared with previous studies [5,10,11] However, increase in frequency of laryngeal cancer among women has been reported [12].

The age span in this study is from 29 to 52 years of which majority of the cases were seen between the ages of 30 to 49 years. This reflects the age range seen in most cases with laryngeal tumor [13]. This is probably due to the active age for an adult with exposure to various factors such as alcohol and tobacco use as well as exposure to other factors associated with occupation ranging from farming, voice misuse from preaching or teaching, to exposure to chemicals by painting of buildings and chemicals used for hair treatments [14]. This emphasizes that the predisposing factors to laryngeal cancer go beyond exposure to alcohol and tobacco use. Laryngopharyngeal reflux, exposure to asbestos, polycyclic aromatic hydrocarbons, wood dust, coal dust and cement dust were also recognized as risk factors for laryngeal cancer especially in non-smokers [15,16]. Probably, non-smokers (32%) and non-alcoholics (16%) who had laryngeal tumor as seen in this study could have other risk factors.

The most common presentation was hoarseness and dyspnea which was noticed in other studies [17,18] and in some cases upper airway obstruction [10]. The late presentation of these

patients was mainly as a result of misdiagnosis prior to presentation at the Ear, Nose and Throat clinic and based on assumptions by the patients who believed their symptom was due to an upper respiratory tract infection which will clear with time. These patients had tracheostomy done with subsequent examination under anesthesia and biopsy. The histologic findings and stage of the malignant cases gave a guide on the best line of management for the patients. Based on the results retrieved from histology, 2 cases with papilloma were weaned off tracheostomy after excision of all masses seen in the larynx.

Laryngeal Cancer is one of the most common malignancies in the head and neck region [19,20]. In this study, squamous cell carcinoma (64%) accounted for the commonest histologic type which agrees with other studies [10,21,22]. This reflects their origin from squamous cells that form the majority of the laryngeal epithelium. A total of five (5) laryngectomies were done in our patients with advanced cases of laryngeal cancer and were subsequently referred to other centers for radiotherapy and chemotherapy. A few declined medical advice and the others were lost to follow up. Total laryngectomy with post operative radio-therapy offers a good result in patients with advanced laryngeal Carcinoma [23]. Good prognosis has been reported despite late presentation [5].

Tumors of the larynx can be benign or malignant and either of them may present in similar symptoms of hoarseness and or difficulty in breathing.

5. CONCLUSION

Laryngeal neoplasm affects both males and females, with majority of the malignant tumors affecting the males of which Squamous cell carcinoma had the highest occurrence in this

study. In a 9 year period, only 25 cases were reported in the University of Port Harcourt Teaching Hospital (UPTH), of which most patients presented late. Early presentation of patients with laryngeal tumor will result in better management options to reduce morbidity and mortality.

CONSENT

As per international standard or university standard, patients' written consent has been collected and preserved by the author(s).

ETHICAL APPROVAL

As per international standard or university standard written ethical approval has been collected and preserved by the author(s).

COMPETING INTERESTS

Authors have declared that no competing interests exist.

REFERENCES

1. Dhingra PL. Anatomy and Physiology of larynx. In: Disease of the Ear Nose and Throat 7th edn. India: Elsevier; 2009;319-323.
2. Raitola H, Pukander J, Laippala P. Glottic and Supraglottic laryngeal carcinoma: differences in epidemiology, clinical characteristics and prognosis. *Acta Otolaryngol.*1999;119:847-51.
3. Robin PE, Olofsson J. Tumours of the larynx. In: Kerr AG, Hibbert J (Ed). *Scott Brown's Otolaryngology. Laryngology.* Butterworth-Heinemann, Edinburgh.1997;11(7).
4. Zapater E, Campos A, Fortea M, Armeangot M, Basterra J. Prognostic factors in supraglottic laryngeal cancer: a review of 74 cases. *Acta Otorhinolaryngol Esp.* 2000;51:120-8.
5. Amusa YB, Badmus A, Olabanji JK, Oyebamiji EO. Laryngeal carcinoma: Experience in Ile-Ife, Nigeria. *Nigerian J Clin Pract.* 2011;14(1):74-78.
6. Trivedi NP, Swaminathan DK, Thankappan K, Chatni S, Kuriakose MA, Lyer S. Comparison of quality of life in advanced laryngeal cancer patients after concurrent chemoradiotherapy vs total laryngectomy. *Otolaryngol Head and Neck Surg.*2008;139(5):702-7.
7. Mohammed O.M, Ahmad D.F, Chinaka C.C, Mohammed I, Umar A, Abubakar U, et al. Histopathological Patterns of Laryngeal Biopsies in Usmanu Danfodiyo University Teaching Hospital(UDUTH) Sokoto, North-Western Nigeria from 2002-2012. *Journal of Advances in Medicine and Medical Research.*2018;28(9):1-6.
8. Avalos E, Martin A, Porras E, Martinez E, Araujo J, Cordoba J, et al. Biological markers of alcohol abuse in patients with carcinoma of the larynx. *Acta Otorhinolaryngol Esp.*1998;49:465-6.
9. Armstrong WB, Vokes DE, Tijoja T, Verma SP. Malignant tumors of the larynx. In: Flint PW, Francis HW, Haughey BH, editors. *Cummings Otolaryngology Head and Neck Surgery.* 7th ed. Philadelphia: Elsevier Inc; 2021;1564-95.
10. Iseh KR, Abdullahi M, Aliyu D. Laryngeal tumours: clinical pattern in Sokoto, Northwestern Nigeria. *Nigerian Journal of Medicine: Journal of the National Association of Resident Doctors of Nigeria.* 2011;20(1):75-82.
11. Roos M.E, Sherriff A, Riaz S. Laryngeal squamous cell carcinoma at a South Africa referral Hospital. *Egyptian Journal of Ear, Nose, Throat and Allied Sciences.* 2019;2(202):52-59.
12. Lechuga R, Martín C, Mínguez I, Cajade J, Vélez M, Labella T. Study and incidence of carcinoma of the larynx in women. *Acta Otorrinolaringologica Espanola.* 2000;51(2):129-32.
13. Singh B, Alfonso A, Sabin S, Poluri A, Shaha AR, Sundaram K, et al. Outcome differences in younger and older patients with laryngeal cancer: a retrospective case-control study. *American journal of otolaryngology.* 2000;21(2):92-7.
14. Ajayi OF, Adeyemo WL, Ladeinde AL, Ogunlewe MO, Effiom OA, Omitola et al. Primary Malignant neoplasms of orofacial origin: A retrospective review of 256 cases in Nigerian teaching hospital. *Int J Oral Maxillofac Surg.* 2007;36:403-408.
15. Bayer O, Camara R, Zeissig SR, Rensing M, Dietz A, Locati LD et al. Occupation and cancer of the larynx: A systemic review and meta-analysis. *Eur Arch Otorhinolaryngol* 2016;273:9-20.
16. Richiardi L, Corbin M, Marron M, Ahrens W, Pohlmann H, Lagiou P et al. Occupation and risk of upper aerodigestive

- tract cancer: The ARCADE study. *Int J Cancer* 2012;130:2397-406.
17. 17.Koufman JA, Burke AJ. The etiology and pathogenesis of laryngeal carcinoma. *Otolaryngologic Clinics of North America*. 1997;30(1):1-9.
 18. Lilly-Tariah OB, Ukoli CO, Nwana EJ. Cancer of the larynx in black Africans in Jos Nigeria. *The central African Journal of Medicine*. 1999;45(2):40-2.
 19. 19.Siegel RL, Miller KD, Jemal A. Cancer statistics, 2018. *CA: A Cancer Journal for Clinicians*. 2018;68(1):7-30.
 20. Nocini R, Molteni G, Mattiuzzi C, Lippi G. Updates on larynx cancer epidemiology. *Chinese Journal of Cancer Research*. 2020;32(1):18.
 21. 21.Okhakhu AL, Emma-Nzekwue NH. Pattern of persistent hoarseness at the University of Benin Teaching Hospital. *Archives of International Surgery*. 2015;5(2):69-73.
 22. Nwogbo CA, Oghenekaro NE. Surgical review of laryngeal lesions in Port-Harcourt, Nigeria. *Journal of Dental and Medical Sciences*. 2021;20(1):36-39.
 23. Stankiewicz C, Kowalska B, Mikaszewski B, Brzoznowski W. Bilateral neck dissections. *Otolaryngol Pol*. 2000;54:142-4.

© 2022 Oparaodu et al.; This is an Open Access article distributed under the terms of the Creative Commons Attribution License (<http://creativecommons.org/licenses/by/4.0>), which permits unrestricted use, distribution, and reproduction in any medium, provided the original work is properly cited.

Peer-review history:
The peer review history for this paper can be accessed here:
<https://www.sdiarticle5.com/review-history/86098>