

Ocular Manifestations in Thyroid Eye Disorder: A Cross-Sectional Study from Nepal

Palikhe Sabita¹, Thakur Ajit¹, Shah Dev Narayan², Sharma Ananda Kumar², Acharya Niranjana²

¹Drishti Eye Hospital, Birtamode, Nepal

²BP Koirala Institute of Ophthalmic Studies, Institute of Medicine, Tribhuvan University, Kirtipur, Nepal

Email: ajitfriend2002@yahoo.com

How to cite this paper: Sabita, P., Ajit, T., Narayan, S.D., Kumar, S.A. and Niranjana, A. (2016) Ocular Manifestations in Thyroid Eye Disorder: A Cross-Sectional Study from Nepal. *International Journal of Clinical Medicine*, 7, 814-823.

<http://dx.doi.org/10.4236/ijcm.2016.712088>

Received: September 14, 2016

Accepted: December 2, 2016

Published: December 5, 2016

Copyright © 2016 by authors and Scientific Research Publishing Inc.

This work is licensed under the Creative Commons Attribution International License (CC BY 4.0).

<http://creativecommons.org/licenses/by/4.0/>



Open Access

Abstract

Background: Thyroid eye disease represents an organ-specific autoimmune process that is usually associated with thyroid disease. Graves' disease is the most common thyroid abnormality associated with thyroid eye disease. **Aim:** This study was conducted for the profile of ocular manifestation in Thyroid Eye Disease (TED). **Methodology:** A cross-sectional study of 117 cases of thyroid dysfunction was carried out at BP Koirala Institute of Health System, out of which 84 (71.79%) cases had ocular manifestation. They were evaluated and analyzed in detail and the characteristics documented included patient's demography, ocular and systemic history and as well as ocular examination and some of the systemic and laboratory findings. **Results:** In this study, mean age of presentation of TED was 39.7 years. 59 patients were female and 25 were male. The maximum patients of both sexes were in the fourth decade of their lives. The common lid signs were lid retraction and lid lag. Proptosis was seen in 33.3% of cases out of which 68% had bilateral proptosis. Corneal ulcer was seen in 7.1% and optic neuropathy in 1.2% of cases. In 27.3% of cases there was elevation of IOP. Dry eye was seen in 61.9% of cases and POAG seen in 8.3% of cases. In the study population 75% were hyperthyroiditic, 16.7% were hypothyroiditic and 8.3% were in euthyroid state. **Conclusion:** Female was more commonly affected. The maximum number of patients of both sexes was in the fourth decade of their lives. Hyperthyroidism patient had greater chance of ocular manifestation.

Keywords

Thyroid Eye Disease, Ocular Manifestation, Nepal

1. Background

The thyroid gland is an endocrine gland in the body, and consists of two interconnected lobes. It is located at the front of the neck region, below the laryngeal promi-

nence. The thyroid gland secretes thyroid hormones, which influence the metabolic rate, protein synthesis, and have a wide range of other effects, including on development. The thyroid hormones T_3 and T_4 are synthesized from iodine and tyrosine. The thyroid also produces calcitonin, which plays a role in calcium homeostasis [1]. Hormonal output from the thyroid is regulated by thyroid-stimulating hormone (TSH) secreted from the anterior pituitary, which itself is regulated by thyrotropin-releasing hormone (TRH) produced by the hypothalamus [2]. Any structural or functional deficit either in thyroid gland or in their stimulating hormone due to any reason (genetical, environmental etc.) causes thyroid disorder and thus causes its deleterious effect on the body [3]. A cross-sectional multicenter study done in urban population of eight cities in India reported the prevalence of hyperthyroidism to be 10.95% ($n = 5376$) [4]. In Nepal, a retrospective hospital based study done in central region reported the prevalence of thyroid dysfunction to be 29.00% [5].

Thyroid Eye Disease also known as Graves' orbitopathy is typically a self-limiting autoimmune process associated with dysthyroid states. The clinical presentation may vary from very mild disease to severe irreversible sight-threatening complications. It is the most common disease affecting the orbit. It is detectable in approximately 25% of unselected patients with Graves' disease if eyelid signs are excluded, and 40% if eyelid signs are included [6]. It generally presents during 4th and 5th decade of life while it can affect neonates and elderly.

Nepal is a developing country where around 18% people are of age group 40 - 60 [7], and females are more in numbers than males (male to female ratio: 0.96) [8]. Also there is high rate of smokers (25% - 73%) in Nepal [9]. Hence, Nepal is a country with high risk factors but no any study is attempted to know the burden of thyroid ophthalmopathy and the varieties of ocular manifestations due to thyroid disorder. This study is designed to find the rate of ocular manifestation in thyroid disorder in a hospital setting.

2. Methodology

A hospital based cross-sectional study was designed to evaluate the ocular manifestations in patients with thyroid disorder. A sample size was calculated assuming the prevalence of 8%, in 95% of confidence interval with permissible error of 5%. The total sample size calculated was 114. The required sample was collected randomly from outdoor patient department of BP Koirala lions centre for Ophthalmological Studies (BPKLCOS).

The thyroid disorder cases that had sign symptoms mimicking thyroid ophthalmopathy (proptosis, eyelid retraction) due to other causes were excluded. Each patient was informed about the study and only the patients were enrolled if he gave consent for the study. A detailed protocol for data collection was prepared and approved by Institute of Medicine Tribhuvan University Teaching Hospital Institution review board.

Mean was used as a measure of central tendency. Similarly, standard deviation and range were used as a measure of dispersion. Prevalence was calculated in percentage at

95% confidence interval. For risk factor, univariate as well as multivariate analysis were performed and odds ratio was calculated. The level of significance was set at 95%.

3. Data Collection Protocol

After having a verbal consent, a detailed history was taken including the chief visual complaint, history of present illness, medical history, personal and professional history. Visual acuity (unaided, with previous glass and with pinhole) was measured with self illuminated Snellen chart at 6 meter distance at room illumination. Subjective as well as objective refraction were performed for every case and the required glasses were prescribed.

Extra ocular movement and cover test were performed with the help of torch light in all the cardinal gazes and any restriction or over action was noted. Forced duction test was performed in cases with restricted extraocular motility to differentiate restrictive and paralytic. Detail examination of lid was done with the help of torchlight to see if there was any eyelid sign of thyroid ophthalmopathy. The signs that were looked for were Lid retraction (Dalrymple's sign), Lid lag, Enroth's sign (Edema esp. of the upper eyelid), thin tremors when closed eyelid (Rosenbach's sign) [10].

Detail proptosis evaluation was done on for pain, progression, amount and type of proptosis (axial or non axial and measured by Hertel's exophthalmometer), palpation, pulsation and retro pulsation and periorbital changes. Detail examination of conjunctiva, cornea and anterior segment was done with the help of torch light followed by Haag Streit 900 Slit lamp biomicroscopy to find out any abnormalities present. Presence of congestion at the site of insertion of extra ocular muscle, superior limbic keratoconjunctivitis, and any tear film abnormalities were noted. Pupillary light reflex both direct and consensual was noted using bright torch light. Fundus examination was done after pupillary dilatation using eye drop Tropicamide 1% with the help of direct and indirect ophthalmoscope and using + 90 lens in selected cases wherever necessary. IOP was taken with the help of Goldman applanaton tonometer attached to the slit lamp in primary and up gazes.

All patients were sent for thyroid function test if not done. CT scan was ordered in cases of proptosis and with any one of the signs of vision threatening condition (exposure keratopathy, squint or optic nerve involvement). Colour vision was performed in suspected cases of optic neuropathy. In cases of corneal ulcer corneal scraping and culture were done. B scan for orbit was performed in all cases of proptosis.

4. Results

A total of 117 cases, 80 female (68.4%) and 37 male (31.6%), of Thyroid dysfunction were included in this study. The mean age of presentation was 39.7 years that ranged from 17 - 65 years. The majority of the cases (64.1%, n = 75) in their 3rd and 4th decade. The gender distribution with age range is given in **Table 1**.

As shown in **Table 2**, Among 117 cases of thyroid dysfunction 71.7% (n = 84) of cases had some form of ocular manifestations (at least one sign of NOSPECS) and thus

Table 1. Table showing age range and gender distribution of the cases of thyroid.

Age	Sex of patient				Total	
	Male	%	Female	%	Number of cases	%
0 - 10 yrs	0	0	0	0	0	0
11 - 20 yrs	1	2.7	0	0	1	0.9
21 - 30 yrs	7	18.9	18	22.5	25	21.4
31 - 40 yrs	8	21.6	22	27.5	30	25.6
41 - 50 yrs	13	35.13	32	40	45	38.5
51 - 60 yrs	5	13.5	7	8.75	12	10.3
>60 yrs	3	8.1	1	1.25	4	3.4
Total	37	100	80	100	117	100

Table 2. Gender distribution with thyroid eye disease and without thyroid eye disease.

	Male	Female	
With TED	25	59	84
Without TED	12	21	33
	37	80	117

TED: Thyroid Eye Disease

had thyroid eye disease. Odds ratio was calculated for female for being risk of developing thyroid eye disease among thyroid disorder cases. The odds of female to be more affected by TED to male were 1.35.

Ocular manifestations were analyzed with age group in thyroid disorders patients. Out of 117 thyroid eye disease patients, 75 (64.1%) were in 4th and 5th decade as shown in the bar diagram of **Figure 1**. Out of 84 thyroid eye disease cases, 54 (64.28%) cases were thyroid eye disorder. The odds ratio of having thyroid eye disorder in 4th and 5th decade was 1.008.

As shown in **Figure 2**, among the cases with TED (n = 84), 97.6% (n = 82) of cases had FB sensation, 94% (n = 74) of cases had discomfort in the eyes, 73.8% (n = 62) of cases had swelling of eyelids, 54.8% (n = 46) of cases had watering, 50% (n = 42) of cases had redness of eye, 44% (n = 37) of cases had blurring of vision, 38.1% (n = 32) of cases had proptosis, 26.2% (n = 22) of cases had reading problem, and 4.8% (n = 4) of cases had diplopia in the study population with TED.

Among the cases of TED (n = 84), the most common presenting lid sign was lid retraction 67 (79.8%) followed by lid lag 64 (76.2%), infrequent blinking 43 (51.2%), poor convergence 42 (50%), Enroth's sign 28 (33.3%) as shown in **Figure 3**. Proptosis was seen in 28 cases (33.3%), in 19 (22.61%) cases, the proptosis was bilateral and in 9 (10.71%) cases it was unilateral. Bell's phenomenon was poor in 3 (3.6%) and there was restriction in EOM in 10 (11.9%) cases in the study population with TED. Conjunctival sign like chemosis, congestion over the insertion of the rectus muscle were seen in 25 cases (29.8%).

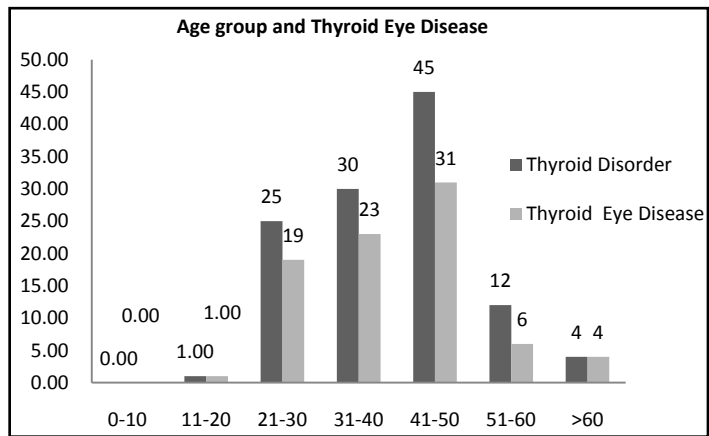


Figure 1. Bar diagram showing the thyroid eye disease distribution among age groups.

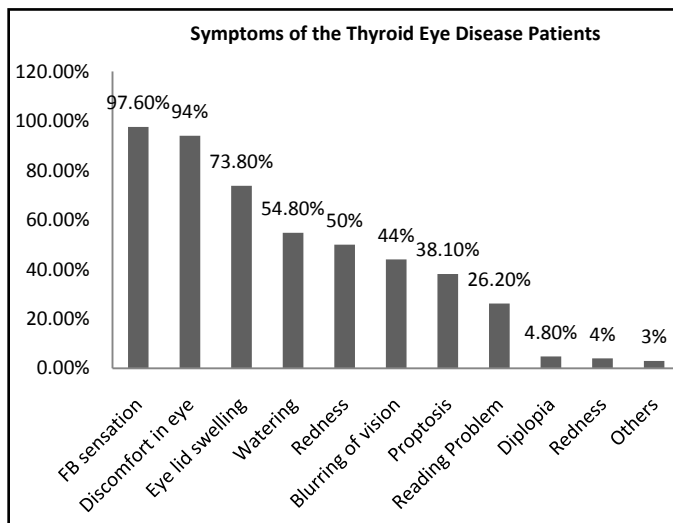


Figure 2. Bar diagram showing the presenting symptoms of Thyroid eye disease patients.

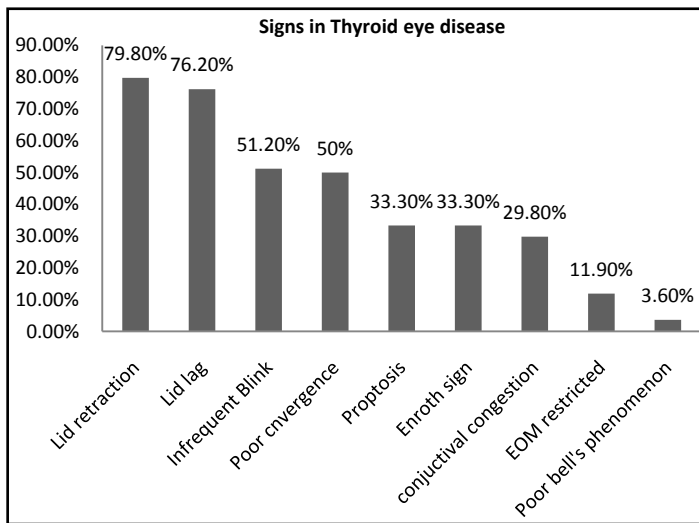


Figure 3. Bar diagram showing the signs of thyroid eye disease observed in patients.

21 (25%) cases had intraocular involvement in which 14 (16.66%) were superior limbic keratoconjunctivitis, 6 (7.14%) cases had corneal ulcer and 1 (1.19%) case was diagnosed as optic neuropathy. Out of 6 cases of corneal ulcer, 4 cases were bilateral and 2 cases were unilateral. Corneal scrapping was done in all the cases and culture positive was seen in 67% (n – 4) of cases. In all the culture positive cases *Staphylococcal aureus* was isolated. Unilateral optic neuropathy seen in 1 case had severe degree of proptosis with bilateral corneal ulcer and visual acuity of no perception of light in that eye with optic neuropathy.

Intraocular pressure was measured in primary and up gaze and any pressure above 22 mm of hg at any of the gaze was recorded as high [11]. Out of 84 cases of thyroid eye disease, 21 (25%) had high IOP while 63 (75%) had normal IOP. All the cases with higher IOP were evaluated for glaucoma with cup-disc ratio evaluation and automated visual field and central corneal thickness evaluation. 7 cases (8.33%) were diagnosed as primary open angle glaucoma and 3 (3.57%) were put as suspect of glaucoma and rest were diagnosed as ocular hypertension.

Schirmer's test and tear break up time were evaluated for diagnosis of tear film disorder. The normal value for schirmer's test was set 10 and for tear break up time it was set 10 sec. [12]. 52 (61.9%) were diagnosed to have tear film disorder. 75% (n – 63) of cases were Hyperthyroiditic, 16.7% (n – 14) of cases were Hypothyroiditic and 8.3% (n-7) of case were having Euthyroid state.

A yes/No questionnaire on the knowledge of their being affected by thyroid eye disease was asked with all the patients. 34 (27.35%) patients were not aware of their thyroid status but presented in eye OPD for various eye problems. But on careful examination we suspected of thyroid eye disease and investigation was sent for it. They all turned out to have thyroid dysfunction and are now under treatment for it.

5. Discussion

Thyroid eye disease is a complex and poorly understood inflammatory disease that causes a wide variety of clinical problems. Clinical management is often frustrating for both the physician and the patient, because no immediate or dramatic cure exists. Each treatment modality has significant side effects and complications, and treatment decisions are rarely easy.

Thyroid disease, being autoimmune disorder mostly, effects mostly in 4th and 5th decade of life and commonly in females as cited by many previous studies [13] [14] [15]. The average age of presentation of the thyroid eye disease was 40 years in our study. This was similar to the result shown by Bartley GB *et al* of median age 43 years [16]. Another study by DeLisa Fair-weather *et al.* in their review quoted that Autoimmune diseases affects 8% of the population, 78% of whom are women. The exact reason for the high prevalence in women is unclear. But it is presumed that the effects of female gonadal hormones (prolactin and estrogen) and X chromosome inactivation on thyroid gland and immune system greatly contribute to the female predilection of thyroid disorder in female. The direct actions of estrogens on the thyroid tissue contribute

to the development of thyroid goitre, nodule and cancer in women [15]. From the literatures; it is evident that female predominant autoimmune diseases that manifest during the acute phase, such as Graves' disease and systemic lupus erythematosus, are diseases with a known antibody-mediated pathology. Autoimmune diseases with an increased incidence in females that appear clinically past age 50 are associated with a chronic, fibrotic Th2-mediated pathology. Th17 responses increase neutrophil inflammation and chronic fibrosis.

The prevalence of thyroid eye disease in thyroid disorder varies greatly as cited by different studies. It was reported as low as 17.3% by Kyung In Woo, *et al.* in Korea [17] and reported as high as 51.7% by Manji N *et al.* In contrast, our study reported the prevalence of any form of thyroid eye disorder in 71.7% (n = 84) cases that is much higher than the previous studies elsewhere. The higher prevalence of thyroid eye disease may be attributed to the definition of thyroid eye disease in our study. We have defined thyroid eye disease as presence of any one sign of thyroid eye disease (NOSPECS) while other studies have taken at least two signs [18]. In a study done in India by Mohsen Bahmani Kashkoui *et al.* [19], the prevalence was 35.6%.

Thyroid eye disease can occur in any form of thyroid dysfunction either hyper, hypo or euthyroid state. In our study, out of 84 thyroid eye disease patients, 63 (75%) were hyperthyroid, 14 (16.7%) were hypothyroid and 7 (8.3%) were euthyroid. A study reported by Bartley GB, Fatourehchi V *et al.* at Mayo Clinic, Rochester USA has cited 90% of hyperthyroid, 6% euthyroid, 1% had primary hyperthyroidism and 3% had Hashimoto's thyroiditis [20]. Many explanations for the occurrence of thyroid ophthalmopathy in hyperthyroid, hypothyroid and euthyroid states are given in literature. One was that hyperthyroidism and hypothyroidism can occur concurrently in one patient, but the time of occurrence might be different, because of the possibility of spontaneous transition. There might be transformation in blocking antibodies into stimulating antibodies with time [21]. It was also hypothesized that different concentrations of blocking and stimulating antibodies attack the thyroid cell simultaneously, which might cause hypothyroidism or hyperthyroidism [22].

Ocular manifestation of thyroid disease includes eyelid retraction, periorbital edema, conjunctival injection and chemosis, proptosis, extraocular muscle restriction, exposure keratopathy, and optic nerve compromise. Sympathetic stimulation of the Müller muscle may be responsible for most of the medically reversible cases of eyelid retraction in patients with Graves disease [23]. Similarly, the periorbital edema, conjunctival injection, proptosis, extraocular muscle restriction all are attributed to the inflammation of intraorbital fat as well as extraocular muscle. The exposure keratopathy is due to severe proptosis and the compressive optic neuropathy is also due to severe proptosis [24].

Our study showed that eyelid retraction was present in 79.8% that was far less than Bartley GB *et al.*'s [20] 90%. The difference might be due to ethnic variation or might be the severity of disease unequal in the study. Another study reported by Saks ND *et al.* reported the lid retraction in 98% of the patients [25]. Similarly, lid lag was present in 76.2% (n = 64) of cases in our study while it was reported 43.33% in Bartley GB *et al.*

study [20].

Exophthalmos is the most widely known sign of thyroid eye disease, occurs in 20% - 30% of patients with Graves' disease and up to 40% - 70% of patients with thyroid associated ophthalmopathy. It is bilateral in 80% - 90% of cases [26]. In our study, Exophthalmos was present in only 33.3% (n = 28) of cases, restrictive extra ocular myopathy was seen in only in 11.95% (n = 10) of cases.

Other severe ocular manifestations of thyroid ophthalmopathy include diplopia, corneal ulcer due to exposure keratopathy and dysthyroid optic neuropathy. Diplopia was noted in 4.8% (n = 4). Corneal involvement was in the form of superior limbic kerato-conjunctivitis (16.7%) and corneal ulcer (7.1%). Decreased vision from optic neuropathy was present in only 1.2% of cases. Bartley *et al.* reported 17% of the patients presenting with diplopia, 10% of cases with corneal involvement and optic neuropathy in 5% to 9% [27]. The presence of this severe degree of eye involvement and blinding conditions in our set up may be due to late presentation and due to unawareness of their disease process at presentation. It may be also due to our centre being tertiary eye centre and we get majority of complicated and referred case.

Thyroid eye disease has been found to be usually associated with glaucoma. The possible cause of increased intraocular pressure and thus causing optic neuropathy might be increased episcleral pressure thus hindering the outflow and increasing intraocular pressure. The other mechanism if increased intraocular pressure might be compression of globe by inflamed and fibrosed inferior rectus muscle. In our study of the total no. of patients with thyroid eye disease 23 patients, which accounted for 27.38% cases had increased IOP. However only 7 cases (8.3%) had POAG and 3 cases were suspected for glaucoma. Cookerham and associates reviewed 500 patients with thyroid eye disease and found 120 (24%) had increased IOP. Of this 2% developed glaucomatous field defect over a follow up of 48 months [28].

Other ocular pathology like dry eyes was seen in 61.9% (n = 52) in thyroid eye disease patients in our study. This may be due to the exposure or it may be due to the immunological process associated with thyroid eye disease. It is cited in literature that five factors potentially associated with corneal exposure-palpebral fissure width, exophthalmos, blink rate, lagophthalmos, and lid lag. All the factors were evaluated in 17 patients with Graves' disease in a study to determine which were associated with ocular surface damage. Multiple regression analysis revealed that increased palpebral fissure width and increased blink rate were both significant predictors of ocular surface damage [29].

6. Conclusion

Thyroid eye disease affects the majority of thyroid disease patients. The ocular manifestation ranges from mildest to the most severe form. Early diagnosis and intervention can be beneficial in saving sight and globe. Hence a proper referral system between ophthalmologists and physician is mandatory. Also, many thyroid disorders are first time diagnosed form ocular manifestations so a regular health check up including eye

check up is needed to pick the cases in early stage and referred among each other for better treatment outcome.

References

- [1] Hall, J. (2011) Guyton and Hall Textbook of Medical Physiology. 12th Edition, Saunders/Elsevier, Philadelphia, 907.
- [2] Boron, W.F. and Boulapep, E.L. (2012) Medical Physiology. 2nd Edition, Saunders, Philadelphia, 1052.
- [3] Tomer, Y. and Huber, A. (2009) The Etiology of Autoimmune Thyroid Disease: A Story of Genes and Environment. *Journal of Autoimmunity*, **32**, 231-239. <https://doi.org/10.1016/j.jaut.2009.02.007>
- [4] Unnikrishnan, A.G., Kalra, S., Sahay, R.K., Bantwal, G., John, M. and Tewari, N. (2013) Prevalence of Hypothyroidism in Adults: An Epidemiological Study in Eight Cities of India. *Indian Journal of Endocrinology and Metabolism*, **17**, 647-652. <https://doi.org/10.4103/2230-8210.113755>
- [5] Mahato, R.V., Jha, B., Singh, K.P., Yadav, B.K., Shah, S.K. and Lamsa, M. (2005) Status of Thyroid Disorders in Central Nepal: A Tertiary Care Hospital Based Study. *International Journal of Applied Sciences and Biotechnology*, **3**, 119-122.
- [6] Maheshwari, R. and Weis, E. (2012) Thyroid Associated Orbitopathy. *Indian Journal of Ophthalmology*, **60**, 87-93. <https://doi.org/10.4103/0301-4738.94048>
- [7] Population Pyramids of the World from 1950 to 2100. <https://populationpyramid.net/nepal/2016/>
- [8] Demographics of Nepal/Sex Ratio 2012. https://en.wikipedia.org/wiki/Demographics_of_Nepal
- [9] Poudel, S. and Gurung, D.K. (2013) Prevalence of Smoking and Perceived Health Problems among Male Population of Dharan Municipality. *Journal of Kathmandu Medical College*, **2**.
- [10] Graves' Ophthalmopathy. From Wikipedia, the Free Encyclopedia. https://en.wikipedia.org/wiki/Graves%27_ophthalmopathy
- [11] Chua, J., Tham, Y.C., Liao, J., Zheng, Y., Aung, T., Wong, T.Y. and Cheng, C.Y. (2014) Ethnic Differences of Intraocular Pressure and Central Corneal Thickness: The Singapore Epidemiology of Eye Diseases Study. *Ophthalmology*, **121**, 2013-2022. <https://doi.org/10.1016/j.ophtha.2014.04.041>
- [12] Savini, G., Prabhawat, P., Kojima, T., Grueterich, M. and Espana, E. (2008) The Challenge of Dry Eye Diagnosis. *Clinical Ophthalmology*, **2**, 31-55. <https://doi.org/10.2147/OPHTH.S1496>
- [13] Morganti, S., Ceda, G.P., Sacconi, M., Milli, B., Ugolotti, D., Prampolini, R., Maggio, M., Valenti, G. and Ceresini, G. (2005) Thyroid Disease in the Elderly: Sex-Related Differences in Clinical Expression. *Journal of Endocrinological Investigation*, **28**, 101-104.
- [14] Vanderpump, M.P.J., et al. (1995) The Incidence of Thyroid Disorders in the Community: A Twenty-Year Follow-Up of the Whickham Survey. *Clinical Endocrinology (Oxford)*, **43**, 55-68. <https://doi.org/10.1111/j.1365-2265.1995.tb01894.x>
- [15] Li, H. and Li, J. (2015) Thyroid Disorders in Women. *Minerva Medica*, **106**, 109-114.
- [16] Bartley, G.B., Fatourechi, V., Kadrmas, E.F., Jacobsen, S.J., Ilstrup, D.M., Garrity, J.A., et al. (1995) The Incidence of Graves' Ophthalmopathy in Olmsted County, Minnesota. *American Journal of Ophthalmology*, **120**, 511-517. [https://doi.org/10.1016/S0002-9394\(14\)72666-2](https://doi.org/10.1016/S0002-9394(14)72666-2)

- [17] Woo, K.I., Kim, Y.-D. and Lee, S.Y. (2013) Prevalence and Risk Factors for Thyroid Eye Disease among Korean Dysthyroid Patients. *Korean Journal of Ophthalmology*, **27**, 397-404. <https://doi.org/10.3341/kjo.2013.27.6.397>
- [18] Manji, N., Carr-Smith, J.D., Boelaert, K., Allahabadia, A., Armitage, M., Chatterjee, V. K., et al. (2006) Influences of Age, Gender, Smoking, and Family History on Autoimmune Thyroid Disease Phenotype. *The Journal of Clinical Endocrinology & Metabolism*, **91**, 4873-4880. <https://doi.org/10.1210/jc.2006-1402>
- [19] Kashkouli, M.B., Kaghazkanani, R., Heidari, I., Ketabi, N., Jam, S., Azarnia, S. and Pakdel, F. (2011) Bilateral versus Unilateral Thyroid Eye Disease. *Indian Journal of Ophthalmology*, **59**, 363-366. <https://doi.org/10.4103/0301-4738.83612>
- [20] Bartley, G.B., Fatourechi, V., Kadrmas, E.F., Jacobsen, S.J., Ilstrup, D.M., Garrity, J.A., et al. (1996) The Chronology of Graves' Ophthalmopathy in an Incidence Cohort. *American Journal of Ophthalmology*, **121**, 426-434. [https://doi.org/10.1016/S0002-9394\(14\)70439-8](https://doi.org/10.1016/S0002-9394(14)70439-8)
- [21] McDermott, M.T., Kidd, G.S., Dodson, L.E. and Hofeldt, F.D. (1986) Case Report: Hyperthyroidism Following Hypothyroidism. *American Journal of the Medical Sciences*, **291**, 194-198. <https://doi.org/10.1097/00000441-198603000-00011>
- [22] Starrenburg, A.J., Cabezas, M., Gan, I.M., Njo, T.L., Rietveld, A.P. and Elte, J.W. (2010) Four Patients with Hypothyroid Graves' Disease. *Netherlands Journal of Medicine*, **68**, 178-180.
- [23] Ohnishi, T., Noguchi, S., Murakami, N., Nakahara, H., Hoshi, H., Jinnouchi, S., Futami, S., Nagamachi, S. and Watanabe, K. (1993) Levator Palpebrae Superioris Muscle: MR Evaluation of Enlargement as a Cause of Upper Eyelid Retraction in Graves Disease. *Radiology*, **188**, 115-118. <https://doi.org/10.1148/radiology.188.1.8511284>
- [24] Mourits, M.P., Koornneef, L., Wiersinga, W.M., Prummel, M.F., Berghout, A. and van der Gaag, R. (1989) Clinical Criteria for the Assessment of Disease Activity in Graves' Ophthalmopathy: A Novel Approach. *British Journal of Ophthalmology*, **73**, 639-644. <https://doi.org/10.1136/bjo.73.8.639>
- [25] Saks, N.D., Burnstine, M.A. and Putterman, A.M. (2001) Glabellar Rhytids in Thyroid-Associated Orbitopathy. *Ophthalmic Plastic & Reconstructive Surgery*, **17**, 91-95. <https://doi.org/10.1097/00002341-200103000-00003>
- [26] Asman, P. (2003) Ophthalmological Evaluation in Thyroid-Associated Ophthalmopathy. *Acta Ophthalmologica Scandinavica*, **81**, 437-448.
- [27] King, J.S. and Netland, P.A. (2002) Glaucoma in Thyroid Eye Disease. In: Dutton, J.J. and Haik, B.G., Eds., *Thyroid Eye Disease: Diagnosis and Treatment*, CRC Press, Boca Raton, 319-325. <https://doi.org/10.3109/9780203908983-33>
- [28] Cockerham, K.P., Pal, C., Jani, B., Wolter, A. and Kennerdell, J.S. (1997) The Prevalence and Implications of Ocular Hypertension and Glaucoma in Thyroid-Associated Orbitopathy. *Ophthalmology*, **104**, 914-917. [https://doi.org/10.1016/S0161-6420\(97\)30207-3](https://doi.org/10.1016/S0161-6420(97)30207-3)
- [29] Gilbard, J.P. and Farris, R.L. (1983) Ocular Surface Drying and Tear Film Osmolarity in Thyroid Eye Disease. *Acta Ophthalmologica*, **61**, 108-116. <https://doi.org/10.1111/j.1755-3768.1983.tb01401.x>



Submit or recommend next manuscript to SCIRP and we will provide best service for you:

Accepting pre-submission inquiries through Email, Facebook, LinkedIn, Twitter, etc.

A wide selection of journals (inclusive of 9 subjects, more than 200 journals)

Providing 24-hour high-quality service

User-friendly online submission system

Fair and swift peer-review system

Efficient typesetting and proofreading procedure

Display of the result of downloads and visits, as well as the number of cited articles

Maximum dissemination of your research work

Submit your manuscript at: <http://papersubmission.scirp.org/>

Or contact ijcm@scirp.org