

A Case Report on PRES and HELLP Syndrome in 08 Months Amonehrric Women

Priyancy Patel ^{a*}, Khushi Thakor ^a, Monil Dabgar ^a and Snigdha Das Mandal ^{b++}

^a *Department of Pharmacy Practice, Parul Institute of Pharmacy & Research, Parul University, Vadodara, Gujarat, India.*

^b *Department of Pharmacy Practice, Pharmacology, Parul Institute of Pharmacy & Research, Parul University, Vadodara, Gujarat, India.*

Authors' contributions

This work was carried out in collaboration among all authors. All authors read and approved the final manuscript.

Article Information

Open Peer Review History:

This journal follows the Advanced Open Peer Review policy. Identity of the Reviewers, Editor(s) and additional Reviewers, peer review comments, different versions of the manuscript, comments of the editors, etc are available here: <https://www.sdiarticle5.com/review-history/94684>

Case Study

Received 14 October 2022
Accepted 17 December 2022
Published 22 December 2022

ABSTRACT

Posterior Reversible Encephalopathy Syndrome (PRES), in 1996 was originally described by Hinchey. It is also so-called as reversible posterior leukoencephalopathy syndrome, an illness in which a person present's with acutely altered mentation, visual impairment, drowsiness or sometimes stupor, seizures (focal or general tonic-clonic), and sudden or constant, non-localized headaches, and nausea and vomiting. If recognized promptly and treated, the clinical syndrome generally resolves within a week, and the variations seen in magnetic resonance imaging (MRI) resolve over days to weeks. The syndrome of hemolysis, elevated liver enzymes, and low platelets, is referred to as HELLP syndrome, has historically been classified as a complication or progression of severe preeclampsia. An ischemic-reperfusion injury initiates the liver damage in HELLP syndrome. The clinical presentation may vary from patient to patient with HELLP syndrome, and may present with colicky mid-epigastric and/or right upper quadrant pain associated with fatigue, nausea and vomiting. An appropriate physical examination must be conducted if any of the above complications are suspected.

⁺⁺ *Head of the Department;*

^{*}*Corresponding author: E-mail: priyancypatel18@gmail.com;*

Keywords: *Posterior reversible encephalopathy syndrome (PRES); hemolysis, elevated liver enzymes and low platelets (HELLP).*

1. INTRODUCTION

Posterior Reversible Encephalopathy Syndrome (PRES), in 1996 was originally described by Hinchey [1]. "It is also so-called as reversible posterior leukoencephalopathy syndrome, an illness in which a person presents with acutely altered mentation, visual impairment, drowsiness or sometimes stupor, seizures (focal or general tonic-clonic), and sudden or constant, non-localized headaches, and nausea and vomiting". [2,3]. "The risk factors for emerging PRES include hypertension, pregnancy and puerperal diseases, organ transplantation, immunosuppressive agents or cytotoxic agents, acute or chronic kidney disease, autoimmune diseases, infections, endocrine diseases, etc" [4-6]. "On neuroimaging, it is characterized by vasogenic edema involving the cortical/subcortical regions which is bilateral affecting the parietal and occipital regions, followed in frequency by involvement of other regions" [7-10]. "If promptly recognized and treated, the clinical syndrome usually resolves within a week [2,3], and the changes seen in magnetic resonance imaging (MRI) resolve over days to weeks" [11-13].

"HELLP syndrome is a life-threatening condition with the mortality rate of around 0%-24%, and perinatal death rate of up to 37%" [14]. "Maternal death occurs due to placental abruption, disseminated intravascular coagulation (DIC), postpartum hemorrhage, or acute renal failure" [15]. "The syndrome of hemolysis, elevated liver enzymes and low platelets, is referred to as HELLP syndrome, has historically been classified as a complication or progression of severe preeclampsia" [16]. "An ischemic-reperfusion injury starts the liver damage in HELLP syndrome" [17]. "The clinical presentation may vary from patient to patient with HELLP syndrome, and may present with colicky mid-epigastric and/or right upper quadrant pain associated with fatigue, nausea and vomiting. Associated features may include jaundice, increasing abdominal girth, leg swelling, headache, visual changes, severe bleeding, placental abruption, acute kidney injury, liver hematoma, or retinal detachment. Upon physical examination, the blood pressure >140/90 mmHg, hypertensive patient and may have pedal edema or ascites, right upper quadrant or epigastric tenderness may be noted. An appropriate physical

examination must be conducted if any of the above complications are suspected" [18].

2. CASE PRESENTATION

A 31-year-old female patient, came with the history of, one episode of GTCS (Generalized Tonic Clonic Seizure) at home around 7:30AM in the morning, stiffening of joints and up rolling of eyes. The patient also had 2 episodes of vomiting at the night. The patient was then after brought to hospital and was drowsy and confused but arousable. The patient was, 33 weeks amenorrheic with IUD.

2.1 Past History

Since last two three days, the patient had swelling on both the legs, and was treated for the same on OPD basis. The patient had history of one episode of convulsion 7 years back during pregnancy- was not on any medications. No history of Fall, Seizure, Trauma or Fever. Menstrual History- Irregular. LSCS, G2P2L1 (2nd miscarriage -the baby died inside the womb due to the comorbidities). Fetal Heart Rate was 110-115/min, Per Vagina- OS closed, Vertex Position- down. L.M.P-7/11/21 & E.D.D-14/08/2022.

2.2 Physical Examination

During the of admission, Temperature was 97°F, Pulse Rate was 122/min, Respiratory Rate was 22/min, Blood Pressure was 138/78 mmHg, Pain Score: 0/10, Random Blood Sugar: 140mg/dL, SpO₂: 100% on RA. The Respiratory System's air entry was equal, Abdomen was Soft, non-tender Cardiovascular S1S2 were normal & no murmur, the Central Nervous System notes were Drowsy but arousable, confused state, GCS, E 3/4, V4, M6, Pupils 2mm BERL, all 4 limbs moving. Musculoskeletal System/Spine/Extremities showed Stiffening of hands.

Provisional diagnosis: Seizure?

2.3 MRI Brain Screening with Contrast Showed Following Impressions

Mild mucosal thickening is seen in right ethmoid air cells, Mild fluid is seen in right mastoid air cells. Mild abnormal enhancing subgalea soft tissue is noted in the left parietal and right parieto-temporo-occipital region, and MRI-Screening Charges left mastoid air cells and orbits are clear.

Near symmetrical white matter edema with associated cortical swelling noted in bilateral fronto-parietal and bilateral posterior parieto-temporo-occipital lobe. Abnormal altered signal

intensity also noted in bilateral cerebellar hemisphere, brainstem, right thalamus and bilateral basal ganglia with moderate perifocal edema adjacent to the bilateral basal ganglia.

Table 1. Report of laboratory investigations

Hematology		Biochemistry	
Hemoglobin levels low	8.1gm/dl	Chloride ions	111meq/ L
Total RBC count, low	2.82 mill/cmm	Bicarbonates	17.7 meq/L
Hematocrit	23.2%,	Others	
Mean Corpuscular Volume	82.3%,	D-dimer	9527.77 ng/ml.
Mean Corpuscular Hemoglobin Concentration	34.9%	C-Reactive Protein	21.1mg/L
Red Cell Distribution Width	14.4%	Lactate Dehydrogenase	1728U/L
Total leucocyte count	15.64 thou/cmm.	Random plasma glucose	321mg/dl.
Platelets	26 thou/cmm.		
Liver function tests			
Total Bilirubin	2.35 mg/dl	Alanine Aminotransferase/SGPT	110 U/L
Direct Bilirubin	0.38 mg/dl	Alkaline Liver Phosphatase	192 U/L
Aspartate Aminotransferase/SGOT	277 U/L	Total protein	5.78 gm/dl
		Albumin	2.24 gm/dl.
Urine examination			
Presence of RBCs and Epithelial cells, Leucocytes & Granular casts (Low, High)			

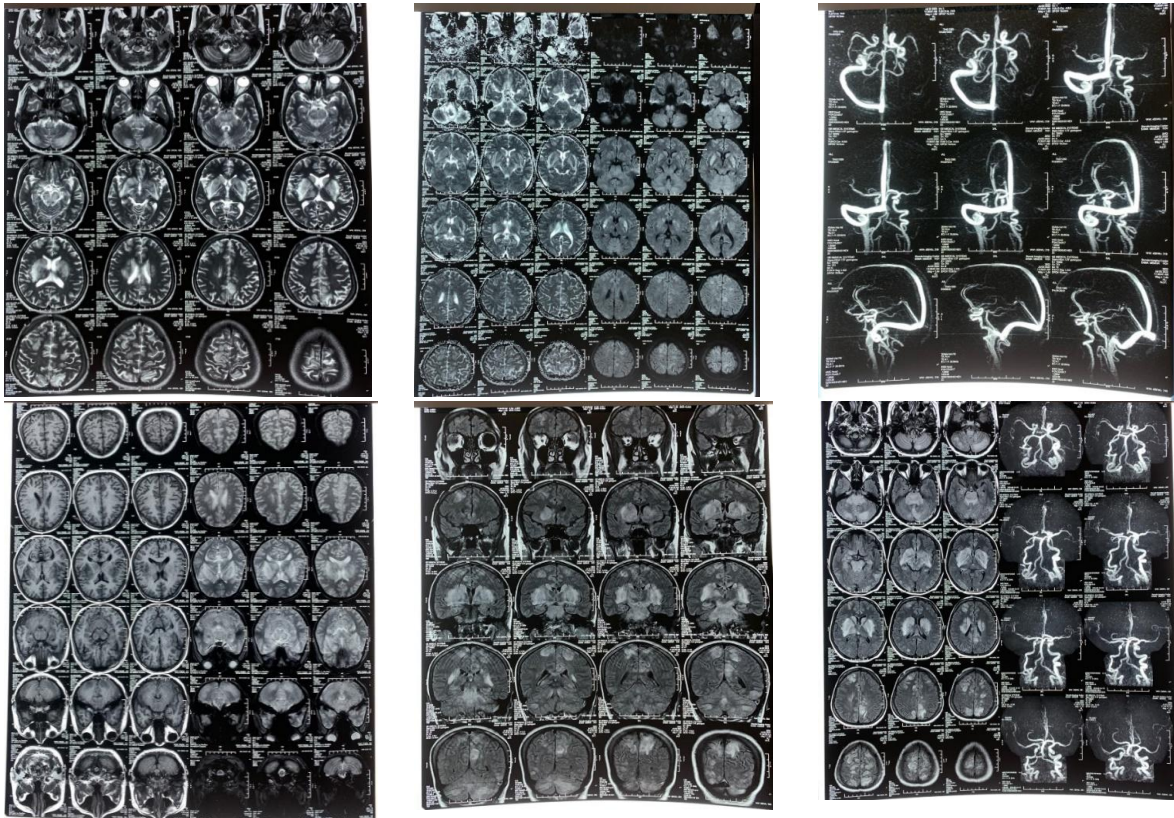


Fig. 1. Final diagnosis: PRES with HELLP syndrome to R/O Viral encephalopathy

USG (obs.): single live intrauterine pregnancy in cephalic presentation of 30 weeks. The cervical length was 2.8cms. The liquor was adequate. No active limbs movement noted during scanning. Later on, FHR was not seen and the blood clot was identified in two ventricles

Table 2. Application of several drugs with their doses and frequency

SR. NO.	Drug	Dose	Route	Frequency	Date
1.	INJ. LEVIPIL	1GM THEN 500MG	IV	STAT/ THEN (500MG) BD	03.07.22 TO 06.07.22
2.	INJ. MIDAZOLAM	2ML	IV	STAT	02.07.22
3.	INJ. NS	80ML/HR	IV	/HR INFUSION	03.07.22 TO 06.07.22
4.	INJ. PANTOCID	40MG	IV	STAT & OD	03.07.22 TO 06.07.22
5.	INJ. EMESET	4MG	IV	STAT & SOS	03.07.22 TO 06.07.22
6.	INJ. CEFTRIAZONE	2GM	IV	STAT & BD	03.07.22 TO 04.07.22
7.	INJ. MGSO4	4GM	IV	IN 100CC NS IV OVER 30 MINS F/B 1GM/ HR INFUSION	03.07.22
8.	INJ. RL/ ISOLYTE M		IV	100ML/HR ACC. TO CVP	03.07.22 TO 06.07.22
9.	INJ. NTG	25MG	IV	IN 50 ML NS STAT @BP	03.07.22 TO 04.07.22
10.	INJ. BETAMETASONE	12MG	IV	STAT 1PM	03.07.22
11.	INJ. TRAMADOL		IV	1CC IN 100ML NS SOS	03.07.22
12.	INJ. FENTANYL+MIDAZOLAM+NS	(20MG+20ML +100ML)	IV		03.07.22 TO 05.07.22
13.	INJ. MEROPENEM	2GM	IV	100ML NS OD	04.07.22 TO 06.07.22
14.	INJ. TARGOCID	400MG		BD	04.07.22 TO 06.07.22
15.	INJ. LOBET INFUSION		IV	NEAT 1ML/HR.	04.07.22 TO 06.07.22
16.	TAB. NICARDIA	10MG	PO	TDS	04.07.22 TO 06.07.22 TARGET BP<140/90 MMHG
17.	INJ. OPTINEURON	1AMP	IV	40ML/HR OD	04.07.22 TO 06.07.22

Associated leptomeningeal enhancement also noted in all milder fronto parietal temporal occipital sulci and along the cerebellar folia. These findings are in favor of posterior reversible encephalopathy syndrome (PRES) with involvement of basal ganglia could represent atypical uncommon involvement.

Rounded area of restricted diffusion with corresponding hypo enhancement on T1-weighted images noted in the bilateral basal ganglia which may represent irreversible changes. Mild fluid in the right mastoid air cells, secretions in the bilateral nasal cavity and mild mucosal thickening in the right ethmoid sinus. Subgalea soft tissue swelling noted in the left parietal and right parieto-temporal region.

3. DISCUSSION AND CONCLUSION

HELLP syndrome is a possibly life-threatening dynamic condition for which a standardized approach to diagnosis and management is paramount. Despite, HELLP syndrome is well-thought-out to be a hypertensive multi-organ disorder during pregnancy, the intensity of high blood pressure does not associate to the severity of the ailment; therefore, the analysis should be based on biochemical laboratory evidence. Besides, one must keep in mind that clinical presentation is one of the foremost factors that allow the judicious diagnosis of this condition. All in all considering these factors, the implementation of standardized diagnostic criteria based on laboratory findings such as the Mississippi triple-class system for HELLP

syndrome creates a possibility of defining this disorder similarly in most cases, applying the same treatment options in the same stage of the condition, and improving maternal and perinatal outcomes. The outcomes of various studies suggests that hemorrhage is allied with deprived outcome in PRES whereas toxemia of pregnancy (pre-eclampsia/eclampsia) is associated with an improved outcome in PRES patients. Diffusion restriction (cytotoxic edema) may indicate a poor outcome, although these results did not reach statistical significance. Also, studies are warranted to evaluate the detrimental effects of hemorrhage, cytotoxic edema, pre-eclampsia/eclampsia and other related risk factors in PRES patients. The management of both the syndromes requires supportive management as well as a concrete therapeutic plan. If handled judiciously, the life of mother and the new born will be on safer end.

CONSENT

As per international standard or university standard, patient(s) written consent has been collected and preserved by the author(s).

ETHICAL APPROVAL

As per international standard or university standard written ethical approval has been collected and preserved by the author(s).

COMPETING INTERESTS

Authors have declared that no competing interests exist.

REFERENCES

- Hinchey J, Chaves C, Appignani B, Breen J, Pao L, Wang A, et al. A reversible posterior leukoencephalopathy syndrome. *N Engl J Med*. 1996;334:494–500. DOI: 10.1056/NEJM199602223340803
- McKinney AM, Short J, Truwit CL, McKinney ZJ, Kozak OS, SantaCruz KS et al. Posterior reversible encephalopathy syndrome: incidence of atypical regions of involvement and imaging findings. *AJR Am J Roentgenol*. 2007;189:904–12.
- Fischer M, Schmutzhard E. Posterior reversible encephalopathy syndrome. *Journal of Neurology*; 2017. [PubMed PMID: 28054130]
- Pereira PR, Pinho J, Rodrigues M, Rocha J, Sousa F, Amorim J, Ribeiro M, Rocha J, Ferreira C. Clinical, imagiological and etiological spectrum of posterior reversible encephalopathy syndrome. *Arq Neuropsiquiatr*. 2015;73:36-40.
- Zhang L, Wang Y, Shi L, Cao J, Li Z, Wang YX. Late postpartum eclampsia complicated with posterior reversible encephalopathy syndrome: A case report and a literature review. *Quant Imaging Med Surg*. 2015;5:909-16.
- Pavlidou E, Pavlou E, Anastasiou A, Pana Z, Tsotoulidou V, Kinali M, Hatzipantelis E. Posterior reversible encephalopathy syndrome after intrathecal methotrexate infusion: a case report and literature update. *Quant imaging Med Surg*. 2016;6:605-11.
- Schwartz RB, Jones KM, Kalina P, Bajakian RL, Mantello MT, Garada B, et al. Hypertensive encephalopathy: findings on CT, MR imaging, and SPECT imaging in 14 cases. *AJR Am J Roentgenol*. 1992; 159:379–83. DOI: 10.2214/ajr.159.2.1632361
- Schwartz RB, Bravo SM, Klufas RA, Hsu L, Barnes PD, Robson CD, et al. Cyclosporine neurotoxicity and its relationship to hypertensive encephalopathy: CT and MR findings in 16 cases. *AJR Am J Roentgenol*. 1995; 165:627–31. DOI: 10.2214/ajr.165.3.7645483
- Bartynski WS, Grabb BC, Zeigler Z, Lin L, Andrews DF. Watershed imaging features and clinical vascular injury in cyclosporin A neurotoxicity. *Comput Assist Tomogr*. 1997;21:872–80. DOI:10.1097/00004728-199711000-00005
- Bartynski WS, Zeigler Z, Spearman MP, Lin L, Shaddock RK, Lister J. Etiology of cortical and white matter lesions in cyclosporin-A and FK-506 neurotoxicity. *AJNR Am J Neuroradiol*. 2001;22:1901–14.
- Roth C, Ferbert A. The posterior reversible encephalopathy syndrome: What's certain, what's new? *Pract Neurol*. 2011;11:136–44.
- Hinchey J, Chaves C, Appignani B, Breen J, Pao L, Wang A, et al. A reversible posterior leukoencephalopathy syndrome. *N Engl J Med* 1996;334:494–500.
- Fugate JE, Claassen DO, Cloft HJ, Kallmes DF, Kozak OS, Rabinstein AA. Posterior reversible encephalopathy syndrome: associated clinical and

- radiologic findings. Mayo Clin Proc. 2010 ;85:427–32.
14. Van Lieshout LCEW, Koek GH, Spaanderman MA, van Runnard Heime! PJ Placenta derived factors involved in the pathogenesis of the liver in the syndrome of haemolysis, elevated liver enzymes and low platelets (HELLP): A review. Pregnancy hypertension; 2019. [PubMed PMID: 31494464]
 15. Sadaf N, Haq G, Shukar-ud-Din S. Maternal and foetal outcome in HELLP syndrome at tertiary care hospital. JPMA. The Journal of the Pakistan Medical Association; 2013. [PubMed PMID: 24397093]
 16. Stojanovska V, Zenclussen AC. Innate and Adaptive Immune Responses in HELLP Syndrome. Front Immunol. 2020; 11:667. [PMC free article] [PubMed]
 17. Haram K, Svendsen E, Abildgaard U. The HELLP syndrome: clinical issues and management. A Review. BMC pregnancy and childbirth; 2009. [PubMed PMID: 19245695]
 18. Böhmer AB, Wappler F, Zwissler B. Preoperative risk assessment—from routine tests to individualized investigation. Deutsches Ärzteblatt International. 2014 Jun;111(25):437.

© 2022 Patel et al.; This is an Open Access article distributed under the terms of the Creative Commons Attribution License (<http://creativecommons.org/licenses/by/4.0>), which permits unrestricted use, distribution, and reproduction in any medium, provided the original work is properly cited.

Peer-review history:
The peer review history for this paper can be accessed here:
<https://www.sdiarticle5.com/review-history/94684>