



# Hyperparathyroidism's Rare Reveal: Young Adult with Recurrent Pancreatitis

Kirushanth Sathiyathan <sup>a++\*</sup>, Senuri Dias <sup>a#</sup>,  
B Lalith Perera <sup>a†</sup> and T Nissanthan <sup>a++</sup>

<sup>a</sup> National Hospital of Sri Lanka, Sri Lanka.

## *Authors' contributions*

*This work was carried out in collaboration among all authors. All authors read and approved the final manuscript.*

## *Article Information*

### **Open Peer Review History:**

This journal follows the Advanced Open Peer Review policy. Identity of the Reviewers, Editor(s) and additional Reviewers, peer review comments, different versions of the manuscript, comments of the editors, etc are available here: <https://www.sdiarticle5.com/review-history/115100>

**Case Report**

**Received: 05/02/2024**

**Accepted: 10/04/2024**

**Published: 15/04/2024**

## **ABSTRACT**

**Introduction:** Acute pancreatitis is a common condition with significant morbidity and mortality. While the most common causes are gallstones and alcohol, there are rarer causes such as primary hyperparathyroidism. Most patients with primary hyperparathyroidism are asymptomatic while symptomatic patients present with bone disease and renal manifestations. They can still present with acute pancreatitis, mostly in advanced disease. Infrequently, it can be the first presentation of primary hyperparathyroidism as depicted in our case.

**Case Presentation:** We herein report a case of a 20-year-old male presenting with epigastric pain and vomiting, relieved by bending forward.

**Clinical Findings and Investigations:** On examination, the patient was in pain but hemodynamically stable with a soft abdomen. Initial investigations found elevated serum amylase levels and imaging confirms the acute pancreatitis. However initial etiology screening is normal. Further investigations revealed hypercalcemia. A diagnosis of primary hyperparathyroidism and parathyroid adenoma was made based on an elevated parathyroid hormone level and USS

<sup>++</sup> Registrar Surgery;

<sup>#</sup> Relief House Officer;

<sup>†</sup> Consultant Surgeon;

\*Corresponding author: E-mail: kirushanths@gmail.com;

neck showing a left inferior parathyroid adenoma. Technetium-99m methoxy-isobutyl-isonitrile scintigraphy was used to localize the parathyroid adenoma.

**Intervention and Outcome:** The patient underwent left lower parathyroidectomy. After the surgery, he had a normal parathyroid hormone level with no further episodes of acute pancreatitis.

**Relevance and Impact:** Acute pancreatitis is a rare presentation of primary hyperparathyroidism. Primary hyperparathyroidism should be suspected in patients with acute pancreatitis with no common etiologies. Diagnosis is important since parathyroidectomy is a definitive treatment method which can prevent progression into chronic pancreatitis.

*Keywords: Acute pancreatitis; primary hyperparathyroidism; parathyroid adenoma; case report.*

## 1. INTRODUCTION

Acute pancreatitis is an inflammatory disease of the exocrine pancreas which can lead to significant short- and long-term morbidity with often ignored impact on quality of life due to chronic pain. A diagnosis of acute pancreatitis requires two out of three criteria: abdominal pain typical of pancreatitis, an elevated serum amylase or lipase by three folds, and findings consistent with pancreatitis on cross-sectional abdominal imaging [1]. Gallstones and heavy alcohol consumption are the leading causes of acute pancreatitis followed by hypertriglyceridemia and drugs. Primary hyperparathyroidism causing hypercalcemia is one of the rarer causes of acute pancreatitis [2].

Primary hyperparathyroidism is an endocrine disorder characterized by hypercalcemia and elevated or high normal levels of parathyroid hormone. Approximately 80%-85% of patients with primary hyperparathyroidism have a single parathyroid adenoma, and 10 to 15% have more than one adenoma. Parathyroid carcinoma accounts for less than 1% of cases of hyperparathyroidism [3]. In developed countries, more than three-fourths of the patients are asymptomatic. When symptomatic, they mostly present with bone disease and renal complications such as nephrocalcinosis and nephrolithiasis [4]. In high-income countries, the classic presentations of primary hyperparathyroidism have become less severe or even absent. While a majority of patients with primary hyperparathyroidism in developing countries remain symptomatic, recent studies report a significant decrease in the clinical and biochemical severity of the disease [5].

In this case, a young man presented with recurrent pancreatitis without any obvious cause or symptoms of hyperparathyroidism. However, due to a high index of suspicion, it was possible to prevent the patient's condition from progressing into chronic pancreatitis and long-

term morbidity. This case report has been reported in line with the SCARE criteria [6].

## 2. CASE PRESENTATION

A 20-year-old Asian unmarried male presented to the surgical casualty unit by himself with abdominal pain associated with nausea and vomiting. It was an epigastric pain that worsened with movements and was relieved by bending forward. He doesn't have a personal, or family history of tumors related to multiple endocrine neoplasia syndrome. On initial examination, he had epigastric tenderness. His other systemic examination findings including examination of the neck were unremarkable. During this episode, his vitals were stable.

He has never consumed alcohol. Initial investigations showed an elevated serum amylase (1122 U/L) with no leukocytosis (WBC  $6.13 \times 10^3/\mu\text{L}$ ), liver transaminases in the normal range and a normal lipid profile. Ultrasound abdomen was normal. He was diagnosed with acute pancreatitis clinically. A month later, he had a similar episode with elevated serum amylase (1657 U/L). During this second episode, an ultrasound abdomen revealed a resolving pancreatitis.

Since he does not consume alcohol and his ultrasound scan and lipid profile were normal, he underwent the next step of further investigation to determine the cause of recurrent pancreatitis. On further investigations, both Magnetic Resonance Cholangiopancreatography and CECT abdomen were normal. He was found to have an elevated serum calcium level of 14 mg/dl (8.6 – 10.2), a high level of urine calcium creatinine ratio of 0.445 (<0.14) and an elevated level of PTH 555 pg/mL (16 – 60.4) and was diagnosed with primary hyperparathyroidism.

DEXA scan of the patient showed that he was suffering from osteoporosis (Tscore -2.4) (Fig. 1

A-C). Normal FSH, LH, TSH and 9 am cortisol excluded MEN syndrome.

Initial ultrasound imaging of the neck showed a left parathyroid gland enlargement. This was confirmed by a CECT neck showing an oval-shaped hypo-attenuated focal lesion posteroinferior to the left lobe of the thyroid and a sestamibi scan showing increased trace activity seen just below the lower pole of the left lobe of the thyroid (Fig. 2).

He was started on furosemide 20 mg daily and hydrated well. After proper preoperative preparation, the patient underwent exploration and was found to have an enlarged left parathyroid gland. The rest of the parathyroid glands and thyroid were macroscopically normal. As a result, the patient underwent left-sided parathyroid gland excision. The histopathological report confirms the presence of a parathyroid adenoma (Fig. 3).

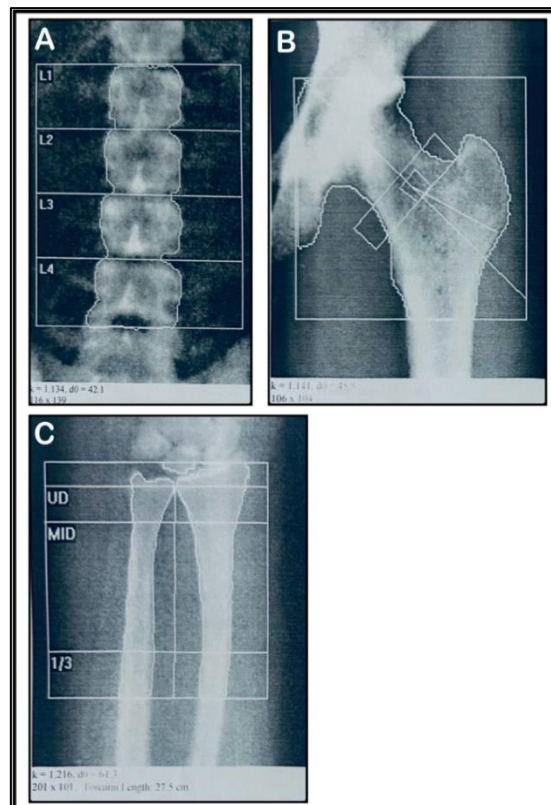
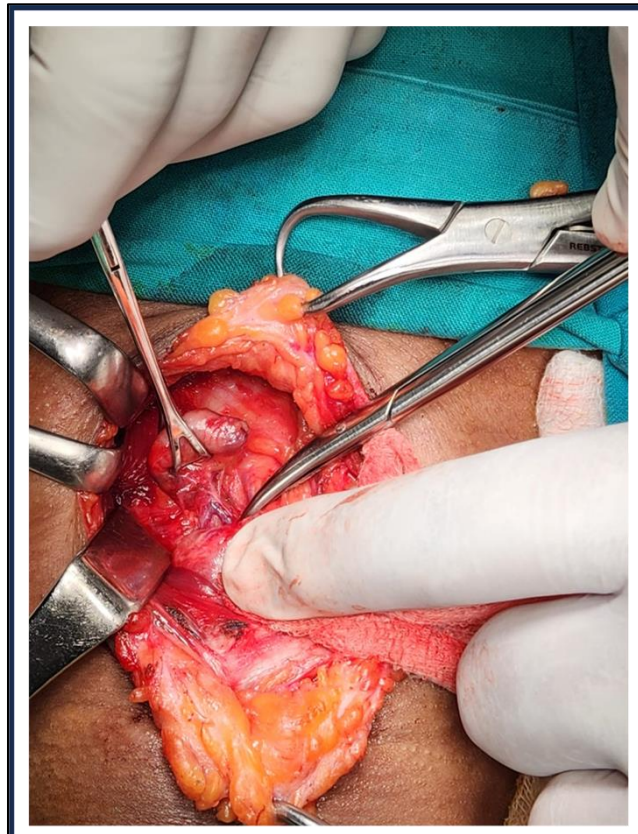


Fig. 1. Showing DEXA scan of Lumbar spine showing osteopenia (A), Left Hip osteopenia (B) and Left forearm showing Osteoporosis (C)

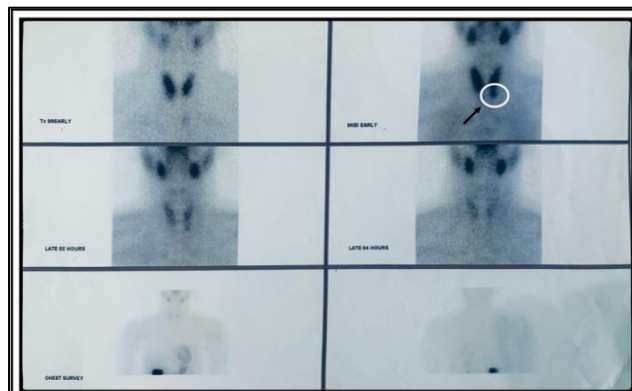

Fig. 2. <sup>99m</sup>Tc- Tetrofosmin parathyroid scan report. The circled and arrowed shows increased tracer activity just below the lower pole



**Fig. 3. Left inferior parathyroid gland being removed**

Immediately before the incision, the serum PTH level was 613 pg/mL. However, the level of PTH dropped to 104 pg/mL just 10 minutes after the excision of the inferior parathyroid gland. There were no postoperative complications, and the patient is currently on follow-up. He has had no further episodes of pancreatitis during 6 months of follow up.

### **3. DISCUSSION**

Pancreatitis is a condition characterized by acute inflammation and a systemic inflammatory response, which can lead to significant morbidity and mortality. The most common causes of pancreatitis are biliary (30-40%), alcoholic (30-40%), and idiopathic (20-30%). Other causes include hypertriglyceridemia, hypercalcemia, trauma, drugs, surgical and endoscopic procedures, neoplasms, infectious diseases, autoimmune diseases, and genetic factors (which account for only 8% of cases) [7].

Pancreatic disease is an uncommon complication in primary hyperparathyroidism with a prevalence varying from 1.5-13%. This explains the occurrence of pancreatitis only at

advanced stages of parathyroid disease [8]. Despite that in our patient, acute pancreatitis was the first clinical manifestation of primary hyperparathyroidism. Pancreatitis could be the sole presenting complaint of primary hyperparathyroidism and therefore should be an anticipated complication. It shows the importance of investigating for primary hyperparathyroidism in any patient with pancreatitis and normal or elevated serum calcium levels in the absence of other common causes of pancreatitis [8].

Patients with primary hyperparathyroidism and hypercalcemia have a ten-fold greater risk of suffering from acute pancreatitis as compared to the general population [9]. Even though a clear pathophysiological basis has not been established, hypercalcemia appears to be the main causative factor in the association of primary hyperparathyroidism and acute pancreatitis. This can be explained by several mechanisms. One such hypothesis is that hypercalcemia promotes the activation of pancreatic enzymes like trypsinogen to trypsin. This in turn inhibits the auto-catalytic action and can lead to auto-digestion of the pancreas. Enzyme activation can also be triggered by

obstruction of the pancreatic duct with deposition of calcium. Hypercalcemia is also known to induce cholecystokines which cause stimulation of pancreatic acinar cells and leads to activation of pancreatic proteases. Mutations in the SPINK1 (serine protease inhibitor Kazal type I) and CFTR (cystic fibrosis transmembrane conductance regulator) genes have been found in patients with primary hyperparathyroidism with acute pancreatitis. This shows that genetic modifications also play a role in the development of acute pancreatitis in these patients [2].

The mean age at diagnosis can vary [10]. Studies show an average age of 36.3 +/- 16 yrs. Aslam et al shows that primary hyperparathyroidism associated with pancreatitis is more common in males with a male-to-female ratio of 2:1. This finding has been proved in several previous studies and is consistent with our case.

It is crucial to estimate serum calcium levels following unexplained pancreatitis episodes to promptly diagnose primary hyperparathyroidism and prevent it from worsening [11]. It is important to assess serum calcium levels in combination with parathyroid hormone levels to diagnose hyperparathyroidism. There is a negative feedback mechanism on PTH secretion by serum calcium. Therefore, in the presence of a high serum calcium level, both an elevated PTH level and a normal PTH level indicate hyperparathyroidism. Elevated levels of serum calcium and PTH confirm the diagnosis [3]. Hypercalciuria can further support the diagnosis of primary hyperparathyroidism. Urine calcium concentration can increase when more calcium is filtered exceeding the renal capacity for calcium reabsorption [12].

Similarly in the Sri Lankan context, serum calcium is not routinely measured in patients presenting with the first episode of acute pancreatitis since gallstones and alcohol are the main culprits. Most patients suffer for two or more episodes of pancreatitis before a diagnosis of primary hyperparathyroidism is made [13]. Although imaging of the parathyroid gland is not necessary to diagnose primary hyperparathyroidism, precise localization of parathyroid adenoma is done by four imaging studies which enables minimal invasive parathyroidectomy. Ultrasound of the neck is widely used as the initial imaging modality. Sestamibi scintigraphy, CT and magnetic resonance imaging (MRI) can also be used to

localize abnormal parathyroid tissue. The sensitivity of the USS neck remains 80% for the preoperative localization of parathyroid adenomas while a Tc99m Sestamibi scan of the parathyroid glands has a sensitivity of 92%. Newer modalities like PET-CT imaging are advantageous in terms of detecting smaller adenomas. In our case, the diagnosis was made with elevated serum calcium and PTH levels and parathyroid adenoma was diagnosed with an ultrasound scan of the neck, while localization was done by CECT of the neck [14]. Sestamibi scan was used to rule out any ectopic parathyroid tissue [15].

Parathyroidectomy remains to be the definitive treatment method for primary hyperparathyroidism [16]. The intraoperative PTH level should decrease by at least 50% after removal of a single parathyroid adenoma. This measurement can vary when more than one gland is involved [14]. Some studies showed a significant reduction in the serum calcium and parathyroid hormone levels in all patients following parathyroidectomy in addition to reducing the number of episodes and the severity of abdominal pain in patients with pancreatitis. Therefore, parathyroidectomy improved the clinical outcomes of primary hyperparathyroidism and, possibly, prevented further attacks of pancreatitis [11,17]. Our patient's symptoms also improved without any recurrence of pancreatitis over the 6-month follow-up period. Potential postoperative complications even though infrequent, include recurrent laryngeal nerve injury, wound infection, bleeding, and postoperative transient hypocalcemia [14]. Our patient had an uncomplicated postoperative period.

#### 4. CONCLUSION

This case report emphasizes the importance of early diagnosis of primary hyperparathyroidism in a patient with acute pancreatitis with no common etiologies. Even though a rare manifestation of primary hyperparathyroidism, further investigations should be carried out when there is clinical suspicion. Parathyroidectomy is an effective definitive treatment that can be offered to these patients with a high curative rate.

#### CONSENT

Written informed consent was obtained from the patient for publication of this case report and accompanying images.



## ETHICAL APPROVAL

As per international standards or university standards written ethical approval has been collected and preserved by the author(s).

## COMPETING INTERESTS

Authors have declared that no competing interests exist.

## REFERENCES

1. Szatmary P, Grammatikopoulos T, Cai W, Huang W, Mukherjee R, Halloran C, et al. Acute pancreatitis: Diagnosis and treatment. *Drugs*. 2022;82(12):1251–1276.
2. Basavaraj R Patil, Nirdhum Shikha. Acute pancreatitis predating the diagnosis of parathyroid adenoma. *International Journal of Head and Neck Surgery*. 2022;13:82–4.
3. Sudharshan M, Kumaran R, Sundaramurthi S, Krishnaraj B, Sistla SC. Acute pancreatitis as the index manifestation of parathyroid adenoma. *Cureus*. 2021;13(8).
4. Walker MD, Bilezikian JP. Primary hyperparathyroidism: Recent advances. *Current Opinion in Rheumatology*. 2018; 30(4):427-439.
5. Castellano E, Attanasio R, Boriano A, Borretta G. The clinical presentation of primary hyperparathyroidism: A Southern European perspective over the last 2 decades. *Endocrine Practice*. 2018;24(12): 1023–1029.
6. Sohrabi C, Mathew G, Maria N, Kerwan A, Franchi T, Agha RA. The Scare 2023 guideline: Updating consensus surgical case report (Scare) guidelines. *Int J Surg*. 2023;109:1136–40.
7. Carlos R, Zilio M, Lucas A, Fernando A, Costas A. Systematic review of most common causes of acute pancreatitis; 2019. Accessed: 04 April 2024. Available: <https://www.preprints.org/manuscript/201902.0220/v1/download>
8. Sanyal SD, Zaman S, Roy A, Raychowdhury R. Parathyroid Adenoma Presenting as Acute Pancreatitis. *World Journal of Endocrine Surgery*. 2021;13: 32–4.
9. Vera C, Díez M, San Román R, Ratia T, Granell J. Primary hyperparathyroidism and acute pancreatitis. *Endocrinología y Nutrición (English Edition)*. 2013;60:275–6.
10. Diallo I, Fall CA, Ndiaye B, Mbaye M, Diedhiou I, Ndiaye AR, et al. Primary hyperparathyroidism and pancreatitis: A rare association with multiple facets. *Int Sch Res Notices*. 2016;2016:1–4.
11. Aslam M, Talukdar R, Jagtap N, Rao Gv, Pradeep R, Rao U, et al. Clinical profile and outcome of parathyroid adenoma-associated pancreatitis. *Saudi J Med Med Sci*. 2018;6:95.
12. Shariq OA, Strajina V, Lyden ML, McKenzie TJ, Wermers RA, Thompson GB, et al. Parathyroidectomy improves hypercalciuria in patients with primary hyperparathyroidism. *Surgery*. 2020; 168(4):594–600.
13. Pathmanthan S, Bulugahapitiya DUS, Gamage B. Recurrent pancreatitis in a patient with primary hyperparathyroidism (PHPT). *Sri Lanka Journal of Diabetes, Endocrinology and Metabolism*. 2013;3(1): 35.
14. Insogna KL. Primary hyperparathyroidism. Solomon CG, editor. *New England Journal of Medicine [Internet]*. 2018;379:1050–9. Available: <http://www.nejm.org/doi/10.1056/NEJMcp1714213>
15. Fu CH, Chen HF. Parathyroid adenoma presenting as chronic pancreatitis: A case report and literature review. *Medicine (United States)*. 2022;101:E31750.
16. Singh BK, Toshib GA, Rathore YS, Agarwal S, Chumber S, Damle N. Gastric outlet obstruction following recurrent pancreatitis uncovers a giant parathyroid adenoma: A case report. *J Asean Fed Endocr Soc*. 2022;37:1–6.
17. Diaconescu MR, Costea I, Glod M, Terinte R, Diaconescu S. Parathyroid adenomas in adults and adolescents. *Critical Appraisal and Surgical Strategy in 18 Cases*. *Chirurgia (Romania)*. 2017;112:18–24.

© Copyright (2024): Author(s). The licensee is the journal publisher. This is an Open Access article distributed under the terms of the Creative Commons Attribution License (<http://creativecommons.org/licenses/by/4.0>), which permits unrestricted use, distribution, and reproduction in any medium, provided the original work is properly cited.

Peer-review history:

The peer review history for this paper can be accessed here:

<https://www.sdiarticle5.com/review-history/115100>