

CAD-CAM Designed Ceramic Veneer for the Restoration of Peg-shaped Lateral Incisor: Case Report

MOHAMMAD H AL REFEAI



ABSTRACT

Peg shaped lateral incisors are considered to be the most common discrepancy concerning tooth size. This results in reduced size of the tooth, anterior diastema, and most often an unrepresentable smile. Nowadays, the concepts of Adhesive Dentistry and wider use of ceramic veneers have allowed all ceramic restorations to be more acceptable in terms of function and aesthetics as well as establishing a good smile harmony. The aim of the clinical report presented, is to demonstrate a conservative approach of treatment so as to improve an aesthetically disharmonious smile resulting from a unilateral peg-shaped lateral incisor. Here the authors present a case of 33-year-old Saudi male, who sought treatment for solving his aesthetically disharmonious smile. Digital Impression guides were utilised for planning and fabricating Lithium Disilicate veneers. This was done to restore the size, morphology, function, as well as the aesthetics of upper lateral incisors including the overall smile of the patient. The veneers using Lithium disilicate provided the harmonisation of smile of the patient. It further resulted in recovering of the tooth size including its shape as well as anatomical characteristics.

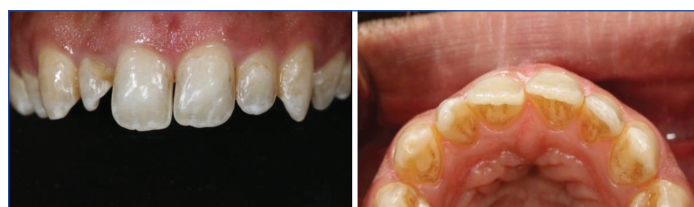Keywords: Aesthetic, Computer aided design, Computer-aided manufacturing

CASE REPORT

A 33-year-old Saudi male patient was seen for a restorative consultation. His chief complaint was dissatisfaction with shape of the upper right lateral incisor compared to left lateral incisor tooth. A comprehensive oral and radiographic examinations were completed. It showed no active dental caries or signs of periodontal disease. The enamel showed signs of white stain lesion in the incisal one-third of anterior teeth. Medical history check revealed no contraindication for elective dental care. The proposed treatment options were first bleaching followed by direct resin based composite restoration. Second, bleaching and followed by indirect ceramic veneer restoration. The patient was informed about the differences between two options and specifically removal of some enamel when utilising the indirect restoration. The patient elected to choose the second option without bleaching due to high cost and risk of hypersensitivity. He was also short in time as he had a wedding in two days. Informed consent was obtained from the patient, and treatment was initiated.

Preparation Procedure

Preoperative photograph and initial upper and lower impression were obtained [Table/Fig-1,2]. The lingual surface of the ceramic veneer was prepared using a butt joint margin, a reduction of 1.5 mm was done on the incisal edge and 0.3-0.8 mm on facial surface utilising a round-ended diamond cutting bur (Brasseler, Savannah, GA, USA). Final preparation was then finished and polished using Soflex disc (Sof-Lex™, 3M, USA). Soft tissue and marginal exposure management were out by utilising retraction cord (size 000, Ultrapak, Ultradent Inc, USA) and Astringent retraction paste (3M ESPE retraction capsule, 3M, USA).

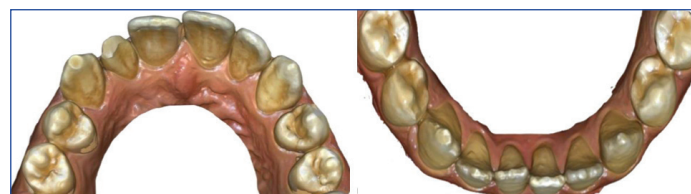


[Table/Fig-1]: Preoperative photograph frontal view.

[Table/Fig-2]: Preoperative photograph occlusal view. (Images from left to right)

Final Impression Procedure

A CAD digital impressions of the prepared upper right lateral incisor and the opposing lower arch were taken using intraoral digital scanner (Primescan, Dentsply Sirona, USA) [Table/Fig-3,4]. This Intraoral digital scanner was again used for a closed-jaw record. Digital information obtained using the previously acquired lower and upper scans of the arches with the closed-bite scan was overlapped by the CEREC software (Dentsply Sirona, USA) forming a virtual bite registration as well as articulation [Table/Fig-5,6]. The finalised CAD data was then uploaded by means of Connect SW software to a nearby private dental laboratory for marking the veneer margins so as to accomplish virtual ditching method for adequate marginal design and fabrication. Shade selection was done and recorded for the dental laboratory via clinical photographs. The veneer was virtually designed using CEREC software (Dentsply Sirona, USA). The provisional veneer was made from putty index of the original tooth that needed to be splinted for better retention and was eventually fabricated using polymethyl-methacrylate (PMMA) Vita A2. Cementation of the provisional veneer was done utilising flowable composite with spot etching (35% phosphoric acid) and spot bonding agent (Excite F DSC, Ivoclar vivadent, USA). Finally, the definitive laminate veneer designs were milled using low translucency IPS E.Max (Vita A2) milling blocks (Ivoclar-Vivadent, Amherst, NY, USA) [Table/Fig-7,8].

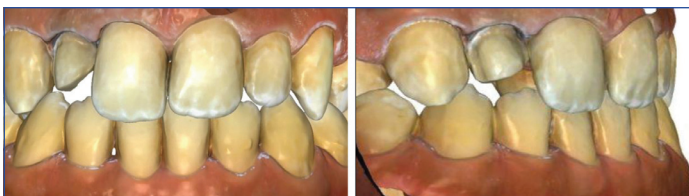

[Table/Fig-3]: Digital upper arch impression using primescan.

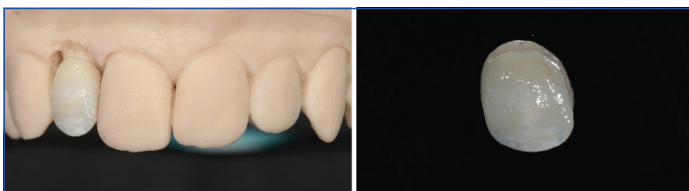
[Table/Fig-4]: Digital lower arch impression using primescan. (Images from left to right)

Cementation Procedure

At the time of the appointment for insertion, the provisional veneer was removed and the prepared surface was cleaned from remaining temporary cement using hand scaler and Soflex discs for polishing. A translucent try-in paste (variolink esthetic LC,

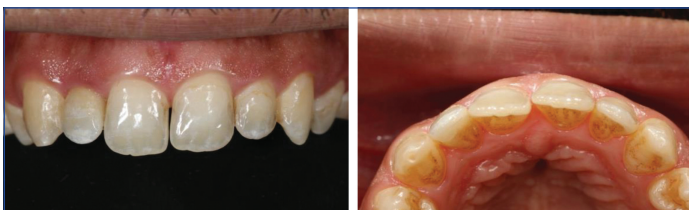

[Table/Fig-5]: Digital bite registration frontal view.
[Table/Fig-6]: Digital bite registration lateral view. (Images from left to right)

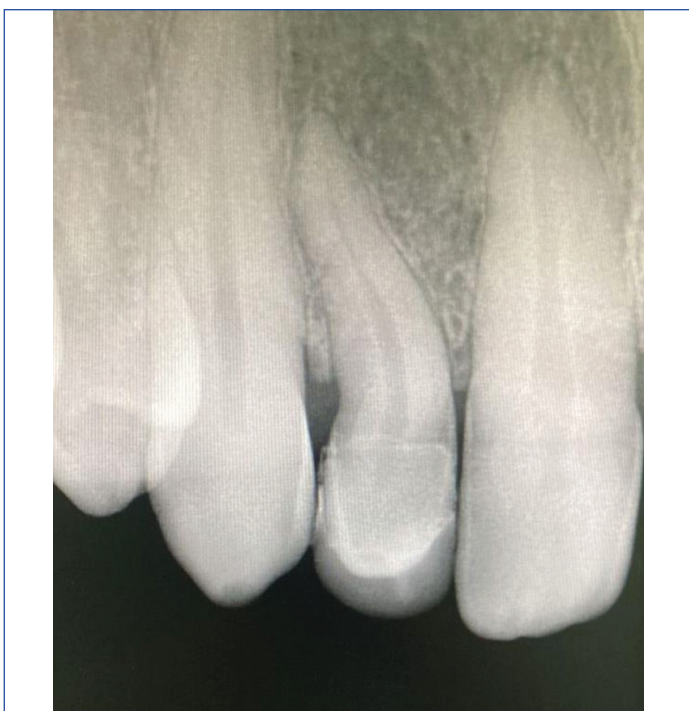

[Table/Fig-7]: Printed dental solid model for upper arch.
[Table/Fig-8]: Milled porcelain veneer. (Images from left to right)

ivoclar vivadent) was used to verify for marginal adaptation, fit of the restoration, as well as interproximal contacts, and occlusion. A fine diamond bur (Brasseler USA) was used for minor adjustments to the interproximal contacts. These contacts were then polished making use of chairside ceramic polishing kit (Brasseler USA). After the final outcome was approved by the patient, 9.5% hydrofluoric acid as an etchant for 20 seconds with silane applied and air dried (monobond plus, ivoclar vivadent) was used on all the internal bonding surfaces of the laminate veneer. The prepared laminate veneer was then cemented with the use of a translucent light-cure resin cement (variolink esthetic LC, ivoclar vivadent) after following the manufacturer's instructions. Excess material cement was removed from the tooth margins and eventually cured using a VALO Grand LED Curing Light (Ultradent Corp) for 10 seconds according to manufacturer's instructions [Table/Fig-9-11]. Patient



[Table/Fig-9]: Postoperative photograph frontal view.
[Table/Fig-10]: Postoperative photograph occlusal view. (Images from left to right)



[Table/Fig-11]: Postoperative radiograph.

was instructed to avoid biting on hard substances that might result in fracture or deboning of the ceramic veneer.

DISCUSSION

The smile plays an important role in the peoples' self-perception and personality. Its importance impacts the facial expression and physical appeal. People with positive characteristic such as intelligence, good well-being, and sociability were associated to their Harmonic smile [1]. Restoring the harmonic smile of the patient in the present case was thus important as it was linked to factors associated to a high social interaction gatherings like wedding. Majority of concern related to esthetic disharmony was directly related to colour, position, size, and shape of the teeth [2-4]. The conical shaped teeth (peg-shaped teeth) of upper anterior teeth specifically lateral incisor were reported as one of the most common morphological variations in the permanent teeth [5]. The prevalence of peg-shape lateral incisor in Jizan and eastern Saudi population was 0.36% and 1.1%, respectively [6,7].

Many restorative options were proposed by the literature for the management of peg-shaped lateral incisors. It includes direct and indirect resin-based composite, full ceramic crowns, and ceramic veneers. The resin-based composite restoration is considered a reliable material for such cases due to good physical properties, esthetic quality, and marginal integrity. Ceramic based restoration provides optimal esthetic outcome due to its high colour stability and better resistance to abrasion when compared to resin-based restoration [8,9].

In the presented case, it can be assumed that the ceramic full crown was not indicated because it would be invasive towards the pulp vitality. However, for important time limitation and high esthetic demand as described in the presented case, ceramic veneer was the treatment of choice. No case report was found in the literature that utilised CAD-CAM fabricated laminate veneer specifically acquired with Primscan scanner for the treatment of peg-shaped lateral incisor. However, the long term success and survival of laminate porcelain veneer and CAD-CAM fabricated laminate veneer is well established. The success of both form of treatment option was in term of colour matching, ceramic surface, marginal discolouration and integrity [10,11].

CONCLUSION(S)

The CAD-CAM designed ceramic veneers are a reliable esthetic solution for peg-shaped lateral incisors. Its indication should be carefully assessed considering the effect of various factors such as patient expectation, clinical finding, and time limitation.

REFERENCES

- [1] Montero J, Gómez Polo C, Rosel E, Barrios R, Albaladejo A, López-Valverde A, et al. The role of personality traits in self-rated oral health and preferences for different types of flawed smiles. *J Oral Rehabil.* 2016;43(1):39-50.
- [2] Witt M, Flores-Mir C. Laypeople's preferences regarding frontal dentofacial esthetics: tooth-related factors. *J Am Dent Assoc.* 2011;142(6):635-45.
- [3] Miro AJ, Shalman A, Morales R, Giannuzzi NJ. Esthetic smile design: Limited orthodontic therapy to position teeth for minimally invasive veneer preparation. *Dent Clin North Am.* 2015;59(3):675-87.
- [4] Samorodnitsky-Naveh GR, Geiger SB, Levin L. Patients' satisfaction with dental esthetics. *J Am Dent Assoc.* 2007;138(6):805-08.
- [5] Bäckman B, Wahlén YB. Variations in number and morphology of permanent teeth in 7-year-old Swedish children. *Int J Paediatr Dent.* 2001;11(1):11-17.
- [6] Salem G. Prevalence of selected dental anomalies in Saudi children from Gizan region. *Community Dent Oral Epidemiol.* 1989;17(3):162-63.
- [7] Bakhurji EA, Aldossary F, Aljarbo J, AlMuhammadi F, Alghamdi M, Nazir MA, et al. Prevalence and distribution of nonsyndromic dental anomalies in children in Eastern Saudi Arabia: A radiographic study. *Scientific World Journal.* 2021;2021:9914670. Doi: 10.1155/2021/9914670. eCollection 2021.
- [8] Mittal N, Mohandas A. Management of peg-shaped lateral with new minimal invasive restorative technique-componeer: A case report. *J Dent Adv.* 2018;10(1):53-55.
- [9] Saatwika L, Prakash V, Anuradha B, Subbiya A. Esthetic correction of anteriors: A case report. *Indian J Public Heal Res Dev.* 2019;10(11):2826.

- [10] Morimoto S, Albanesi RB, Sesma N, Agra CM, Braga MM. Main clinical outcomes of feldspathic porcelain and glass-ceramic laminate veneers: A systematic review and meta-analysis of survival and complication rates. *Int J Prosthodont*. 2016;29(1):38-49.
- [11] Imburgia M, Lerner H, Mangano F. A retrospective clinical study on 1075 lithium disilicate CAD/CAM veneers with feather-edge margins cemented on 105 patients. *Eur J Prosthodont Restor Dent*. 2021;29(1):54-63.

PARTICULARS OF CONTRIBUTORS:

1. Assistant Professor, Department of Restorative Dentistry/Operative Division, King Saud University/College of Dentistry, Riyadh, Middle, Saudi Arabia.

NAME, ADDRESS, E-MAIL ID OF THE CORRESPONDING AUTHOR:

Mohammad H Al Refeai,
Assistant Professor, Department of Restorative Dental Sciences, College of Dentistry,
King Saud University, P.O. Box 60169, Riyadh-11545, Kingdom of Saudi Arabia,
Middle, Saudi Arabia.
E-mail: malrefeai@ksu.edu.sa

PLAGIARISM CHECKING METHODS: [\[Alain H et al.\]](#)

- Plagiarism X-checker: Nov 09, 2022
- Manual Googling: Dec 07, 2022
- iThenticate Software: Dec 12, 2022 (5%)

ETYMOLOGY: Author Origin**AUTHOR DECLARATION:**

- Financial or Other Competing Interests: None
- Was informed consent obtained from the subjects involved in the study? Yes
- For any images presented appropriate consent has been obtained from the subjects. Yes

Date of Submission: **Nov 06, 2022**Date of Peer Review: **Nov 30, 2022**Date of Acceptance: **Dec 14, 2022**Date of Publishing: **Feb 01, 2023**