



## **Evaluation of the Effect of Ethanol Bark Extract of *Moringa oleifera* on Reproductive Biology of Non-pregnant Wistar Albino Rats**

**C. B. Onyewuchi<sup>1</sup>, J. S. Aprioku<sup>2\*</sup> and I. M. Siminialayi<sup>1</sup>**

<sup>1</sup>Department of Pharmacology, Faculty of Basic Medical Sciences, University of Port Harcourt, P.M.B 5323, Port Harcourt, Nigeria.

<sup>2</sup>Department of Experimental Pharmacology and Toxicology, Faculty of Pharmaceutical Sciences, University of Port Harcourt, P.M.B. 5323, Port Harcourt, Nigeria.

### **Authors' contributions**

*This work was carried out in collaboration among all authors. Authors JSA and IMS designed the study, contributed to the interpretation of the results and critically revised the manuscript. Author JSA wrote the protocol and analyzed the data. Author CBO managed the literature searches, conducted the experiments, collected the data and wrote the first draft of the manuscript. All authors read and approved the final manuscript.*

### **Article Information**

DOI: 10.9734/JOCAMR/2018/40118

#### Editor(s):

(1) Abdelkrim Berroukche, Biology Department, Faculty of Sciences, Dr. Tahar-Moulay University of Saida, Algeria.

#### Reviewers:

(1) Diego Alejandro Fano Sizgorich, Universidad Peruana Cayetano Heredia, Peru.

(2) Veeravan Lekskulchai, Srinakharinwirot University, Thailand.

(3) Alok Nahata, Malaysia.

Complete Peer review History: <http://www.sciencedomain.org/review-history/23901>

**Original Research Article**

**Received 12<sup>th</sup> January 2018**

**Accepted 23<sup>rd</sup> March 2018**

**Published 29<sup>th</sup> March 2018**

### **ABSTRACT**

**Aim:** This study was carried out to evaluate the effect of ethanol bark extract of *Moringa oleifera* (EBMO) on reproductive hormone levels and organ histology in non-pregnant Wistar rats.

**Place and Duration of Study:** This study was conducted at the Department of Pharmacology, Faculty of Basic Medical Sciences, College of Health Sciences, University of Port Harcourt, Nigeria; between March and May, 2017.

**Methodology:** The study was conducted using 40 non-pregnant adult female rats which were divided into four groups (n=10 per group), labelled as groups I, II, III and IV. Group I was the

\*Corresponding author: E-mail: [sydaprio@yahoo.com](mailto:sydaprio@yahoo.com);

control (given only distilled water), whereas rats in groups II, III and IV were orally administered EBMO (100, 200 and 400mg/kg, respectively) daily for 30 days. At the end of treatment, blood was collected for estimation of serum concentrations of progesterone, estradiol, prolactin, Luteinizing Hormone (LH) and Follicle Stimulating Hormone (FSH). The ovaries, uteri and fallopian tubes of the rats were examined for histologic changes.

**Results:** There was a non-significant decline in the concentrations of progesterone and estradiol in EBMO treated rats compared to control. No changes occurred in the serum levels of prolactin, LH and FSH after EBMO treatment. Also, there were no alterations in the histology of all three organs in EBMO treated rats when compared to control.

**Conclusion:** Results indicate that subacute administration of EBMO does not cause alterations of serum concentrations of reproductive hormones or histology of reproductive organs in non-pregnant Wistar rats.

**Keywords:** Gonadotropic hormones; moringa; ovary; progesterone; reproductive biology.

## 1. INTRODUCTION

*Moringa oleifera* Lam. is a perennial tree which has been recognized to be of medicinal value many years ago. It originated from the provinces of Agra and Oudh situated in the Himalayan Mountains but has been domesticated in several tropical and sub-tropical countries [1]. *M. oleifera* tree grows very rapidly and can grow up to 7–12 m high and 0.2–0.4 m wide in diverse climatic environments [2]. The plant is cultivated for its medicinal and dietary values [3]. Each part of *Moringa oleifera* has medicinal value and they are used as remedies for several diseases [4]. *Moringa oleifera* is very rich in nutritional and phytochemical constituents including minerals, vitamins and several antioxidant components [5,6]. Carbohydrates, glycosides, flavonoids and tannins are among phytoconstituents that have been identified in the ethanol bark extract of moringa bark [7].

The plant has been studied extensively to demonstrate its potent biological activities. The reproductive effects of *M. oleifera* have been studied in male and female animal models fairly well and reports indicate that different parts of the plant influence reproduction differently. The leaf extract had a positive influence on sperm parameters and elevated hormone levels in male rats [8]. The leaf extract also protected and remediated radiation and chemical-induced testicular damage [9]. The seed extract increased sexual activities in male rats [10]. The root extract possesses contraceptive potentials and has been shown to be teratogenic and abortifacient in rats [11,12]. The root has equally induced post-coital antifertility effect in rats and has been demonstrated to induce fetal resorptions in pregnant rats [13]. However, there is a dearth of data concerning the bark.

The aim of this study was to evaluate the effect of ethanol bark extract of *M. oleifera* on serum levels of reproductive hormones (progesterone, estradiol, prolactin, FSH and LH) and histology of reproductive organs (uterus, ovary and fallopian tube) in non-pregnant female Wistar rats.

## 2. MATERIALS AND METHODS

Fresh bark of *Moringa oleifera* was obtained from an horticulture (11 Nkakini Road, Port Harcourt, Nigeria). It was identified and authenticated by a botanist of the Department of Plant Science and Biotechnology, University of Port Harcourt, Nigeria and voucher number of UPH003/1017 was assigned to the plant specimen and deposited at the herbarium of the University. The bark was shade-dried, powdered (15.0 kg), and macerated in 95% ethanol (60 L) for 2 days and filtered with size 15 mm Watman filter paper. The filtrate was concentrated under reduced pressure using a rotary evaporator (RV0 400 SD, BOECO, Germany). Residual ethanol was evaporated in water bath at 40°C (Techmel & Techmel, USA) at 40°C to obtain dry extract (10.36 kg). Extract was preserved in refrigerator until used for experiments.

### 2.1 Animals Handling

Forty (40) female rats weighing 140–200 g were used for the experiment. The animals were fed with rodent pellets and allowed free access to water throughout the period of the experiment. They were maintained under natural lighting condition. The experiments were commenced after obtaining Ethical Clearance from the Research and Ethics Committee of our institution (UPH/CEREMAD/REC/04).

## 2.2 Design of the Study

The animals were divided into 4 groups (I, II, III and IV) each containing 10 animals. Group I received distilled water (Control), while groups II, III and IV received 100, 200 and 400 mg/kg body weight of ethanol bark extract of *M. oleifera* (EBMO), respectively. Extract was administered by oral gavage daily for 30 days. The choice of these doses was based on the median lethal dose (LD<sub>50</sub>) of the leaf extract of *M. oleifera* which is >2000 mg/kg body weight when administered orally to rats [14]. The doses selected were approximately equivalent to 5, 10 and 20% of the LD<sub>50</sub> of the plant and was similar to doses used in other studies [15]. At the end of the treatment, the rats were anesthetized with ether and then sacrificed. Blood was collected by cardiac puncture and serum levels of reproductive hormones (FSH, LH, progesterone, estradiol and prolactin) were measured using ELISA technique. Briefly, blood samples were allowed to clot and centrifuged at 3000 rpm for 15 min to separate serum. Serum was analyzed with auto-analyzer machine- microplate reader (RT-2100C, China) using AccuBind assay kits (FSH: EIA-4K4A7, LH: EIA-6K2C7, prolactin: EIA-7K1C7, progesterone: EIA-48K1H6, and estradiol: EIA-49K637; Monobind Inc., USA). Reproductive organs (ovaries, fallopian tubes and uteri) were harvested, fixed in Bouin's solution and processed for histological analysis.

## 2.3 Histological Analysis

Tissues (ovary, oviduct, and uterus) were sliced, dehydrated with ascending grades of alcohol and embedded with paraffin wax. Sections were cut (5 µm thick) with a microtome and tissues were

fixed to slides and allowed to dry. The slides were stained with hematoxylin–eosin (H & E) solution and examined under the light microscope (Optitech model RC 1321, California, USA). Photomicrographs of the tissues were taken.

## 2.4 Statistical Analysis

All data were expressed as means ± standard deviation of mean (mean±SD). Data obtained were analyzed by one–way analysis of variance (ANOVA) using SPSS version 21. Values were considered to be significant at p < 0.05.

## 3. RESULTS AND DISCUSSION

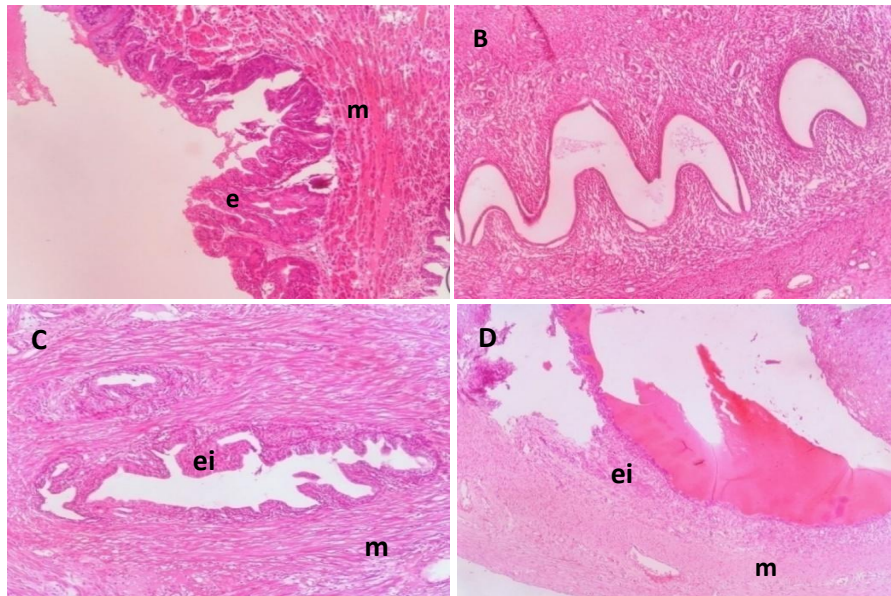
The serum levels of progesterone, estrogen, prolactin, FSH and LH in moringa extract treated rats were not different (p>0.05) compared to control (Table 1). The hormone concentrations obtained in the control rats were: progesterone (4.18±1.06 ng/ml), estrogen (300.00±69.63 ng/ml), prolactin (2.60±0.82 ng/ml), FSH (13.20±1.30 mIU/ml) and LH (8.00±1.41 mIU/ml). Although the concentrations of progesterone and estrogens in rats that received moringa extract were lower than control levels, the values were not significant (Table 1).

The histologic analyses of the uteri, ovaries and fallopian tubes of rats revealed normal histoarchitecture for the control rats (Fig.1A, 2A and 3A). Mild inflammatory cell infiltrations were observed in the uteri, ovaries and fallopian tubes of extract administered groups of rats. However, the structural outline and cellular composition of the structures were preserved in all the organs (Figs. 1, 2 and 3).

**Table 1. Effect of ethanol bark extract of *Moringa oleifera* on serum reproductive hormone levels in female Wistar rats**

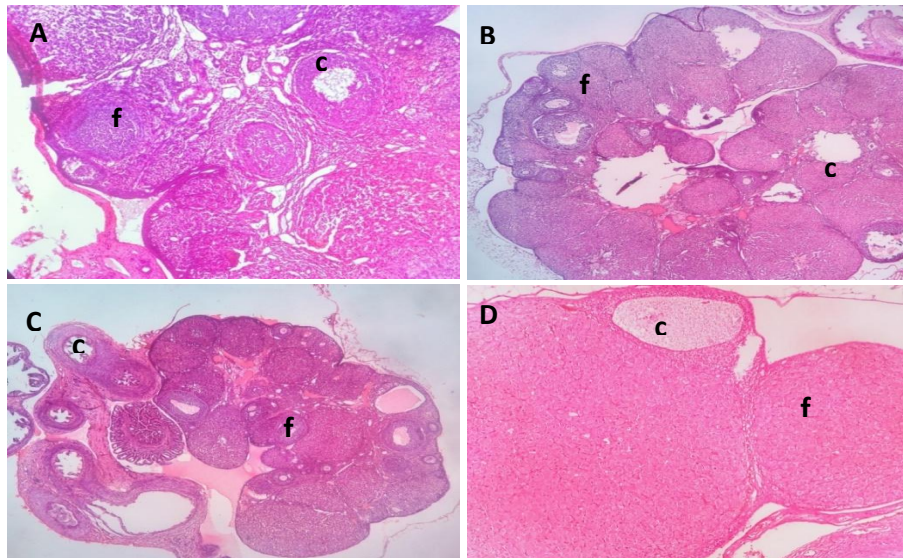
Group	Progesterone (ng/ml)	Estradiol (ng/ml)	LH (mIU/ml)	FSH (mIU/ml)	Prolactin (ng/ml)
Control	4.18±1.06	300.00±69.63	8.00±1.41	13.20±1.30	2.60±0.82
100 mg/kg	3.64±1.20	292.00±75.19	8.00±1.41	13.60±1.67	2.80±0.57
200 mg/kg	3.14±1.71	252.00±95.50	8.20±2.05	13.00±1.00	2.50±0.61
400 mg/kg	3.06±0.68	236.00±43.36	8.80±1.10	14.20±1.79	2.90±0.55
F	0.901	1.509	0.305	0.644	0.398
p-value	0.462	0.250	0.821	0.598	0.756

Values are expressed as mean±SD, n=10 per group



**Fig 1. Photomicrographs showing uteri of non-pregnant female Wistar rats treated with ethanol bark *M. oleifera* extract for 30 days. H & E stain, 400x**

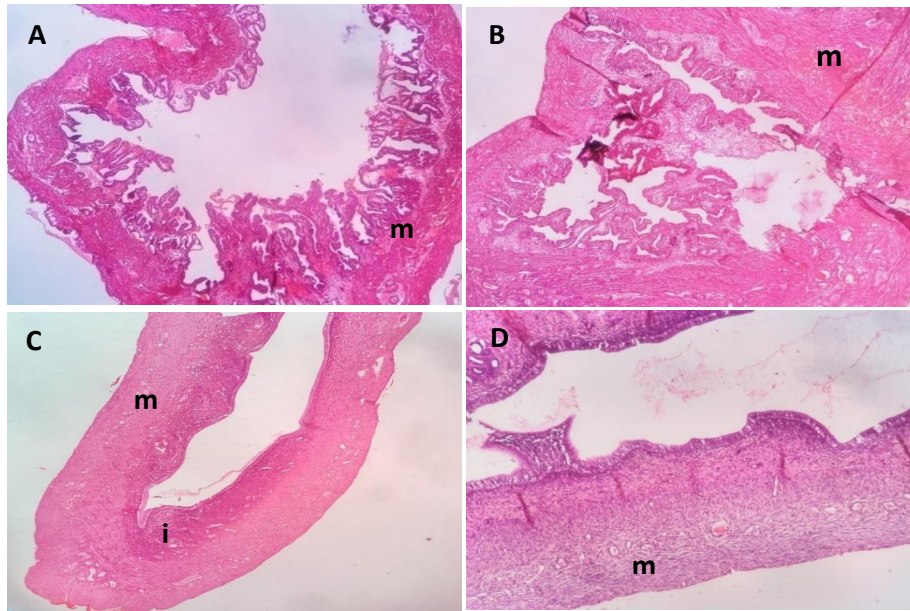
A- (Control): Section shows normal uterine tissue with straight and tubular endometrial glands and normal sized myometrium. B - (100 mg/kg): Section shows uterine tissue with normal histology, C - (200 mg/kg): Section has normal histology with few endometrial leukocytic infiltrations, D - (400 mg/kg): Section shows uterine tissue with convoluted endometrial glands with few sub-epithelial leukocytic infiltrations  
Key: e = endometrium, m = myometrium, ei = sub-endometrial inflammation



**Fig 2. Photomicrographs showing ovaries of non-pregnant female Wistar rats treated with ethanol bark *M. oleifera* extract for 30 days. H & E stain, 400x**

A - (Control): Section shows ovarian tissue composed of maturing follicles of different stages (primary and Graafian). There are several corpus lutei, B - (100 mg/kg): Section shows ovarian tissue composed of few maturing follicles of different stages (primary and Graafian). There are few corpus lutei, C - (200 mg/kg): Section shows ovarian tissue composed of maturing follicles of different stages (primary and Graafian). There are few corpus lutei, D - (400 mg/kg): Section shows ovarian tissue with maturing follicles and few corpus lutei.  
Key: c = corpus luteum, f = follicle at various stages of maturation





**Fig 3. Photomicrographs of fallopian ducts of non-pregnant female Wistar rats treated with ethanol bark *M. oleifera* extract for 30 days. H & E stain, 400 x**

*A - (Control): Section shows fibro-muscular tubal tissue lined by tall columnar epithelium with normal histology.*

*B - (100 mg/kg): Section shows fibro-muscular tube lined by columnar epithelium with no leukocytic infiltration*

*C - (200 mg/kg): Section shows fibro-muscular tube with normal epithelia and mild leukocytic infiltration.*

*D - (400 mg/kg): Section shows fibro-muscular tube with mild mucosal and muscularis leukocytic Inflammation,*

*Key: m = fibro-muscular layer, i = inflammation*

The results of the present study indicate that subacute exposure of ethanol bark extract of *M. oleifera* may have no effect on serum concentrations of progesterone and estradiol in non-pregnant rats. An earlier report concluded that the stem/bark of the plant elevated estrogen level in pregnant rats and eventually produced an abortifacient effect [16]. In another study, low progesterone has equally been described to induce abortion at certain stages of gestation, which may explain the abortifacient activity of antiprogestosterone agents like mifepristone [17]. The maintenance of normal serum levels of these hormones suggests thus that the extract may not affect ovarian activity and not be harmful to reproductive function in the non-pregnant rats. Interestingly, limited data on the effect of moringa bark on non-pregnant rats existed prior to this study. Additionally, the lack of effect on prolactin level by the extract in this study disagrees with some results that were obtained with the leaf extract in pregnant animals. Oral administration of the leaf extract increased the volume of mammary glands and serum prolactin level in rats and goats [18]. This effect was ascribed to the phytosterol content of moringa which

indirectly stimulates ductular proliferation by increasing estrogen formation. Although the major physiologic regulator of prolactin secretion is a negative feedback inhibition by dopamine, it has been suggested that progesterone may as well be a putative positive regulator of prolactin secretion [17]. The effect of the extract on progesterone thus correlated with the non-alteration of prolactin level.

In previous studies, ethanol extract of *M. oleifera* leaf increased FSH and LH levels in male albino rats [19]. From our results, there was no change in the serum levels of FSH and LH following treatment with the extract in female rats. This zero effect on gonadotropic hormones is explained by the normal estrogen and progesterone levels that was seen after extract treatment, being that the hormones are feedback regulators of gonadotropins release, particularly LH [17]. Similarly, the histology results revealed no histological changes of concern supporting the insignificant hormonal influence of the extract and indicating it may not be harmful to reproductive biology of non-pregnant rats. Although animals' menstrual cycles can influence

the outcome of this study, the consistent results obtained provide some reliability. However, future studies are necessary to establish the influence of the plant on female sex hormones in specific terms.

#### 4. CONCLUSION

This study shows that 30 days consecutive treatment with crude ethanol moringa bark extract may cause no change in serum reproductive hormone concentrations as well as reproductive organs in the non-pregnant female rats.

#### CONSENT

It is not applicable.

#### ETHICAL APPROVAL

As per international standard or university standard, written approval of Ethics Committee has been collected and preserved by the author(s).

#### COMPETING INTERESTS

Authors have declared that no competing interests exist.

#### REFERENCES

1. Dhakar RC, Maurya SD, Pooniya BK, Bairwa N, Gupta M, S. Moringa: The herbal gold to combat malnutrition. *Chronicles of Young Scientists*. 2011;2(3):119-126.
2. Egbuna C. *Moringa oleifera*- The mothers' best friend. *International Journal of Nutrition and Food Science*. 2015; 4(6):624-630.
3. Dalei J, Rao VM, Sahoo D, Rukmini M, Ray R. Review of nutritional and pharmacological potencies of *Moringa oleifera*. *European Journal of Pharmacy and Medical Research*. 2016,3(1):150-155.
4. Koul B, Chase N. *Moringa oleifera* Lam: Panacea to several maladies. *Journal of Chemical and Pharmaceutical Research*. 2015;7(6):687-707.
5. Mahmood KT, Mugal T, Haq IU. *Moringa oleifera*: A natural gift- a review. *Journal of Pharmaceutical Sciences and Research*. 2010;2(11):775-781.
6. Fakankum OA, Babayemi JO, Utiaruk JJ. Variations in the mineral composition and heavy metals content of *Moringa oleifera*. *African Journal of Environmental Science and Technology*. 2013;7(6):372-379.
7. Sholapur HPN, Patil BM. Pharmacognostic and phytochemical investigations on the bark of *Moringa oleifera* Lam. *Indian Journal of Natural Products and Resources*. 2013;4(1):96-101.
8. Novodita P, Varma MC. Effect of leaf powder on sperm count, histology of testis and epididymis of hyperglycaemic mice *Mus musculus*. *American International Journal of Research in Formal, Applied and Natural Science*. 2014;7(1):7-13.
9. Nithya R, Elango.V, Protective activity of *Moringa oleifera* leaf extract on lindane induced testicular damage in rats, *International Journal of Research Studies in Biosciences*. 2014;2(11):126-132.
10. Zade V, Dabhadkar D, Thakara V, Pare S. Effects of aqueous extract of *Moringa oleifera* seed on sexual activity of male albino Rats. *Biological Forum-An International Journal*. 2013;5(1):129-140.
11. Sethi.N, Nath .D, Shukla SC, Dyal R. Abortifacient activity of a medicinal Plant *Moringa oleifera* in rats. *Anc Sci Life*. 1988;7(3-4):172-174.
12. Das B, Talukdah AD, Choudhury MD. A few traditional medicinal plants used as antifertility agents by ethnic people of Tripura, India. *International Journal of Pharmacy and Pharmaceutical Sciences*. 2014;6(3):47-53.
13. Prakash AO, Tewari RK, Shukla S, Mathur R, Tewari KK. Post-coital antifertility effect of some medicinal plants in rats. *Indian Drugs*. 1987;25(2):40-44.
14. Adedapo AA, Mogbojuri OM, Emikpe BO. Safety evaluations of the aqueous extract of the leaves of *Moringa oleifera* in rats. *Journal of Medicinal Plants Research*. 2009;3(8):586-591.
15. Zade V, Dabhadkar D. Antifertility effects of alcoholic extract of *Moringa oleifera* stem bark on estrous cycle and estrogenic activity of female albino rat. *American Journal of Advanced Drug Delivery*. 2015;3(3):223-235.
16. Zade V, Dabhadkar D. Abortifacient efficacy of *Moringa oleifera* stem bark of female Albino rats. *World Journal of*

- Pharmaceutical Research. 2014;3(3):4666-4679.
17. Ganong EW. Review of Medical Physiology; Endocrine and Reproductive Physiology, 24<sup>th</sup> edition, Lange 2015;391–428.
18. Titi MK, Nunung N. Improvement of noodles recipe for increasing breastmilk: design of the moringa noodles. American Journal of Food Science and Technology. 2014;2(3):88-92.
19. Dafaalla MM, Hassan AW, Idris OF, Abdoun S, Modawe GA, Kabbashi AS. Effect of ethanol extract of *Moringa oleifera* leaves on fertility hormone and sperm quality of male Albino rats. World Journal of Pharmaceutical Research. 2016;5(1):1-11.

© 2018 Onyewuchi et al.; This is an Open Access article distributed under the terms of the Creative Commons Attribution License (<http://creativecommons.org/licenses/by/4.0>), which permits unrestricted use, distribution, and reproduction in any medium, provided the original work is properly cited.

*Peer-review history:*

*The peer review history for this paper can be accessed here:  
<http://www.sciencedomain.org/review-history/23901>*