



## **Does Galectin3 Immunohistochemical Marker Help in Diagnosing the Nature of Benign or Malignant Thyroid Tumor?**

**Umm-e-Farwa<sup>1</sup>, Rehana Ramzan<sup>1</sup>, Mahwish Niaz<sup>2</sup>, Hassan Salim<sup>3</sup>,  
Rabiya Fawad<sup>4</sup>, Nadia Tasawer<sup>5</sup>, Kashif Bangash<sup>6</sup>, Hassan Mumtaz<sup>7\*</sup>  
and Shahzaib Ahmad<sup>8</sup>**

<sup>1</sup>Department of Histopathology, Foundation University Medical College, Islamabad, Pakistan.

<sup>2</sup>Shifa college of medicine, Shifa Tameer-e-Millat University, Islamabad, Pakistan.

<sup>3</sup>Fauji Foundation Hospital, Rawalpindi, Pakistan.

<sup>4</sup>Department of Pathology, Quetta Institute of medical sciences, Quetta Pakistan.

<sup>5</sup>Department of Histopathology, Pakistan institute of medical sciences Islamabad, Pakistan.

<sup>6</sup>Department of Urology, KRL Hospital Islamabad, Pakistan.

<sup>7</sup>Clinical Research Center, Shifa International Hospital Islamabad, Pakistan.

<sup>8</sup>King Edward Medical University, Pakistan.

### **Authors' contributions**

*This work was carried out in collaboration among all authors. All authors read and approved the final manuscript.*

### **Article Information**

DOI: 10.9734/JAMMR/2021/v33i1931085

#### Editor(s):

(1) Dr. Emmanouil (Manolis) Magiorkinis, General Hospital for Chest Diseases "Sotiria", Greece.

#### Reviewers:

(1) Shaimaa Mahmoud Mohamed Saleh, Assiut University, Egypt.

(2) Martha Lilia Tena-Suck, National Institute of Neurology and Neurosurgery, Mexico.

Complete Peer review History: <https://www.sdiarticle4.com/review-history/73568>

**Original Research Article**

**Received 30 June 2021  
Accepted 10 September 2021  
Published 10 September 2021**

### **ABSTRACT**

**Introduction:** Galectin-3 has been reported quite accurate to detect or exclude malignancy in nodules with prior indeterminate Fine Needle Aspiration Cytology and per operative findings. Keeping this fact in mind, Galectin-3 can have a pivotal role in separating benign from the malignant thyroid neoplasms.

We aim to determine the frequency and intensity of Galectin-3 immunohistochemical expression among benign and malignant thyroid neoplasms confirmed on histopathology.

**Materials and Methods:** We studied 78 thyroid specimens diagnosed with thyroid neoplasms on histopathology. Out of these 39 were benign cases (follicular adenoma and hurthle cell adenoma) and 39 were malignant cases (papillary thyroid carcinomas, follicular carcinoma, medullary carcinoma and poorly differentiated carcinoma). Each specimen was examined grossly and microscopically and checked for immunohistochemical staining pattern of Galectin-3 under the microscope.

**Results:** Age range in this study was from 15 to 65 years with mean age of  $44.97 \pm 10.78$  years. Out of these 78 patients, 17 (21.79%) were male and 61 (78.21%) were female with male to female ratio of 1:3.6. Frequency of positive Galectin-3 immuno histochemical expression among thyroid neoplasms was found in 32 (41.03%) cases with Galectin-3 showing positive staining in 21 (53.85%) of all malignant and 11 (28.21%) of all benign cases. Among the malignant neoplasms, positivity was seen most frequently in papillary thyroid carcinomas as compared to the other malignancies.

**Conclusion:** This study concluded that positive Galectin-3 immunohistochemical expression is more in malignant thyroid neoplasms (53.85%) as compare to the benign lesions (28.21%). Therefore, we recommend that this marker cannot be used alone for the routine diagnosis of malignant lesions as it has shown less sensitivity and specificity. Moreover it also has shown no significant role in differentiating between the benign and the malignant thyroid neoplasms.

*Keywords: Thyroid cancer; Immunohistochemical expression; Galectin-3; malignant; benign.*

## 1. INTRODUCTION

Thyroid gland is an important part of the endocrine system located at the base of the neck. It is chiefly composed of two types of cells, follicular and parafollicular cells. The follicular cells make thyroxine, which has important functional impacts on various systems and general metabolism. The parafollicular cells, also known as C cells arise from the neural crest and are involved in the calcitonin production, which has vital role in maintaining calcium homeostasis [1].

Thyroid neoplasms including both benign and malignant lesions are common entities encountered in daily clinical practice. Most of the lesions (95%) arise from the follicular epithelial cells of the thyroid gland [2].

Thyroid cancer is the most common among the endocrine tumors and its incidence has been increasing in the last three decades [3]. An estimated mortality rate of thyroid cancer is 0.5 to 10 cases per 100,000. The annual male and female percentage is 6.3% and 7.1% for white population, 4.3% and 8.4% for blacks and for Asian population patients it is 3.4% and 6.4% respectively [3]. These tumors can clinically present as a solitary nodule along with the normal thyroid gland or as a dominant nodule in the background of a multinodular goiter. 5% of the solitary thyroid nodules are found to be neoplastic [4].

In Pakistan, thyroid neoplasms are common especially in the northern areas, which are mainly attributable to the iodine deficiency or excess. Thyroid cancer accounts for 1.2% of all the malignancies diagnosed in our country with the papillary thyroid carcinoma being most common. The female to male ratio in Pakistan is reported as 2.2:1 [5].

Patients can present with both the features of hyper and hypothyroidism in both benign and malignant lesion. This makes it clinically difficult to diagnose the exact underlying cause. Here comes the role of histopathology, which can correctly diagnose the lesion, but there are some neoplasms that have very confusing morphological details and these cannot be exactly categorized into benign or malignant, only on the basis of histopathology. This scenario is mostly seen in the follicular and the Hurthle cell neoplasms. The gross appearance and the microscopic details are perplexing for a pathologist. Moreover, the cytological details are also much overlapping in various benign versus malignant lesions [2].

The final diagnosis of the lesion being benign and malignant has profound effects on the clinical outcome and prognosis of the patient. Several articles have reported the significance of immune histochemical markers to solve this problem. Galectin-3, p63 and Ki67 have been reported quite accurate to detect or exclude malignancy in nodules with prior indeterminate

Fine Needle Aspiration Cytology and per operative findings [6].

In this study, role of Galectin-3 will be quantified to differentiate and classify the thyroid lesions into benign and malignant categories. Galectin-3 belongs to the family of lectins. Galectin-3 is synthesized in both the nucleus and cytoplasm, and also expressed at the cell surface. It is also found extracellularly in the general circulation. Galectin-3 specifically binds to the beta galactoside containing intracellular, extracellular and cell surface associated glycol conjugates so it is over expressed in oncogenic pathology of thyroid [7-8].

In Pakistan, limited data is available regarding the role of galectin-3 as a diagnostic tool to differentiate malignant thyroid neoplasms from benign lesions. So, this study can have beneficial effects in the diagnostics and further treatment of such lesions.

## 2. MATERIALS AND METHODS

This descriptive, cross-sectional study was conducted from 5th November 2017 to 4th May 2018 in the Department of Histopathology, Foundation University Medical College, Islamabad Campus & Department of Surgery, Fauji Foundation Hospital, Rawalpindi. There was a total of 78 thyroid specimens included in this study (39 benign and 39 malignant neoplasms). All of these patients were operated at the Department of Surgery, Fauji Foundation Hospital Rawalpindi during a period of six months from 5<sup>th</sup> November 2017 to 4<sup>th</sup> May 2018. The specimens were processed in the department of Histopathology, Foundation University Medical College Islamabad. The benign conditions included Follicular adenoma and Hurthle cell adenoma. The malignant conditions included Papillary thyroid carcinoma (both classic type and follicular variant), Follicular thyroid carcinoma, Medullary thyroid carcinoma and poorly differentiated carcinoma.

The hospital ethical committee granted the approval for data collection. The data included patient's demographic details, clinical presentation, previous laboratory test record and clinical suspicion. The specimens were examined both grossly and microscopically in the laboratory. The thyroid specimens were fixed in 10% formalin and were sliced properly. The representative sections were processed in the tissue processor (SAKURA TISSUE TEK-R

TEC5 MODEL 220-240) for the paraffin sectioning. After this step, 4-5µm thick sections were cut using rotatory microtome (SAKURA ACCU-CUT MODEL SRM 200 CW). Hematoxylin and eosin stain (H&E) was used for staining the slides and get them ready to see under the microscope.

For the immunohistochemistry, representative histological sections of the thyroid neoplasm were used. The sections were deparaffinised by xylene and then were rehydrated by ethanol. Trisodium citrate buffer (pH 6.0 to 6.2) was used for the antigen retrieval. When the slides came back to room temperature, endogenous peroxidase activity was blocked by 0.6% H<sub>2</sub>O<sub>2</sub>. After this step lyophilized mouse monoclonal Galectin-3 antibody in the dilution of 1:100 was applied for an hour. Washing was done with tris- buffered saline (TBS). Then for 20 minutes super enhancer was added. Polymer horseradish peroxidase (HRP) was applied for 30 minutes as a secondary antibody and washing was done again with TBS. Subsequently Diamine Benzidine (DAB) chromogen was applied for 5 minutes. Mayer's Haematoxylin was used for counter staining followed by clearing and mounting. Positive and negative controls were also applied.

Two consultant histopathologists examined the H&E stain and immunohistochemical marker (Galectin-3) under the Olympus light microscope. The sections with the best staining were selected for examination and reported likewise. Morphology and staining was noted and grading of Galectin-3 was done by Weber KB et al and Hermann ME et al guidelines. The intensity and distribution of Galectin-3 staining (cytoplasmic) on a scale of 0 to 3 was done as follows:

- 0 No staining
- 1+ Weak/slight staining
- 2+ Moderate staining
- 3+ Intense staining

The proportion of stained cells was interpreted as;

- 1+ < 5% of cells
- 2+ 5% to 50% of cells
- 3+ >50% of cells

The lesions with the particular cytoplasmic staining of more than 5% of the tumor cells was taken as positive for Galectin-3 regardless of its intensity.

### 3. RESULTS

Age range in this study was from 15 to 65 years with mean age of  $44.97 \pm 10.78$  years as shown in Table- 1. Out of these 78 patients, 61 (78.21%) were female and 17 (21.79%) were male with female to male ratio of 3.6:1 (Fig. 1). On the basis of histopathological diagnosis half (39) cases belonged to benign neoplasms and other half (39) were diagnosed as malignant neoplasms as shown in Fig. 2.

Frequency of positive Galectin-3 immunohistochemical expression among thyroid neoplasms was found in 32 out of 78 (41.03%) cases while 46 out of total 78 (58.97%) were showing negative galectin-3 staining (Fig. 3).

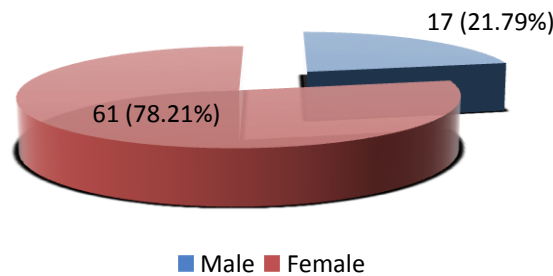
A detailed look at the further breakdown of galectin-3 staining among benign neoplasms reveal that 11(28.1%) among 39 benign cases were positive for the stain. For the malignant neoplasms, total 21(53.85%) among 39 cases were positive. On the other side 28(71.79%) benign cases and 18(46.15%) malignant cases

showed negative galectin-3 staining. The p-value calculated was 0.021 which is not significant (Table 2).

The Stratification of Galectin-3 immunohistochemical expression with respect to age groups showed total 27 cases within the age range of 15- 40 years out of which 10 cases were positive. Total 51 cases belonged to the age range of 41- 65 years out of which 22 showed positive galectin-3 staining. The p-value calculated was 0.602 which is again insignificant (Table 3).

Similarly Table 4 shows the breakdown of the cases according to gender. Total 8 out of 17 cases among male patients were positive for Galectin-3 and 24 out of 61 cases of female patients were showing the positive staining. The p-value calculated was 0.567 which is again insignificant.

The breakdown of Galectin-3 positivity in the various histological types of malignant and benign thyroid neoplasms is also shown in Figs 4,5 respectively.



**Fig. 1. Distribution of patients according to Gender (n=78)**

**Table 1. Age distribution of patients (n=78), having Mean  $\pm$  SD =  $44.97 \pm 10.78$  years**

Age (in years)	No. of Patients	%age
15-40	27	34.62
41-65	51	65.38
Total	78	100.0

**Table 2. Stratification of Galectin-3 immunohistochemical expression among benign and malignant thyroid neoplasms**

	Galectin-3 immunohistochemical expression		p-value
	Positive	Negative	
Benign	11 (28.21%)	28 (71.79%)	0.021
Malignant	21 (53.85%)	18 (46.15%)	

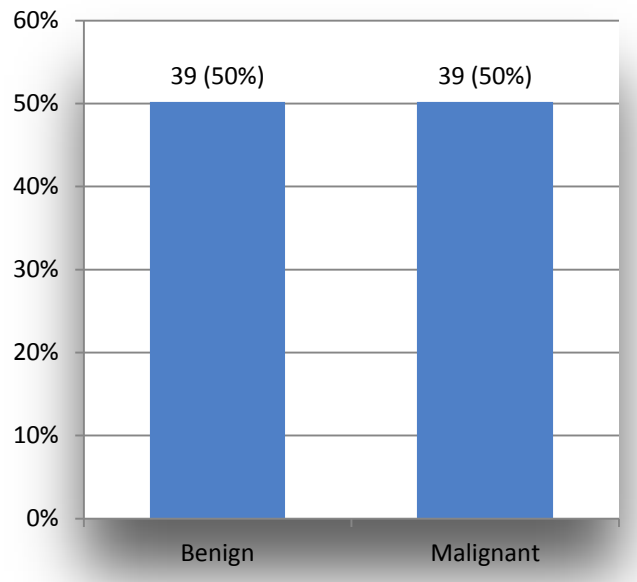


Fig. 2. Distribution of patients according to histopathological features (n=78)

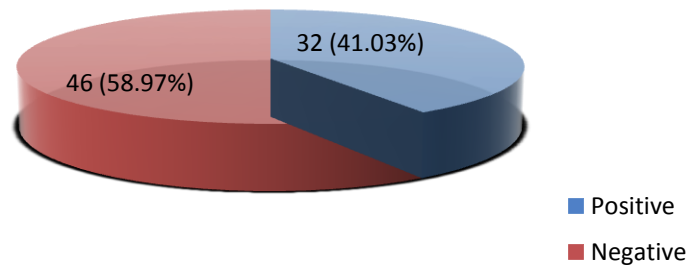


Fig. 3. Frequency of Galectin-3 immunohistochemical expression among thyroid neoplasms confirmed on histopathology (n=78)

Table 3. Stratification of Galectin-3 immunohistochemical expression with respect to age groups

	Galectin-3 immunohistochemical expression		p-value
	Positive	Negative	
15-40 years	10	17	0.602
41-65 years	22	29	

Table 4. Stratification of Galectin-3 immunohistochemical expression with respect to gender

	Galectin-3 immunohistochemical expression		p-value
	Positive	Negative	
Male	08	09	0.567
Female	24	37	

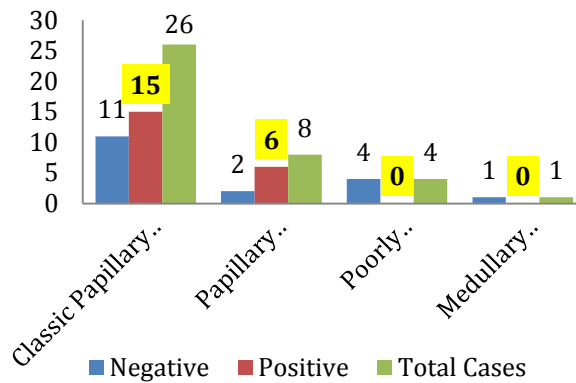


Fig. 4. Galectin-3 staining in various histological types of Thyroid carcinomas

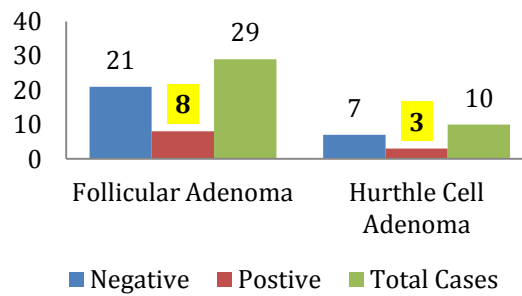


Fig. 5. Galectin-3 staining in various histological types of Thyroid adenomas

#### 4. DISCUSSION

Recent studies pointed to some immunohistochemical markers questioning their diagnostic and prognostic utility in different thyroid tumors. Among these, they have deduced Galectin-3 to be a promising marker. Galectin-3 is a unique member of an ancient lectin family [9]. Galectin-3 is also expressed in a variety of normal tissue and tumors [10]. Malignant transformation of thyroid cells has been found to be accompanied with intense nuclear [10] localization of galectin-3 in tumors [11]. Galectin-3 expression recently emerged as a potential diagnostic and prognostic marker of some cancers [12]. Although galectin-3 is not a universal and unambiguous marker of thyroid cancers, it could be a helpful parameter in diagnosis of these tumors as well as possible potential therapeutic target [13-16].

In 2015 a study was conducted in India regarding the staining pattern of Galectin-3 in thyroid neoplasms. The results showed 86% sensitivity and 85% specificity, with Galectin-3 showing positive staining in 87% of all malignant

and 15% of all benign cases [2] In 2016, another study was conducted in Italy to check the diagnostic accuracy of the various immunohistochemical stains and they found galectin-3 to be 84.2% sensitive and 94.5% specific in detecting the thyroid neoplasms [7].

In contrast, our study shows less frequency of positive Galectin-3 immunohistochemical expression among thyroid neoplasms i.e. total 32 (41.03%) cases with Galectin-3 showing positive staining in 53.85% of all malignant and 28.21% of all benign cases. In 2002 a study was conducted regarding the staining pattern of Galectin-3 in thyroid neoplasms. The results showed high frequency of staining in papillary thyroid carcinomas only and no significant staining in the other type of carcinomas. Moreover, it also showed positive results in follicular adenomas which made them conclude that galectin-3 is not a sensitive marker if used alone [8] Our study also shows the same results.

The latest meta-analysis indicated that galectin-3 may be a potentially useful immuno-marker to distinguish between patients with papillary thyroid carcinoma (PTC) and patients without

PTC. In addition, PTC patients with positive expression of galectin-3 were prone to lymph node metastasis [17]. Our study also gives us the result that although galectin-3 is sensitive for detecting papillary thyroid carcinomas but it is not much sensitive in detecting other carcinomas from benign lesions (adenomas) as shown in Figs 4,5.

Another previous study also support that the use of galectin-3, HBME-1, and cytokeratin-19 may provide significant contributions in the differential diagnosis of malignant thyroid tumors, although focal galectin-3, HBME-1, and cytokeratin-19 expression may be encountered in benign lesions. It has also concluded that cytokeratin-19 alone and its combinations with other markers were more sensitive in accurate diagnosis of papillary carcinoma than the other combinations. Also these Immunohistochemical markers alone cannot be used to differentiate between benign and malignant lesions [18].

Another important point which was noted in this study was that the carcinomas showing positive galectin-3 gave mostly focal positivity rather than the diffuse strong positivity in comparison to the results of the study done by Manivannan et al [18]. That study, which was done in 2012, demonstrated that galectin-3 staining pattern is significant in differentiating benign from malignant follicular neoplasms as well as follicular variant of papillary thyroid carcinoma. Diffuse positivity for galectin-3 was associated with malignant thyroid follicular neoplasms while focal weak positivity favours adenomas. On the other hand, previous study have demonstrated that there was no marked difference in the staining intensity for intra cytoplasmatic or intranuclear expression of galectin-3 in benign and malignant thyroid neoplasms [19].

The increased expression levels of galectin-3 on Thin-Prep fine needle aspiration cytology were associated with hypertrophy and cellular hyperproliferation, pathophysiological situations that are common to adenomas and thyroid carcinomas [20-21]. A previous study compared glypican-3 (a member of the glypican family of heparan-sulfate proteoglycans bound to the plasma membrane) with galectin-3 and demonstrated that galectin-3 was more sensitive in diagnosing thyroid carcinoma; however, it was less specific in discriminating follicular-patterned neoplasm [22]. Besides tissue expression, the preoperative serum galectin-3 level had diagnostic value, as it was significantly higher in the cancer patients than in the control subjects

[23]. Our study doesn't cover this aspect of Galectin-3 role so further studies with larger case numbers can be done to confirm it.

Galectin-3 is also used in combination with other biomarkers for a differential diagnosis of thyroid lesions. The most commonly combined biomarkers are Hector Battifora mesothelial epitope-1 (HBME-1) and cytokeratin-19 [24-27]. However galectin-3 may not be used as single discriminators between follicular thyroid adenoma and carcinoma [24-27]. Some studies show that galectin-3 and HBME-1 have an excellent sensitivity and specificity for malignant thyroid lesions (100 and 89.1%, respectively) [26]. Despite core needle biopsies leading to the diagnosis of the majority of thyroid nodules, the accuracy is increased by also observing the galectin-3, cytokeratin-19 and HBME-1 panels, indicating their additional diagnostic value when combined with routine histology and not when used alone [24-27]. It was also reported that galectin 3, cluster of differentiation (CD) and, to an extent, HBME-1, are useful immunocytochemical parameters with the potential to support the fine needle aspiration cytology diagnosis of PTC, particularly in situations where the differential diagnoses is complicated [28].

Studies have noted variable Galectin-3 expression in poorly differentiated thyroid cancers also [29]. However, in majority of cases (75% to 100% of reported cases) of anaplastic thyroid carcinoma, Galectin-3 positivity was identified suggesting that differentiated thyroid carcinoma can progress or undergo anaplastic transformation [26,29]. In the present study and study by Herrmann et al., small number of cases of MTC and poorly differentiated carcinoma are reported with inconsistent Galectin-3 expression, making diagnostic application of Galectin-3 in these rare histological subgroups unlikely [30].

Zhu et al. studied CK-19, RET, Galectin-3 and HBME-1 expression in papillary thyroid carcinoma and found that expression in papillary thyroid carcinoma was higher than that in benign disease cases, but they concluded that, these were not specific markers for papillary thyroid carcinoma [31].

## 5. CONCLUSION

This study concluded that Galectin-3 immunohistochemical expression is seen among both malignant and benign thyroid neoplasms

although more in malignant ones. So, it cannot be used alone for the routine diagnosis of malignant thyroid lesions as it shows less sensitivity and specificity. It also has expressed limited role in differentiating between the benign and the malignant thyroid neoplasms.

## DISCLAIMER

Authors have declared that no competing interests exist. The products used for this research are commonly and predominantly used products in our area of research and country. There is absolutely no conflict of interest between the authors and producers of the products because we do not intend to use these products as an avenue for any litigation but for the advancement of knowledge. Also, the research was not funded by the producing company rather it was funded by personal efforts of the authors.

## ETHICAL APPROVAL

As per international standard or university standard written ethical approval has been collected and preserved by the authors.

## CONSENT

As per international standard or university standard, patients' written consent has been collected and preserved by the authors.

## COMPETING INTERESTS

Authors have declared that no competing interests exist.

## REFERENCES

1. Braverman LE, Cooper D. Werner & Ingbar's The Thyroid: A Fundamental and Clinical Text. 10<sup>th</sup> ed. Philadelphia: Lippincott Williams & Wilkins. 2012;10.
2. Sumana BS, ShaShidhar S, Shivarudrappa AS. Galectin-3 Immunohistochemical Expression in Thyroid Neoplasms: Journal of Clinical and Diagnostic Research. 2015;9:EC07.
3. Pellegriti G, Frasca F, Regalbuto C, Squatrito S, Vigneri R. Worldwide Increasing Incidence of Thyroid Cancer: Update on Epidemiology and Risk Factors. Journal of Cancer Epidemiology; 2013.
4. Dwivedi SS, Khandeparkar SG, Joshi AR, Kulkarni MM, Bhayekar P, Jadhav A, et al. Study of Immunohistochemical Markers (CK-19, CD-56, Ki-67, p53) in Differentiating Benign and Malignant Solitary Thyroid Nodules with Special Reference to Papillary Thyroid Carcinomas. Journal of Clinical and Diagnostic Research. 2016;10:EC14-9.
5. Asif F, Ahmad MR, Majid A. Risk Factors for Thyroid Cancer in Females Using a Logit Model in Lahore, Pakistan. Asian Pacific Journal of Cancer Prevention. 2015;16:6243-7.
6. Fortuna-Costa A, Gomes AM, Kozlowski EO, Stelling MP, Pavão MS. Extracellular Galectin-3 in Tumor Progression and Metastasis. FrontOncol. 2014;4:138.
7. Trimboli P, Guidobaldi L, Amendola S, Nasrollah N, Romanelli F, Attanasio D, et al. Galectin-3 and HBME-1 Improve the Accuracy of Core Biopsy in Indeterminate Thyroid Nodules. Endocrine. 2016;52:39-45.
8. Fukumori T, Kanayama H, Raz A. The Role of Galectin-3 in Cancer Drug Resistance. Drug Resistance Updates. 2007;10:101-8.
9. Hirabayashi J, Kasai K. The Family of Metazoan Metal-Independent Beta-Galactoside-Binding Lectins: Structure, Function and Molecular Evolution. Glycobiology. 1993;3:297-304.
10. Dumic J, Dabelic S, Flogel M. Galectin-3: An Open-Ended Story. Biochimica et Biophysica Acta. 2006;1760:616-35.
11. Paron I, Scaloni A, Pines A, Bachi A, Liu FT, Puppini C, Pandolfi M, Ledda L, Di Loreto C, Damante G et al. Nuclear Localization of Galectin-3 in Transformed Thyroid Cells: A Role in Transcriptional Regulation. Biochemical and Biophysical Research Communications. 2003;302: 545-53.
12. Danguy A, Camby I, Kiss R. Galectins and Cancer. Biochimica et Biophysica Acta. 2002;1572:285-93.
13. Van den Brule F, Califice S, Castronovo V. Expression of Galectins in Cancer: A Critical Review. Glycoconjugate Journal. 2004;19:537-42.
14. Johnson KD, Glinskii OV, Mossine VV, Turk JR, Mawhinney TP, Anthony DC, et al. Galectin-3 As a Potential Therapeutic Target in Tumors Arising from Malignant Endothelia. Neoplasia. 2007;9:662-70.
15. Sawangareetrakul P, Srisomsap C, Chokchaichamnankit D, Svasti J. Galectin-3 Expression in Human Papillary Thyroid



- Carcinoma. *Cancer Genomics & Proteomics*. 2008;5:117- 22.
16. Nangia-Makker P, Nakahara S, Hogan V, Raz A. Galectin-3 in Apoptosis, a Novel Therapeutic Target. *Journal of Bioenergetics and Biomembranes*. 2007;1: 79- 84.
  17. Tang W, Huang C, Tang C, Xu J, Wang H. Galectin-3 may serve as a Potential Marker for Diagnosis and Prognosis in Papillary Thyroid Carcinoma: A Meta-Analysis. *Onco Targets and Therapy*. 2016;9:455–60.
  18. Manivannan P, Siddaraju N, Jatiya L, Verma SK. Role of Pro-Angiogenic Marker Galectin-3 in Follicular Neoplasms of Thyroid. *Indian Journal of Biochemistry and Biophysics*. 2012;49:392–4.
  19. Sumana BS, Shashidhar S, Shivarudrappa AS. Galectin-3 Immunohistochemical Expression in Thyroid Neoplasms. *Journal of Clinical and Diagnostic Research*.. 2015;9:EC07–11.
  20. Papale F, Cafiero G, Grimaldi A, Marino G, Rosso F, Mian C, Barollo S, Pennelli G, Sorrenti S, De Antoni E, Barbarisi A. Galectin-3 Expression in Thyroid Fine Needle Cytology (t-FNAC) Uncertain Cases: Validation of Molecular Markers and Technology Innovation. *Journal of Cellular Physiology*. 2013;228:968–74.
  21. Salajegheh A, Dolan-Evans E, Sullivan E, Irani S, Rahman MA, Vosgha H, Gopalan V, Smith RA, Lam AK. The Expression Profiles of the Galectin Gene Family in Primary and Metastatic Papillary Thyroid Carcinoma with Particular Emphasis on Galectin-1 and Galectin-3 Expression. *Experimental and Molecular Pathology*. 2014;96:212–8.
  22. Al-Sharaky DR, Younes SF. Sensitivity and Specificity of Galectin-3 and Glypican-3 in Follicular-Patterned and other Thyroid Neoplasms. *Journal of Clinical and Diagnostic Research*. 2016;10:EC06–10.
  23. Yilmaz E, Karsidag T, Tatar C, Tüzün S. Serum Galectin-3: Diagnostic Value for Papillary Thyroid Carcinoma. *Ulus Cerrahi Derg*. 2015;31:192–6.
  24. Paunovic I, Isic T, Havelka M, Tatic S, Cvejic D, Savin S. Combined Immunohistochemistry for Thyroid Peroxidase, Galectin-3, CK19 and HBME-1 in Differential Diagnosis of Thyroid Tumors. *APMIS*. 2012;120:368–79.
  25. Abd-El Raouf SM, Ibrahim TR. Immunohistochemical Expression of HBME-1 and Galectin-3 in the Differential Diagnosis of Follicular-Derived Thyroid Nodules. *Pathology, Research and Practice*. 2014;210:971–8.
  26. Trimboli P, Guidobaldi L, Amendola S, Nasrollah N, Romanelli F, Attanasio D, et al. Galectin-3 and HBME-1 Improve the Accuracy of Core Biopsy in Indeterminate Thyroid Nodules. *Endocrine*. 2016;52:39–45.
  27. Durry MF, Miskad UA, Leiwakabessy WN, Cangara MH. Diagnostic Value of Galectin-3 and Hector Battifora Mesothelial Epitope (HBME)-1 as a Marker for Malignancy in the Diagnosis of Thyroid Lesions. *Pathology International*. 2016;48:S122–3.
  28. Das DK, Al-Waheeb SK, George SS, Haji BI, Mallik MK. Contribution of Immunocytochemical Stainings for galectin-3, CD44, and HBME1 to Fine-Needle Aspiration Cytology Diagnosis of Papillary Thyroid Carcinoma. *Diagn Cytopathol*. 2014;42:498–505.
  29. Bartolazzi A, Gasbarri A, Papotti M, Bussolati G, Lucante T, Khan A, et al. Application of an Immunodiagnostic Method for Improving Preoperative Diagnosis of Nodular Thyroid Lesions. *Lancet*. 2001;357:1644–50.
  30. Herrmann ME, LiVolsi VA, Pasha TL, Roberts SA, Wojcik EM, Baloch ZW. Immunohistochemical Expression of Galectin-3 in Benign and Malignant Thyroid Lesions. *Archives of Pathology & Laboratory Medicine*. 2002;126:710–13.
  31. Zhu X, Sun T, Lu H, Zhou X, Lu Y, Cai X, Zhu X. Diagnostic Significance of CK19, RET, galectin-3 and HBME-1 Expression for Papillary Thyroid Carcinoma. *Journal of Clinical Pathology*. 2010;63:786-9.

© 2021 Farwa et al.; This is an Open Access article distributed under the terms of the Creative Commons Attribution License (<http://creativecommons.org/licenses/by/4.0>), which permits unrestricted use, distribution, and reproduction in any medium, provided the original work is properly cited.

Peer-review history:

The peer review history for this paper can be accessed here:  
<https://www.sdiarticle4.com/review-history/73568>