



Unifocal Langerhans Cell Histiocytosis Presenting as Spontaneous Pneumothorax

**Muhammad Khurram¹, Saima Ambreen¹, Muhammad A. Shafiq^{2,3},
Muhammad Naveed Shahzad¹, Faiqa Zikria¹, Sarah Yousaf Shah⁴
and Hassan Mumtaz^{5,6,7*}**

¹Holy Family Hospital, Rawalpindi, Pakistan.

²California Institute of Behavioral Neurosciences and Psychology, Fairfield, USA.

³Rawalpindi Medical University, Islamabad, Pakistan.

⁴Shifa International Hospital Islamabad, Islamabad, Pakistan.

⁵Clinical Research Center, Shifa International Hospital Islamabad, Islamabad, Pakistan.

⁶General Medicine, Surrey Docks Health Center, London, GBR,

⁷Urology, Guys & St Thomas Hospital, London, GBR.

Authors' contributions

This work was carried out in collaboration among all authors. All authors read and approved the final manuscript.

Article Information

DOI: 10.9734/JAMMR/2021/v33i1931084

Editor(s):

(1) Dr. Ashish Anand, University of Mississippi Medical Center, USA.

Reviewers:

(1) Nikhil Madan, Newark Beth Israel Medical Center, USA.

(2) Aravind Varma Datla, Dr. NTR University of Health Sciences, India.

Complete Peer review History: <https://www.sdiarticle4.com/review-history/73587>

Case study

Received 29 June 2021

Accepted 09 September 2021

Published 10 September 2021

ABSTRACT

Langerhans cell is a rare disease affecting the lungs which has a 10 years survival chance having a prognosis of 85%. It is often linked with smoking. We discuss here the correct stepwise approach towards its diagnosis

Presenting a 28-year-old male smoker with a history of shortness of breath for 2 months which worsened progressively. His chest X-ray showed spontaneous pneumothorax with greater severity towards the right side. HRCT revealed multiple innumerable well-defined cystic lesions of variable sizes in bilateral lung fields, more prominent in upper lobes. A negative suction Pleur-evac was advised but the patient refused it and eventually pleurodesis using bleomycin was done to prevent pneumothorax in the future.

Pleurodesis can improve the symptoms of 88 percent of patients without causing any significant complications. Although pleurodesis does not have any effect on patients' survival, it has a positive impact on their lives continuously by enhancing the quality of life.

Keywords: Pleurodesis; cystic; lung disease; diagnosis; chest auscultation.

1. INTRODUCTION

Cystic lung disease is a broad term that encompasses a group of disorders involving multiple cysts. Park et al define cysts as air-filled lucencies or low attenuation areas bordered by a thin wall, usually <2 mm [1-2]. HRCT is commonly used as an imaging modality and making a correct diagnosis can be a challenging task for radiologists [3].

PLCH has a good prognosis with 85% of the cases having a 10 years survival chance [4]. Smoking cessation has proven to limit disease progression in a significant number of patients [5]. Nevertheless, correlating clinical and radiological findings can help reach a specific diagnosis without having to go for an invasive intervention like open lung biopsy [6].

We discuss here a rare disease like PLCH and a correct step-wise approach towards its diagnosis.

2. CASE PRESENTATION

A 28-year-old male smoker was admitted with a history of shortness of breath for 2 months that was gradual in onset but worsened progressively. In addition, it was positional and relieved temporarily on bending forward. He was put on 2 L oxygen to maintain his saturation. He was vitally stable **having 86 beats/min, 120/80 BP, 99% SPO2 & 130 mg/dl bsr.**

Chest auscultation revealed decreased air entry at the right lung base. In light of the above findings, a chest X-ray was performed as given below (Fig. 1) that showed spontaneous pneumothorax with greater severity towards the right side. Percussion note was hyper resonant. Patient was a smoker and refused for BAL. Hence, a chest tube was placed as shown in (Fig. 2) and the lung was fully expanded (Fig. 3).

Apart from the routine blood tests as shown in (Table 1), his arterial blood gases were also ordered that came out normal.

Subsequently, he underwent HRCT to rule out any lung pathology which revealed multiple

innumerable well-defined cystic lesions of variable sizes in bilateral lung fields as shown in (Fig. 4), more prominent in upper lobes, suggestive of cystic lung disease. Keeping in mind the findings, we closely followed an algorithm given on update [7]. According to this, the strong association of pulmonary Langerhans histiocytosis with young smokers and the features of bizarre-shaped and irregular cysts with upper lobe predominance were strongly consistent with our case.

On the contrary, **Lymphangioleiomyomatosis (LAM)** is more common in females, shows uniform cysts along with extrapulmonary manifestations involving skin and kidneys, therefore, it was ruled out. Apart from that Birt-Hogg-Dubé syndrome, mainly involves lower lung zones and lymphocyte interstitial pneumonia is autoimmune that appears as ground-glass opacities with a small number of cysts on imaging. Hence, excluding them both as our possible diagnosis as well. During his stay, a negative suction Pleur-evac was advised but the patient refused it, and eventually, pleurodesis using bleomycin was done to prevent pneumothorax in the future. Additionally, the patient was given IV fluids, antibiotics cover and counseled regarding smoking cessation.

3. DISCUSSION

Pulmonary Langerhans Histiocytosis is a rare disorder that commonly affects young males, especially smokers of less than 40 years of age group. It has a wide range of clinical presentations including pneumothorax in 15% of the cases, shortness of breath, weight loss, rash, and diabetes insipidus [1]. Our patient was a typical case of the disease clinically, as he was a young smoker and presented with spontaneous bilateral pneumothorax.

Pathophysiologically, in PLCH Langerhans cells, undergo mutations in BRAF, NRAS, KRAS, and MAP 2K1 genes and invade the lung parenchyma [4]. It begins as nodules which progress to become cavitations that eventually turn into cysts [1]. 50% of the cases have been

noted to have an obstructive pattern on pulmonary function tests [8].

HRCT shows a typical pattern of bizarre-shaped cysts along with nodules in the upper and middle lobes of the lungs [1-2]. There are several other diseases with a similar presentation clinically and radiologically, the most important of them are lymphangiomyomatosis, Birt Hogg Dube syndrome, and Lymphocytic interstitial pneumonia [2]. Due to this reason, getting to a definitive diagnosis can be quite a challenge [6]. The first step towards making a diagnosis involves differentiating true cysts from other similar entities like bulla, bronchiectasis, honeycombing, and pneumatoceles. In comparison to cysts, bulla and honeycombing

have a subpleural distribution, spermatoceles are associated with pneumonia or trauma, whereas emphysema has a characteristic centrilobular distribution with a central core vessel [3]. *The next important step is to recognize the distribution pattern along with the size, shape, and number of cysts on HRCT. In LAM, cysts are diffuse, bilateral, and uniform in size. In contrast, cysts in PLCH are associated with ill-defined nodules, predominantly in the upper part of the lungs, not involving the Costophrenic angles. On the other hand, if cysts are lentiform shaped with thin walls and are mainly present in the lower lobe, BHD should be considered, or if ground-glass opacities are observed associated with nodules and thin-walled cysts in the subpleural region, LIP is more likely [7].

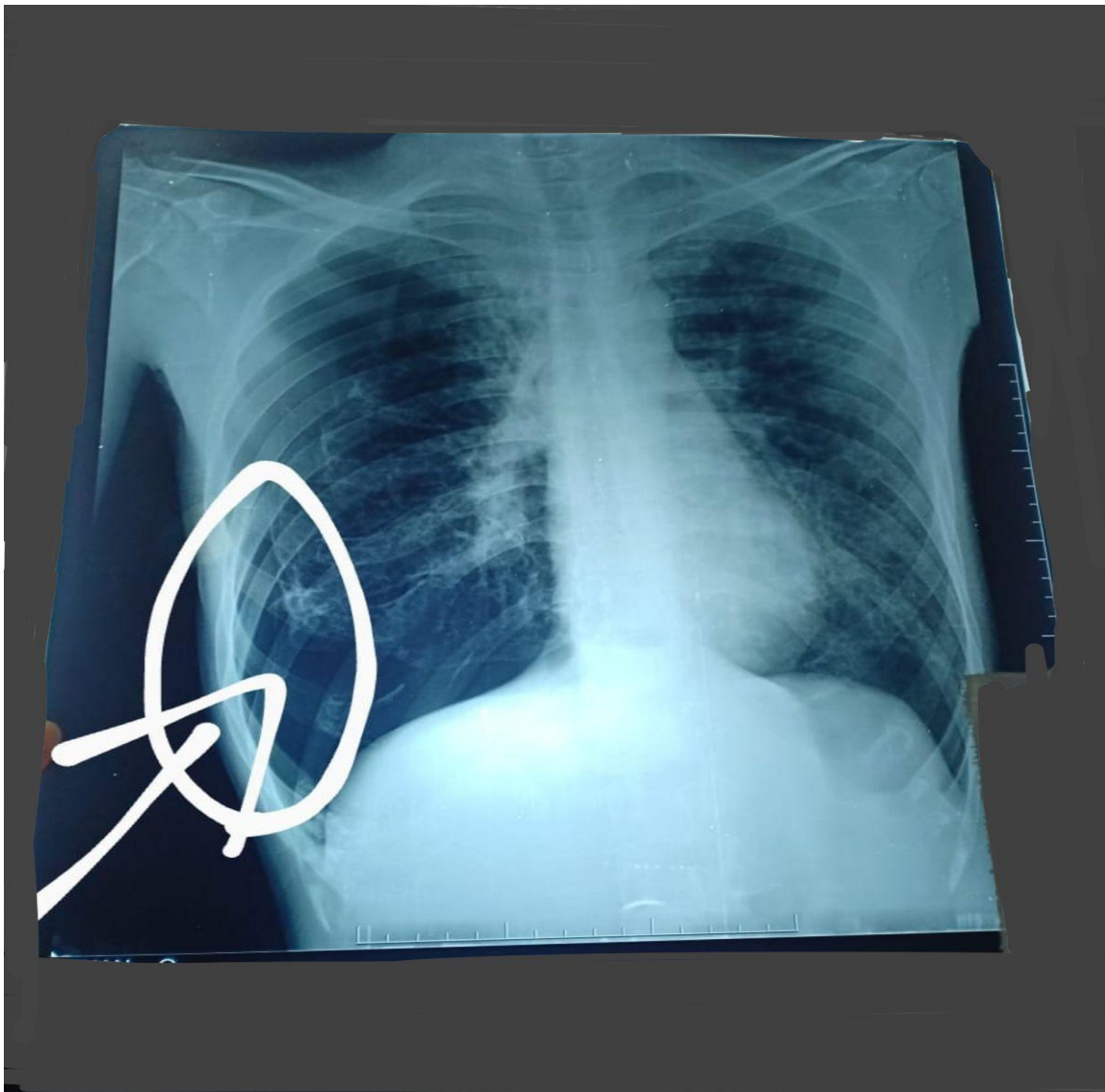


Fig. 1. CXR showing right-sided pneumothorax at the base of the lung

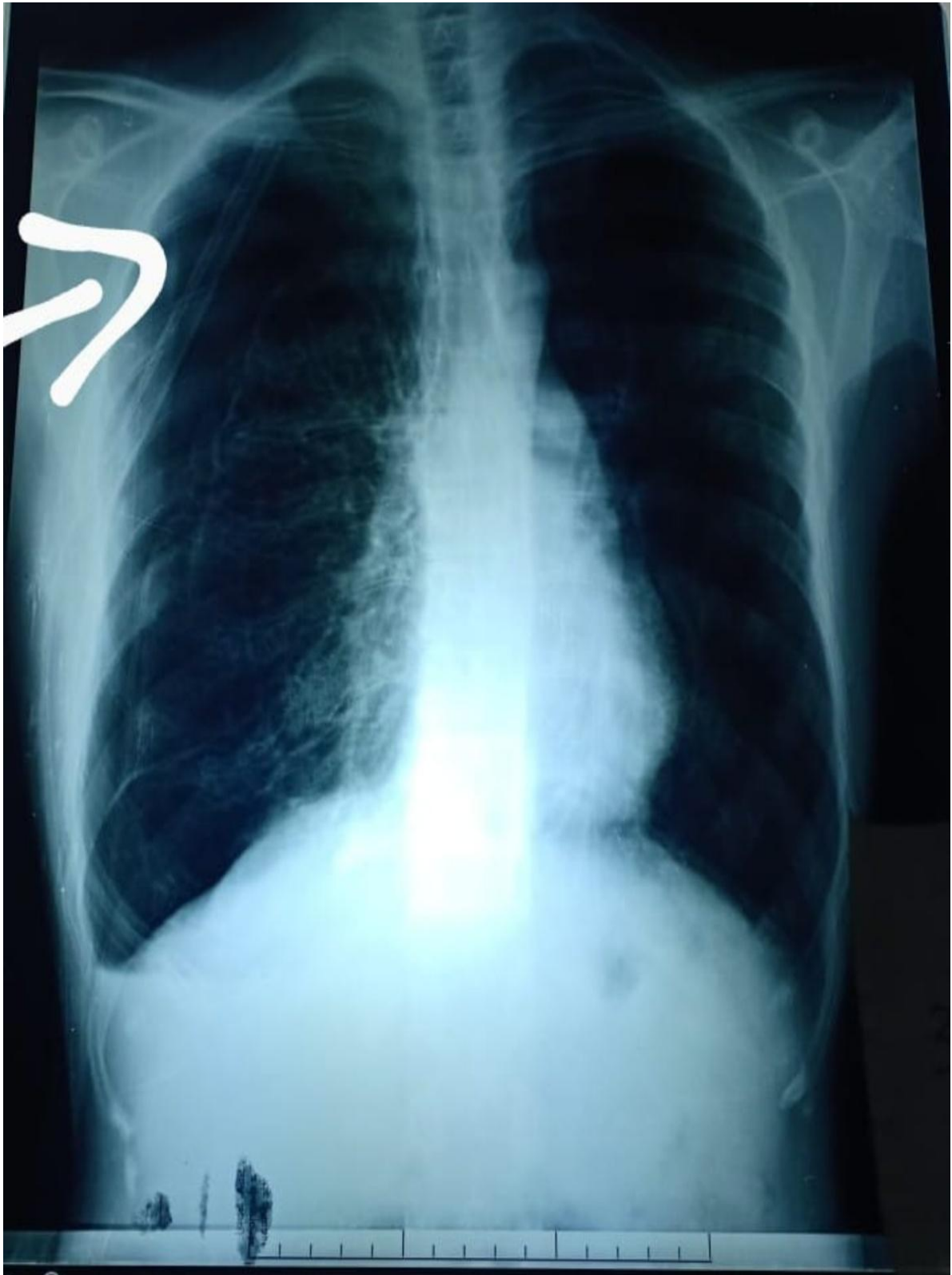


Fig. 2. White arrow on the CXR showing right upper chest tube insertion & pleurodesis

In our case, we diagnosed a rare disease like otherwise go undiagnosed and therefore not PLCH following this algorithm which may treated appropriately. However, in case of

uncertainty, >5% cells with CD1a immunostaining on BAL may confirm the diagnosis [1].

A case presented in Texas showed that patient had tension pneumothorax who had emergency thoracostomy done whose subsequent visit revealed Langerhans cell with pulmonary and jaw involvement [9].

A survey done in Cincinnati USA showed that air travel can be a risk in spontaneous pneumothorax patients having pulmonary Langerhans which can be 2-3% [10]. Where as another study done in Cincinnati, Ohio shows

that Spontaneous pneumothorax can be involved in patients with BHD, and to reduce the recurrence pleurodesis should be considered [11].

A study done in France reveals that recurrent pneumothorax even after conservative and thoracic surgery were same [12]. A case series done in Shanghai shows that langerhans disease might be smoking related [13].

PLCH being a rare disease, does not have a standard treatment so far but smoking cessation has been reported to play a key role in its regression [1-5].

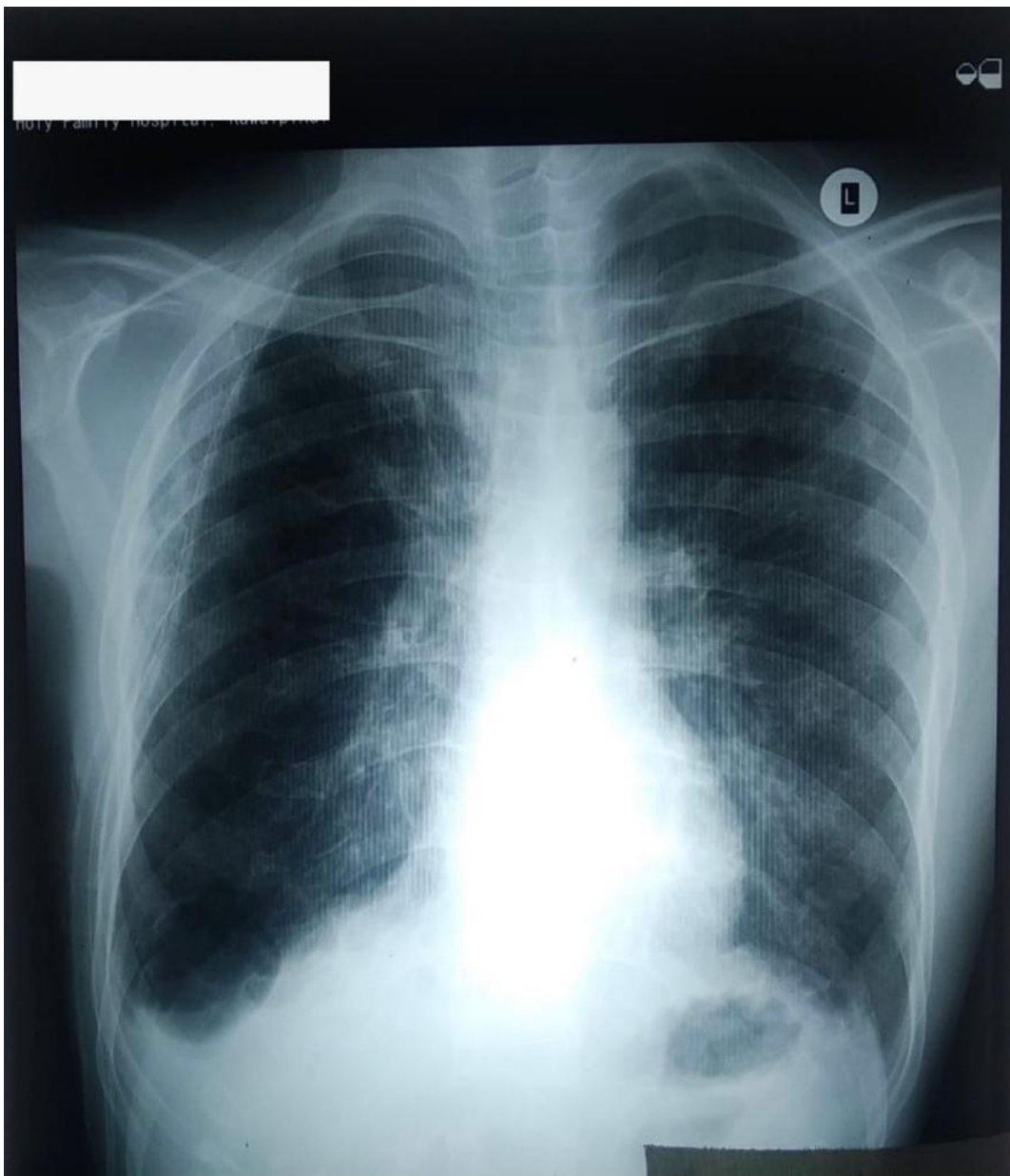


Fig. 3. CXR showing total lung expansion after chest tube insertion & Pleurodesis

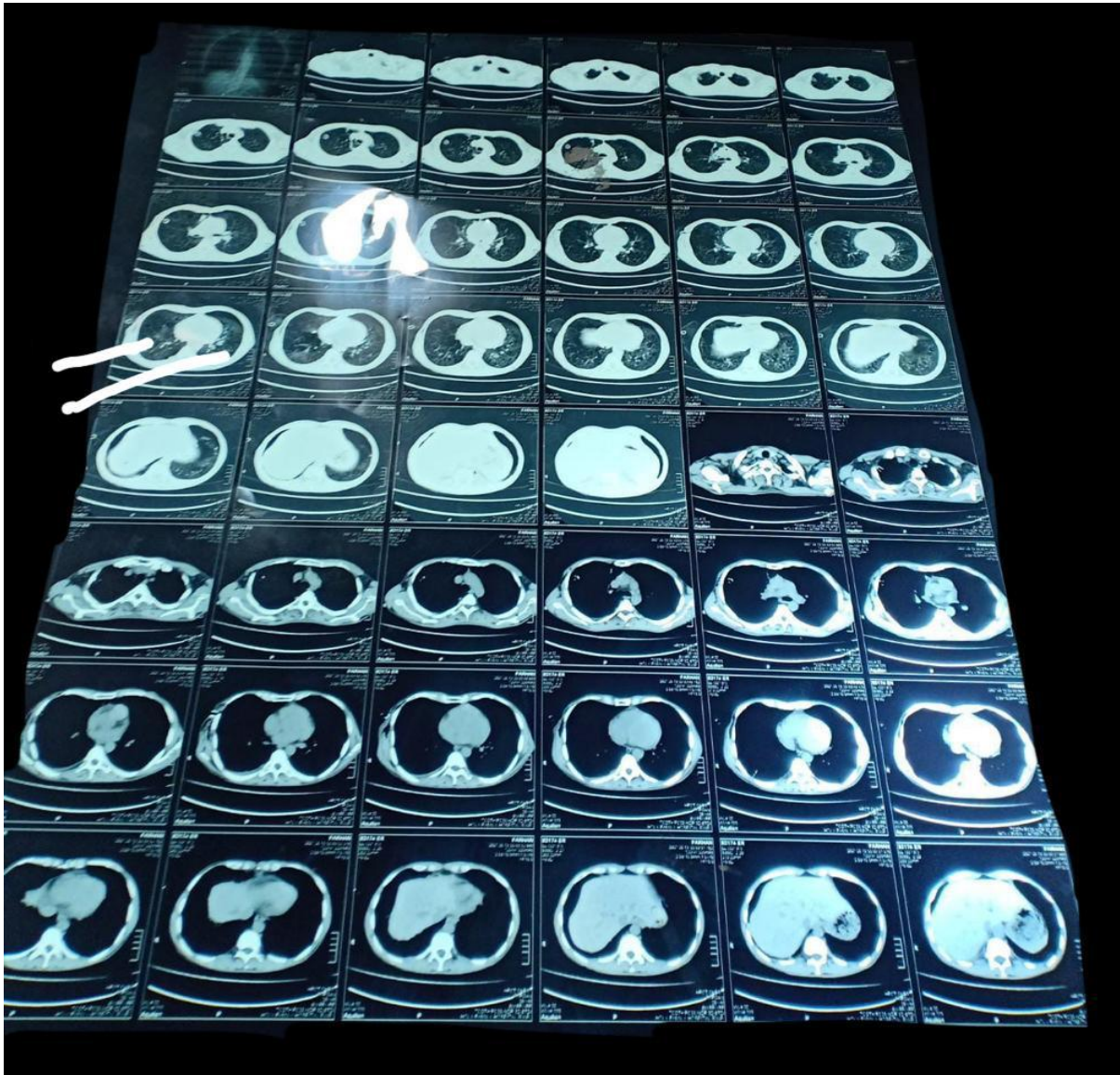


Fig. 4. White arrows in this HRCT showing well defined cystic lesions in bilateral lung fields

Table 1. Blood tests

Hemoglobin	13.6
WBC	6.8
RBC	4.52
Lymphocytes	29.6
Mid	9.6
Gran	60.8
Platelet	280
Sodium (Na)	137
Potassium (k+)	4.62
Cl(Cl-)	139.8
PT	13
APTT	36
Bilirubin	0.57
Serum Urea	29
Serum Creatinine	0.91

4. CONCLUSIONS

PLCH is a disease of young smokers and is one of the differential diagnoses of cystic lung disease. It can commonly present as spontaneous pneumothorax. HRCT plays a primary role as a diagnostic tool and a correct approach with an improved understanding can make the diagnosis a lot easier.

DISCLAIMER

The products used for this research are commonly and predominantly use products in our area of research and country. There is no conflict of interest between the authors and producers of the products because we do not intend to use these products as an avenue for any litigation but the advancement of knowledge. Also, the research was not funded by the producing company rather it was funded by the personal efforts of the authors.

CONSENT

As per international standard or university standard, patients' written consent has been collected and preserved by the authors.

ETHICAL APPROVAL

As per international standard or university standard written ethical approval has been collected and preserved by the authors.

REFERENCES

1. Park S, Lee EJ. Diagnosis and treatment of cystic lung disease. *Korean J Intern Med.* 2017; 32:229-238. DOI: 10.3904/kjim.2016.242
2. Marchiori E, Hochegger B, Zanetti G: Cystic lung disease with sparing of lung bases. *J Bras Pneumol.* 2021;47:1806-3756. DOI: 10.36416/1806-3756/e20210117
3. Lee K, Kang E, Yong H S, Kim C, Lee K Y, Hwang S H, Oh Y. A stepwise diagnostic approach to cystic lung diseases for radiologists. *Korean J Radiol.* 2019;20:1368-1380. DOI: 10.3348/kjr.2019.0057
4. Radzikowska E: Pulmonary Langerhans' cell histiocytosis in adults. *Adv Respir Med.* 2017; 85:277-289. DOI: 10.5603/ARM.a2017.0046
5. Shaw B, Borchers M, Zander D, Gupta N: Pulmonary Langerhans cell Histiocytosis. *Semin Respir Crit Care Med.* 2020;41:269-279. DOI: 10.1055/s-0039-1700996
6. Ferreira Francisco FA, Soares Souza A Jr, Zanetti G, Marchiori E: Multiple cystic lung diseases. *Eur Respir Rev.* 2015;24:552-64. DOI: 10.1183/16000617.0046-2015
7. Available: https://www.uptodate.com/contents/image?imageKey=PULM%2F113238&to picKey=PULM%2F112259&source=see_li nk
8. Torre O, Elia D, Caminati A, Harari S: New insights in lymphangiomyomatosis and pulmonary Langerhans cell Histiocytosis. *Eur Respir Rev.* 2017;26:170042. DOI: 10.1183/16000617.0042-2017
9. Juergens AL 2nd, Reddy AK, Fannell MW, Grayson GH. Pediatric spontaneous tension pneumothorax in Langerhans cell histiocytosis. *Proc (Bayl Univ Med Cent).* 2020 Oct 23;34(1):126-127. DOI: 10.1080/08998280.2020.1826215. PMID: 33456172; PMCID: PMC7787669
10. Singla A, Koprass EJ, Gupta N. Spontaneous pneumothorax and air travel in Pulmonary Langerhans cell histiocytosis: A patient survey. *Respir Investig.* 2019;57(6):582-589. DOI: 10.1016/j.resinv.2019.07.004. Epub 2019 Sep 26. PMID: 31563637; PMCID: PMC6832853.
11. Gupta N, Koprass EJ, Henske EP, James LE, El-Chemaly S, Veeraraghavan S, Drake MG, Mc Cormack FX. Spontaneous Pneumothoraces in Patients with Birt-Hogg-Dubé Syndrome. *Ann Am Thorac Soc.* 2017;14(5):706-713. DOI: 10.1513/AnnalsATS.201611-886OC. PMID: 28248571; PMCID: PMC5427741.
12. Le Guen P, Chevret S, Bugnet E, de Margerie-Mellon C, Lorillon G, Seguin-Givelet A, Jouenne F, Gossot D, Vassallo R, Tazi A. Management and outcomes of pneumothorax in adult patients with Langerhans cell Histiocytosis. *Orphanet J Rare Dis.* 2019;14(1):229. DOI: 10.1186/s13023-019-1203-5. PMID: 31639032; PMCID: PMC6805357.
13. Wei P, Lu HW, Jiang S, Fan LC, Li HP, Xu JF. Pulmonary langerhans cell histiocytosis: case series and literature

review. Medicine (Baltimore). 2014;93(23):
e141.

DOI: 10.1097/MD.000000000000141.
PMID: 25415669; PMCID: PMC4616338.

© 2021 Khurram et al.; This is an Open Access article distributed under the terms of the Creative Commons Attribution License (<http://creativecommons.org/licenses/by/4.0>), which permits unrestricted use, distribution, and reproduction in any medium, provided the original work is properly cited.

Peer-review history:
The peer review history for this paper can be accessed here:
<https://www.sdiarticle4.com/review-history/73587>