



Idiopathic Post-gastropexy Ileo-Ileal Intussusception: A Case Report and Review of Literature

Ahmed Nosseir ^a, Mohammad Daboos ^{a*}, Samir Gouda ^a,
Refaat Ibrahim ^a, Ahmed Salama ^a and Islam Makhoulf ^a

^a *Pediatric Surgery Department, Faculty of Medicine, Al-Azhar University Hospitals, Cairo, Egypt.*

Authors' contributions

This work was carried out in collaboration among all authors. All authors read and approved the final manuscript.

Article Information

Open Peer Review History:

This journal follows the Advanced Open Peer Review policy. Identity of the Reviewers, Editor(s) and additional Reviewers, peer review comments, different versions of the manuscript, comments of the editors, etc are available here: <https://www.sdiarticle5.com/review-history/94790>

Case Study

Received: 09/10/2022

Accepted: 18/12/2022

Published: 20/12/2022

ABSTRACT

Background: Postoperative intestinal intussusception (POI) is a rare cause of intestinal obstruction. It is reported to be occurred after many abdominal and non-abdominal operations. However, delayed diagnosis leads to ischemia and intestinal necrosis. Also increases post-operative morbidity and mortality, so it is needed an early diagnosis and timely intervention.

Methods: We have reported our experience with one of rare condition that post-operative intussusception seldom to be discovered after gastropexy, in addition to the previous experience of similar condition have also reported through collection of online databases of google scholars, included the children and infants with POI since 2017 in English-language using the key word "postoperative intussusception in children".

Results: We presented one case of ileoileal POI. Detected in the 7th post-operative day. Managed successfully with operative manual reduction with no postoperative complications in comparable with others in one diagram, as 18 cases with post-operative intussusception have been reported.

*Corresponding author: E-mail: daboosmohammad@gmail.com;

Conclusion: Frequently, post-operative intussusception is misdiagnosed as postoperative adhesive obstruction or adynamic ileus. Due to its rarity and unusual presentation, diagnosis is difficult and requires a very high index of suspicion.

Keywords: Postoperative intussusception; intestinal obstruction; gastropexy; adynamic ileus.

1. INTRODUCTION

An acute intussusception that appears within 30 days of an index operation is known as post-operative intussusception (POI) [1]. There are numerous suggestions to explain this uncommon condition, including prolonged postoperative ileus, extensive non-gentle treatment of the gut, however the etiopathogenesis of POI is not fully known [1,2].

POI with reported incidence after laparotomies of 0.01 to 0.25%, and accounts for 5-10% of all early postoperative intestinal obstructions [3]. Early POI detection is challenging. Because of the early symptoms of intestinal obstruction after the first procedure are frequently mistaken for a dynamic ileus [4].

This usually presents within one week with picture of intestinal obstruction without a palpable abdominal mass, and absence of bloody stool [5]. So, in a retrospective review by Van Houwelingen LT, et al. believed that ultrasonography for diagnosis of POI had a sensitivity of 89% and specificity of 100% [6].

Because of POI could be misdiagnosed, as it is unusual cause of postoperative obstruction. Herein, we present our experience for post-operative ileo-ileal intussusception after management of gastric volvulus, to increase the awareness of this rare entity.

2. CASE PRESENTATION

A male child one-year-old, presented with repeated attacks of non-bilious vomiting and chest infection, since few months, with failed conservative treatment, investigated by contrast study that showed picture of Transverse lie of the stomach with upward position of greater curvature and spherical bubble at gastric fundus denoting organo-axial gastric volvulus as (Fig.1), patient submitted for surgical correction and fixation of the stomach at 27th September 2022, also abdominal exploration was done for exclusion of gastric outlet obstruction or other abdominal anomalies.

Post-operative first day passes smoothly, but on the 2nd day post-operatively the patient has low grade fever with mild abdominal distention, NGT residual was about 100 cc of bilious secretion, the abdominal girth increased, by the third day and also NGT residual was high. (Hb) was 10.8, and potassium level was low (K 3.7), abdominal X-Ray (AXR) showed multiple air fluid levels (Fig. 2).

At the 4th post-operative days, the patient has same clinical picture, with observed low potassium level (K 3.2), and also abdominal X ray revealed picture of intestinal obstruction (Fig. 3), however abdominal ultrasonography was free. The condition considered to be post-operative paralytic ileus and conservative management was recommended, at 5th day pt. the condition slightly improved as K level was corrected and abdominal distention decreased.

But at the 7th post-operative day, NGT bilious residual and abdominal distension increased, also abdominal US showed target sign of ileo-ileal intussusception. So, exploratory laparotomy has done, revealed that a part of bowel dilated and other collapsed, ileo-ileal intussusception detected (Fig. 4a), and simple reduction done smoothly (Fig.4b), no adhesions, no leading point to be found. The bowel loops at the intussusception were noted to be pink viable. Postoperative course and follow up period were uneventful.

3. DISCUSSION

Postoperative intestinal obstruction is a common problem occurred in children and is mostly due to intestinal adhesions and adynamic ileus. One forgotten cause of postoperative intestinal obstruction is postoperative intussusception [7,8].

The rarity and unusual presentation of this entity make early identification challenging. The exact cause is unknown. Alterations in peristalsis, early postoperative adhesions, excessive bowel movement, electrolyte problems during lengthy procedures, anesthetic medications, opioid analgesics, and neurogenic variables are some of the theories being used to try to explain how POI occurs [3].

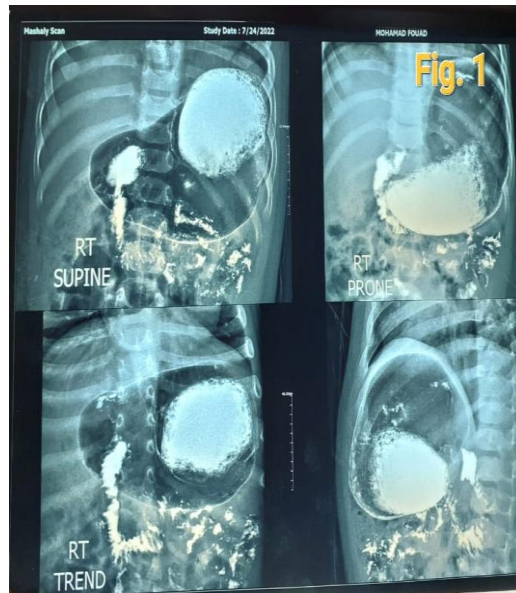


Fig. 1. Contrast study revealed transverse lie of the stomach with upward position of greater curvature and spherical bubble at gastric funds

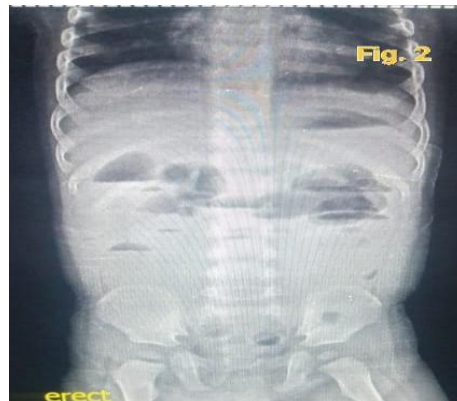

Fig. 2. AXR 2nd day post-operative showed multiple air fluid levels

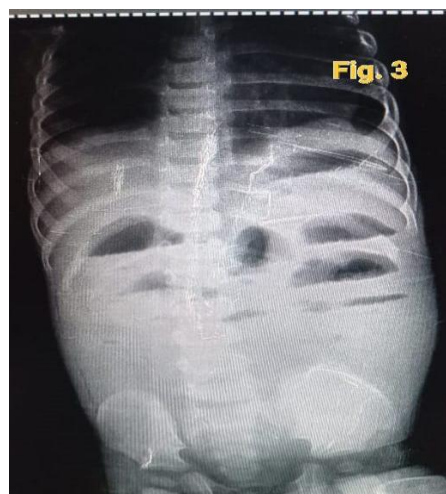


Fig. 3. AXR 4th day post-operative showed multiple air fluid levels

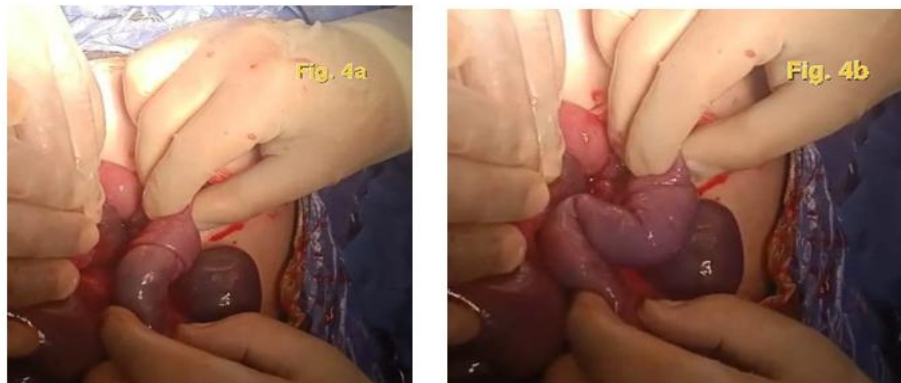

Fig. 4. A. Intraoperative ileoileal intussusceptions; B. Intraoperative successful manual reduction

Surgery for gastroesophageal reflux disease, neuroblastoma, and Hirschsprung's disease is linked to an increased risk of POI [9]. Additionally, appendectomy, Meckel's diverticulum, and retroperitoneal malignancies are common causes of intussusception. As previously documented by Sule Yalçin et al., POI seldom occurs following gastropexy [10], which is what happened in the current case.

POI occurs in 90% of all cases within less than 14 days, in 64% as early as the first 7 days after the primary operation [2,11], our case was picked up at the 7th post-operative day.

Clinically, POI frequently manifests with vague "prolonged paralytic ileus" [2]; moreover, POI is frequently misinterpreted as postoperative adhesive bowel obstruction [7], with bilious vomiting being the most frequently observed presentation of symptoms. Other frequent presentations include abdominal distension and increased bilious nasogastric tube output [3]. In the index case, an early ileus was present with bilious vomiting, abdominal distension, no stool passage, low potassium levels, and air fluid levels in the abdominal radiography [12,13]. The patient was closely monitored and the general condition was corrected.

Helpful diagnostic modalities may include abdominal X-ray, abdominal ultrasound, contrast study and computerized tomography (CT) scan [14], in our case AXR revealed obstruction as multiple fluid levels, diagnosis of POI by ultrasound had a sensitivity of 89% and specificity of 100% [5], In our case to complete our work up we did 2 repeated ultrasounds for

the patient, first one was negative (during the ileus period), the 2nd was positive for the target sign of intussusception.

The most common site of POI is the small intestine with ileo-ileal intussusception predominance [3], Other reported POI sites are jejunojejunal, jejunoileal, ileocolic and multiple intussusception [15]. Ileoileal POI is frequently reported with abdominal procedures while ileocolic POI being reported more commonly with non-abdominal procedures [14,16]. Our case as commonly reported was ileoileal type.

The common characteristics features with many of the others, which are comparable to our case, are the intussusception's prevalence in the ileoileal region, the lack of any lead points, the high rate of manual reduction success, and the uneventful course following the second operation [17,18]. Most authors in the last 5 years' review reported successful manual reduction as Ravibindu et al., Manel et al., Hannah et al. and others (Table 1) [19-23], also most authors do not advocate colonic enema for nonoperative reduction since it will not be beneficial for small bowel intussusception, the most frequent site of POI [10].

Post-operative intussusception can be associated with bowel ischemia and necrosis that need resection and anastomosis as reported in 5 cases in our review with Sadi et al., Lavanya et al. and Aditya et al. (Table 1) [15,24,25], which is not consistent with our case.

The use of a minimally invasive procedure, gentle handling, and avoiding desiccation of the colon are all recommended as POI prevention strategies [10,26,27].

Table 1. Characteristics of the previously reported POI in the last 5 years

	Gender	Age	First operation	Onset of symptoms	Day of reoperation	Second operation
Case 1 (13)	F	2 years	Laparotomy with end sigmoid colostomy	POD 10	POD 30	Manual reduction with resection and re-anastomosis
Case 2 (13)	F	5 mon	Ileo-colic intussusception reduction with Rt. Hemicolectomy	POD 5	POD 7	Manual reduction with primary repair of perforation
Case 3 (13)	M	6 mon	Laparotomy, creation of end colostomy	POD 3	POD 5	Manual reduction
Case 4 (16)	F	4 mon	Laparotomy with end colostomy	POD 3	Unknown	Manual reduction with resection and re-anastomosis
Case 5 (16)	F	2 mon	Laparotomy with end colostomy	POD 2	Unknown	Manual reduction with resection and re-anastomosis
Case 6 (17)	M	13 mon	Right hemi-colectomy with ileocolic anastomosis	POD 7	Unknown	Manual reduction
Case 7 (18)	M	2.5 years	Ladd's procedure	POD 6	Unknown	Manual reduction
Case 8 (19)	F	6 mon	Nissen fundoplication	POD 5	Unknown	Manual reduction
Case 9 (20)	F	8 mon	Manual reduction for intussusception	POD 1	POD 1	Manual reduction
Case 10 (21)	M	6 mon	Ladd's procedure	POD 8	POD 8	Manual reduction
Case 11 (22)	F	3 years	Pyloroplasty	POD 3	POD 5	Manual reduction
Case 12 (23)	M	1.5 years	Excision of pancreatic pseudocyst	POD 5	POD 7	Resection and re-anastomosis
Case 13 (24)	F	10 years	Open appendectomy	POD 1	Unknown	Manual reduction
Case 14 (25)	M	5 years	Nephrectomy	POD 3	POD 4	Manual reduction
Case 15 (25)	M	8 mon	Nephrectomy	POD 1	Unknown	Manual reduction
Case 16 (26)	F	15 mon	Resection anastomosis for patent vitello intestinal duct.	POD 4	POD 15	Manual reduction
Case 17 (27)	M	8 mon	Meckel's diverticulum excision	POD 7	POD 8	Manual reduction
Case 18 (Our case)	M	1 year	Gastropexy	POD 3	POD 7	Manual reduction

4. CONCLUSION

POI is a rare surgical complication. A strong index of suspicion should be kept in place in every patient who has postoperative intestinal obstruction, and meticulous clinical assessment should be done to pick up POI.

CONSENT

As per international standard or university standard, parental(s) written consent has been collected and preserved by the author(s).

ETHICAL APPROVAL

As per international standard or university standard written ethical approval has been collected and preserved by the author(s).

COMPETING INTERESTS

Authors have declared that no competing interests exist.

REFERENCES

1. Eke N, Adotey JM. Postoperative intussusception, causal or casual relationships? *Int Surg.* 2000;85(4):303-8.
2. Mollitt DL, Ballantine TVN, Grosfeld JL. Postoperative intussusception in infancy and childhood: Analysis of 119 cases. *Surgery.* 1979;86(3):402-8.
3. Yang G, Wang X, Jiang W, Ma J, Zhao J, Liu W. Postoperative intussusceptions in children and infants: A systematic review. *Pediatr Surg Int.* 2013;29(12):1273-9.
4. Linke F, Eble F, Berger S. Postoperative intussusception in childhood. *Pediatr Surg Int.* 1998;14(3):175-7.
5. VanHouwelingen LT, Seims AD, Ortega-Laureano L, Coleman JL, McCarville MB, Davidoff AM, et al. Use of ultrasound in diagnosing postoperative small-bowel intussusception in pediatric surgical oncology patients: A single-center retrospective review. *Pediatr Radiol.* 2018; 48(2):204-9.
6. Bai YZ, Chen H, Wang WL. A special type of postoperative intussusception: Ileoileal intussusception after surgical reduction of ileocolic intussusception in infants and children. *J Pediatr Surg.* 2009;44(4):755-8.
7. Weiwei Jiang, et al. Postoperative intussusception in infants and children: A report of seven cases. *J. Biomed. Res.* (2012) 66:26 (1).
8. Linke F, Eble F, Berger S. Postoperative intussusception in childhood, *Pediatr. Surg. Int.* 1998;14(3):175-177.
9. Rosenkrantz JG, Cox JA, Silverman FN, Martin LW. Intussusception in the 1970s: Indications for operation. *J Pediatr Surg.* 1977;12(3):367-73.
10. Sule Yalçın, et al. Postoperative intussusception in children: A keen diagnosis in postoperative ileus. *Turk J Pediatr.* 2012;54(4):403-8.
11. Janik JS, Ein SH, Filler RM, Shandling B, Simpson JS, Stephens CA. An assessment of the surgical treatment of adhesive small bowel obstruction in infants and children. *J Ped Surg.* 1981;16(3):225-9.
12. Naa, et al. Post-operative ileo-ileal intussusception one week after hemicolecotomy for ileo-colic intussusceptions. *Journal of Pediatric Surgery Case Reports.* 2023;88:102506.
13. Zaheer, et al. Post-operative intussusception following ladd's procedure. *Indian Journal of Surgery.* 2021;83(4): 1030-1031.
14. Justin D. Klein, et al. Pediatric postoperative intussusception in the minimally invasive surgery era: A 13-year, single center experience. *J. Am. Coll. Surg.* 2013;216(6):1089-1093.
15. Sadi A, Abukhalaf, et al. Postoperative intestinal intussusception in children, an easily missed culprit of postoperative intestinal obstruction: Case series and literature review. *International Journal of Surgery Case Reports.* 2019;60:336-339.
16. David, et al. Jodhpur disease complicated by postoperative intussusception in St. Mary's Hospital Lacor. *Journal of Pediatric Surgery Case Reports.* 2020;63:101642.
17. Ein SH, Ferguson JM. Intussusception - the forgotten postoperative obstruction. *Arch Dis Child.* 1982;57:788-790.
18. Vries S, Sleebom C, Aronson DC. Postoperative intussusception in children. *Br J Surg.* 1999;86:81-83.
19. Ravibindu, et al. Post-operative intussusception: A rare phenomenon. *Sri Lanka Journal of Child Health.* 2017;46(4):389-390
20. Manel, et al. Postoperative intussusception in children after nissen fundoplication: A case Report. *Int. J Pediatr.* 2018;6(49).

21. Hannah, et al. Double ileoileal intussusception following surgical reduction of ileocolic intussusception in an 8-Month-Old Female. J Pediatr. 2017; 186:208.
22. Omer, et al. Post-operative intussusceptions, a rare case in pediatric, National Center for Pediatric Surgery, Gezira State, Sudan; 2021. World Journal of Biology Pharmacy and Health Sciences. 2021;08(03):001-004.
23. Van Peer, et al. The unique characteristics of intussusception after renal tumor surgery in Children. Journal of Pediatric Surgery Case Reports. 2018;30:68-73.
24. Lavanya, et al. Unusual presentation of postoperative intussusception in two infants. Journal of Indian Association of Pediatric Surgeons. 2022;27(4):503-504.
25. Aditya, et al. Post-operative intussusception in a child after pseudo cyst of pancreas excision. National Journal of Health Sciences. 2018;3:61-62.
26. Sundar, et al. Pediatric postoperative intussusceptions. J Nepal Health Res Council. 2019;17(43):258-60.
27. Reza, et al. Retrograde intestinal intussusception due to a recent suture line as the lead point. Journal of Pediatric Surgery Case Reports. 2019;43;26-2.

© 2022 Nosseir et al.; This is an Open Access article distributed under the terms of the Creative Commons Attribution License (<http://creativecommons.org/licenses/by/4.0>), which permits unrestricted use, distribution, and reproduction in any medium, provided the original work is properly cited.

Peer-review history:
The peer review history for this paper can be accessed here:
<https://www.sdiarticle5.com/review-history/94790>